

Implantation of phakic intraocular lens in 3 patients with oculocutaneous albinism

Gwyneth A. van Rijn, MD, Colette Snoek, MD, Maurits Joosse, MD, PhD,
Ruchi Saxena, MD, PhD, Gregorius P.M. Luyten, MD, PhD

We present 3 cases with oculocutaneous albinism in which a high refractive error was optically corrected by implantation of an Artisan iris-fixated phakic intraocular lens, with a follow-up of 8 to 14 years.

Financial Disclosure: No author has a financial or proprietary interest in any material or method mentioned.

J Cataract Refract Surg 2013; 39:1604–1608 © 2013 ASCRS and ESCRS

Albinism refers to a group of autosomal recessive melanin disorders in which pigmentation is reduced compared with pigmentation in others of the same ethnic and racial backgrounds.¹ Melanin is a chromophore with various biological functions including photoprotection, antioxidant defense, camouflage, drug-binding metal-ion chelation, and thermoregulation.² In the eye, it is found in the uveal melanocytes derived from the neural crest and in the retinal pigmented epithelium derived from the neuroectoderm. Melanin is also present in the posterior iris-pigmented epithelium and in the phagocytic clump cells within the iris stroma.

Ocular involvement is characteristic in albinism. Sole eye involvement is referred to as ocular albinism; in oculocutaneous albinism, the eyes in combination with the skin and hair may be simultaneously affected. Common ocular findings include refractive errors (primarily astigmatism and hyperopia,³ iris transillumination due to reduced pigmentation, nystagmus,

absence of stereopsis, foveal hypoplasia, fundus hypopigmentation, and misrouting of optic nerve fibers at the chiasm; all leading to reduced visual acuity).^{1,4} Oculocutaneous albinism type 1A, the most severe form of oculocutaneous albinism, is associated with the highest rate of hyperopia and the poorest visual acuity compared with the other subtypes.³

Studies of iris-fixated phakic intraocular lenses (pIOLs) for the correction of high refractive errors in healthy eyes have shown good levels of safety and efficacy.^{5–8} This has raised the possibility that an iris-fixated pIOL might be a good option for the treatment of high refractive errors commonly found in albinism. However, the presumed fragility of the iris and supposedly high risk for decentration or dislocation of the pIOL may deter surgeons from implanting an iris-fixated pIOL. We describe 3 patients with oculocutaneous albinism type 1A who had successful iris-fixated pIOL implantation in both eyes with an 8- to 14-year follow-up.

CASE REPORTS

An overview of the clinical data of the 3 cases is shown in Table 1.

Case 1

A 41-year-old male schoolteacher with clinical phenotype oculocutaneous albinism 1A presented to us in February 1998 due to increasing visual disturbances caused by unstable positioning of rigid contact lenses from a pendular nystagmus. The corrected distance visual acuity (CDVA) was 20/400 with $-11.25 -5.00 \times 17$ in the right eye and 20/1200 with $-9.75 -4.00 \times 160$ in the left eye. Slitlamp examination revealed a total diaphanous iris with no sign of iridodonesis, and fundoscopic eye examination showed retinal hypopigmentation. The anterior chamber depth (ACD) from the corneal epithelium was 3.5 mm in the right

Submitted: February 6, 2013.

Final revision submitted: April 15, 2013.

Accepted: April 18, 2013.

From the Department of Ophthalmology (van Rijn, Snoek, Saxena, Luyten), Leiden University Medical Center, Leiden, and the Department of Ophthalmology (Joosse), Haaglanden Medical Center, Den Haag, The Netherlands.

Gwyneth A. van Rijn, MD, and Colette Snoek, MD, contributed equally to this work.

Corresponding author: Gwyneth A. van Rijn, MD, Department of Ophthalmology, Leiden University Medical Center, Room J3-93, Albinusdreef 2, 2300 RC Leiden, The Netherlands. E-mail: g.a.van_rijn@lumc.nl.

Table 1. Clinical data of the 3 cases.

Exam Period	Right Eye						Left Eye					
	UDVA	Sphere	Cylinder	CDVA	IOP	ECD	UDVA	Sphere	Cylinder	CDVA	IOP	ECD
Case 1												
Preop	—	-11.25	-5.0	0.05	14	*	—	-9.75	-4.0	0.02	14	*
Postop (y)												
0.5	0.1	1.5	-2.25	0.1	12	*	0.1	1	-1.75	0.1	12	*
5	0.1	1.25	-2.75	0.1	18	3170	0.1	2.5	-2.75	0.1	16	3165
10	0.1	2	-2.5	0.1	13	3247	0.1	2.75	-3.25	0.1	13	3106
14	0.05	2	-1.75	0.05	14	3075	0.1	4	-2.75	0.1	14	2842
Case 2												
Preop	—	-3.5	-3.75	0.1	16	*	—	-3	-3	0.1	14	*
Postop (y)												
1	0.1	-0.25	-1.5	0.1	9	3312	0.1	-0.75	-0.5	0.16	9	3063
5	0.1	-0.75	-2.25	0.1	14	*	0.16	-1	-1.75	0.16	14	*
10	0.1	0.25	-2.25	0.1	14	2790	0.1	-0.25	-1.75	0.1	14	2755
Case 3												
Preop	—	-10.5	-2	0.08	16	*	—	-9.5	-1.25	0.1	16	*
Postop (y)												
1	0.1	-0.25	-1.5	0.2	15	2967	0.1	0.5	-1.75	0.2	14	2347
8	0.16	0.75	-0.75	0.16	13	2825	0.16	1	-1.25	0.16	13	2086

CDVA = corrected distance visual acuity; ECD = endothelial cell density (cells/mm²); IOP = intraocular pressure (mm Hg); UDVA = uncorrected distance visual acuity

*Missing data; failed ECD because of presence of nystagmus or because it was impossible to recount due to poor quality of endothelial cell photographs

eye and 3.7 mm in the left eye. Because of the nystagmus, no reliable endothelial cell density (ECD) measurement could be performed.

Later in 1998, a -14.5 diopter (D) Artisan pIOL (Ophtec) was implanted according to protocol (Appendix 1) in each eye under general anesthesia in 2 consecutive sessions. (Toric IOLs were not used as they were not available until April 2001.)

Six months after implantation, the CDVA had improved to 20/200 in both eyes. The pIOLs were well centered with good enclavation bites, and the intraocular pressure (IOP) was within normal limits. At 5 and 10 years, the CDVA remained stable at 20/200 in both eyes. The ECD was successfully measured at the 5-year follow-up and remained stable up to 10 years. At the last examination, 14 years after implantation, the ECD was 3075 cells/mm² in the right eye and 2842 cells/mm² in the left eye, indicating a mean yearly decline of 0.33% and 1.13%, respectively, over 9 years. The CDVA was 20/400 in the right eye and 20/200 in the left eye. A clear crystalline lens was observed, and the pIOLs were stable and well centered with no signs of atrophy at the enclavation sites (Figure 1, A). During the past 4 years, recurrent corneal erosions due to epitheliopathy have caused discomfort, problems with reading, and a slight decrease in the CDVA in the right eye. Regular follow-up visits at our clinic are scheduled. Although some residual astigmatism and slightly increasing hyperopia remain, the patient is satisfied with the result of the implantation and continues to work as a schoolteacher.

Case 2

A 45-year-old woman with clinical phenotype oculocutaneous albinism 1A, who was a first-degree relative of the

Case 1 patient, visited our clinic in 2002 because she was dissatisfied with her visual acuity with spectacles and suffered from contact lens intolerance. The CDVA was 20/200 with -3.50 -3.75 × 6 and -3.00 -3.00 × 13 in the right eye and left eye, respectively, with a pendular nystagmus. Biomicroscopy of the anterior segment revealed a total diaphanous iris without iridodonesis. Fundoscopic eye examination showed hypopigmentation of the fundus (Figure 2). The ACD was 3.4 mm in the right eye and 3.26 mm in the left eye.

In 2002, an Artisan toric pIOL of -5.00 -3.50 × 8 was implanted in the right eye according to protocol. Three weeks later, a toric pIOL of -3.50 -3.00 × 13 was implanted in the left eye. Both procedures were performed under general anesthesia. Throughout the 10-year follow-up, the CDVA remained stable around 20/200 in both eyes and the IOPs remained within normal limits. The endothelium in both eyes showed a mean yearly decline of 1.75% in the right eye and 1.12% in the left eye throughout the follow-up. The pIOLs remained in central and stable positions with no sign of iris atrophy or inflammation in the anterior chamber (Figure 1, B). The patient remains pleased with the outcome.

Case 3

A 40-year-old man with clinical phenotype oculocutaneous albinism 1A presented in 2003 because of progressive contact lens intolerance. The CDVA was 20/250 with -10.50 -2.00 × 34 in the right eye and 20/200 with -9.50 -1.25 × 133 in the left eye. On examination, a pendular nystagmus, a complete diaphanous iris without signs of iridodonesis, and an absence of the macular reflex were noted. A convergent strabismus of the right eye was

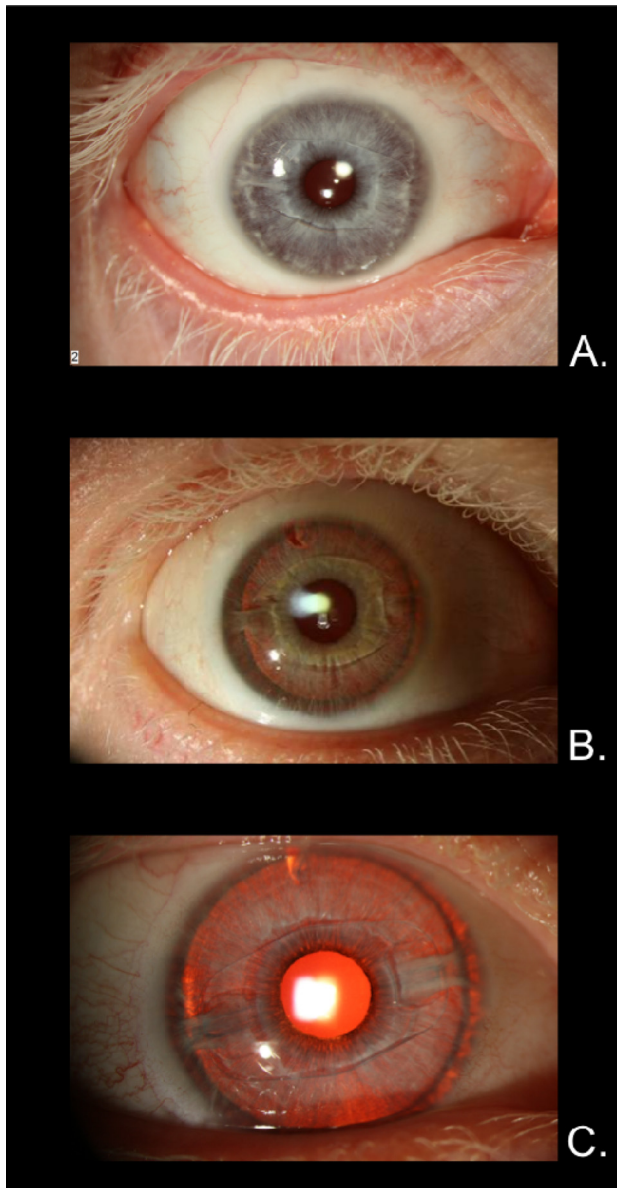


Figure 1. Right eye in Case 1 (A), Case 2 (B), and Case 3 (C) 14, 10, and 8 years, respectively, after implantation of the iris-fixated pIOL. Note the translucent iris tissue, the intact enclavation bites, and the central positioning of the pIOLs.

observed. An initial ECD could not be performed because of the nystagmus. The ACD was 3.4 mm in the right eye and 3.45 mm in the left eye.

In 2004, a -12.5 D Artisan iris-fixated pIOL was implanted in each eye under local anesthesia. At the 1-year follow-up, the CDVA had improved to 20/100 in both eyes and successful endothelial cell counts of 2967 cells/mm² in the right eye and 2347 cells/mm² in the left eye were obtained. At the last follow-up in 2012, the CDVA was 20/125 in both eyes. Throughout the 8-year follow-up, the pIOLs were well centered and remained in stable positions with no signs of iris atrophy around the enclavation sites (Figure 1, C). The IOP remained within normal limits. At the last follow-up, the ECD was 2825 cells/mm² in the right eye

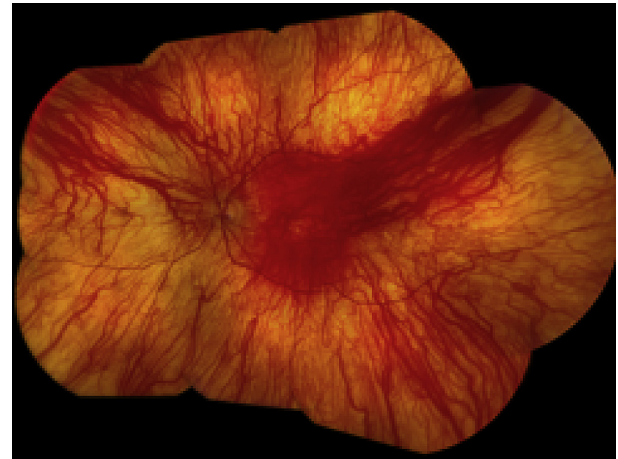


Figure 2. Fundus showing hypopigmentation and an absence of the macular reflex in oculocutaneous albinism type 1A.

and 2086 cells/mm² in left eye, indicating a mean yearly endothelial cell loss of 0.68% and 1.59%, respectively. The patient is very satisfied with the result and will continue regular follow-ups at our clinic.

DISCUSSION

High refractive errors are a common finding in patients with albinism. Often, the visual correction with spectacles is inadequate. Correction with contact lenses can be disappointing due to intolerance or lens instability caused by nystagmus. For these patients, refractive surgical correction, such as the iris-fixated pIOL, may be a good option to maximize visual acuity, although determining an accurate refraction may not be easy in patients with oculocutaneous albinism because of low visual acuity in combination with high astigmatism and nystagmus. Subjective improvement with less disturbing vision was reported in our 3 cases, and postoperative visual acuity increased. In Case 1, a spherical equivalent of around zero was achieved initially but slightly increasing hyperopia was seen in the long-term follow-up. In the other cases, mainly astigmatism remains. The patients are satisfied with the refractive results even though some rest-refractive error remains. To our knowledge, no literature currently describes the stability of refractive errors over time in patients with oculocutaneous albinism, but we do not have any reason to doubt that the stability might be different from that in normal eyes.

Strict preoperative criteria have to be met before iris-fixated pIOLs can be implanted to minimize the risk for endothelial cell loss and other complications in healthy eyes. Reliable endothelial cell analysis is known to be difficult to perform. Besides the measurement device, the skills of the technician, and the location on the cornea, the quality of the endothelial

image accounts for a great deal in performing reliable endothelial cell analysis. In our cases, all endothelial cell photographs were acquired from the central region of the cornea with 2 noncontact specular microscopes. To correct for the use of 2 specular microscopes, although manufactured by the same company, the endothelial cell images were imported and manually recounted in external software, as described in [Appendix 2](#). In our 3 cases, the acquired endothelial cell images were of fair to poor quality due to the presence of nystagmus. Preoperative endothelial cell photographs were acquired but were impossible to analyze because of the extremely poor image quality. As noted by McCarey et al.,⁹ the number of visible and countable endothelial cells is greatly affected by the image quality. Endothelial cell density estimation will become more accurate with larger image samples and more cells counted per image. Physiological central corneal endothelial cell loss is reported to be approximately 0.6% per year.¹⁰ In our cases, endothelial cell loss varied from 0.33% to 1.75% per year. The rate of endothelial cell loss does not seem to differ from the rate reported in normal eyes implanted with an iris-fixated pIOL.^{5,8} However, reliability of the reported ECDs is limited because of the low quality of the analyzed images. We believe that the difference in ECD between the 2 eyes in Case 3 may have been preexistent as it was visible at the first reliable ECD measurement at the 1-year follow-up and both surgeries and direct postoperative history were unremarkable.

In patients with albinism, the iris might not be suitable for iris-fixated pIOLs. A thin iris may be too fragile to allow satisfactory enclavation of the IOL. The normal iris is characterized by 5 layers of tissue: an anterior layer of chromatophores containing melanocytes with a genetically determined density of melanin pigment granules, a well-vascularized stroma containing a dense collection of fibroblasts and radially oriented collagen fibers and glycosaminoglycans, sphincter and dilator muscle fiber layers, and the iris-pigmented epithelium. Although a translucent iris, as may be observed in oculocutaneous albinism, appears fragile, absence or lack of pigmentation does not appear to decrease the mechanical strength of the iris and thus is not likely to increase the risk for dislocation of an iris-fixated IOL. We were unable to find any mechanical strength properties attributed to melanin in the literature. A plausible theory is that rather than pigment, other components of the iris are responsible for the mechanical strength of the tissue, such as the muscular structures or the heavily vascularized stroma.

Melanin is proposed to have proinflammatory properties.¹¹ This suggests that less inflammation is to be

expected after surgery in eyes that contain a small amount or no melanin than in eyes that contain melanin, ie, normal eyes. In our 3 cases with oculocutaneous albinism 1A, no extraordinary inflammatory response was observed after pIOL implantation.

The 3 cases demonstrate successful Artisan pIOL implantation in patients with oculocutaneous albinism 1A. No complications, particularly no dislocation or luxation, were observed. The obtained refractive results were satisfactory to the patients. The visual acuity improved in all 3 cases after implantation, and the endothelial cell counts remained acceptable throughout follow-up. Regular visits of the patients to continue ECD follow-ups at our clinic will be maintained.

Although studies with greater numbers of eyes must be performed, these 3 cases suggest that iris-fixated pIOLs can be considered a safe treatment option for patients with albinism and high refractive errors.

APPENDIX.

Appendix 1. Protocol for Iris-Fixated Phakic IOL Implantation: Before surgery, the desired axis location is marked on the cornea with a corneal marker if a toric IOL is to be placed. Miotic drops (pilocarpine 2%) are administered preoperatively to prepare the iris for IOL fixation. A limbal beveled incision of 5.5 mm is made at 12 o'clock, and 2 paracenteses are made at 10 o'clock and 2 o'clock. The anterior chamber is opened and sodium hyaluronate 1.0% (Healon) introduced to maintain depth and to protect the endothelium. After implantation and correct positioning at the desired axis, the IOL is fixated to the midperipheral iris stroma with an enclavation needle. At the end of the procedure, a slit iridotomy is performed at 12 o'clock to prevent angle-closure glaucoma and the sodium hyaluronate 1.0% is manually removed by irrigation. The incision is closed with a 10-0 nylon running suture.

Appendix 2. The noncontact specular microscope SP-2000P and SP-3000P (Topcon Corp.) was used to obtain multiple images of the endothelial cell layer of the central region of the cornea using automatic focusing and digital image capture. The raw endothelial cell images were imported into Konan KSS-300 software (Version 2.20) (Konan Medical) for recalibration and manual recount purposes. Prior to the procedure, the distance of the embedded tick marks on the image and the image magnification were checked. These were identical in both devices according to the manufacturer. The quality of the imported endothelial cell images was classified as good, fair, poor, or impossible. Two independent researchers manually counted all visible and countable endothelial cells in the image

using the center-to-center method; the mean endothelial cell density was reported.

REFERENCES

1. Levin AV, Stroh E. Albinism for the busy clinician. *J AAPOS* 2011; 15:59–66
2. Zonios G, Dimou A. Melanin optical properties provide evidence for chemical and structural disorder in vivo. *Opt Express* 2008; 16:8263–8268. Available at: http://www.opticsinfobase.org/view_article.cfm?gotourl=http%3A%2F%2Fwww%2Eopticsinfobase%2Eorg%2FDirectPDFAccess%2FC4D4E9D2%2D005F%2D7E15%2D5396F8892DD42BFA%5F160591%2Foe%2D16%2D11%2D8263%2Epdf%3Fda%3D1%26id%3D160591%26seq%3D0%26mobile%3Dno&org=. Accessed May 11, 2013
3. Yahalom C, Tzur V, Blumenfeld A, Greifner G, Eli D, Rosenmann A, Glanzer S, Anteby I. Refractive profile in oculocutaneous albinism and its correlation with final visual outcome. *Br J Ophthalmol* 2012; 96:537–539
4. Kirkwood BJ. Albinism and its implications with vision. *Insight* 2009; 34:13–16
5. Silva RA, Jain A, Manche EE. Prospective long-term evaluation of the efficacy, safety, and stability of the phakic intraocular lens for high myopia. *Arch Ophthalmol* 2008; 126:775–781
6. Bartels MC, Santana NT, Budo C, van Rij G, Mulder PG, Luyten GP. Toric phakic intraocular lens for the correction of hyperopia and astigmatism. *J Cataract Refract Surg* 2006; 32:243–249
7. Huang D, Schallhorn SC, Sugar A, Farjo AA, Majmudar PA, Trattler WB, Tanzer DJ. Phakic intraocular lens implantation for the correction of myopia; a report by the American Academy of Ophthalmology (Ophthalmic Technology Assessment). *Ophthalmology* 2009; 116:2244–2258. Available at: http://www.brightonvisioncenter.com/Research/Phakic_IOLs_for_Correction_of_Myopia_2009.pdf. Accessed May 11, 2013
8. Tahzib NG, Nuijts RM, Wu WY, Budo CJ. Long-term study of Artisan phakic intraocular lens implantation for the correction of moderate to high myopia; ten-year follow-up results. *Ophthalmology* 2007; 114:1133–1142
9. McCarey BE, Edelhofer HF, Lynn MJ. Review of corneal endothelial specular microscopy for FDA clinical trials of refractive procedures, surgical devices, and new intraocular drugs and solutions. *Cornea* 2008; 27:1–16. Available at: <http://www.ncbi.nlm.nih.gov/pmc/articles/PMC3062434/pdf/nihms239342.pdf>. Accessed May 11, 2013
10. Bourne WM, Nelson LR, Hodge DO. Central corneal endothelial cell changes over a ten-year period. *Invest Ophthalmol Vis Sci* 1997; 38:779–782. Available at: <http://www.iovs.org/cgi/reprint/38/3/779>. Accessed May 11, 2013
11. Kaya M, Edward DP, Tessier H, Hendricks RL. Augmentation of intraocular inflammation by melanin. *Invest Ophthalmol Vis Sci* 1992; 33:522–531. Available at: <http://www.iovs.org/content/33/3/522.full.pdf>. Accessed May 11, 2013