

Iris-fixated Anterior Chamber Phakic Intraocular Lens for Myopia Moves Posteriorly With Mydriasis

Lars P.J. Cruysberg, MD, PhD; Muriel Doors, MD;
Tos T.J.M. Berendschot, PhD; John De Brabander, PhD;
Carroll A.B. Webers, MD, PhD; Rudy M.M.A. Nuijts, MD, PhD

ABSTRACT

PURPOSE: To elucidate the physiological characteristics of eyes implanted with iris-fixated anterior chamber phakic intraocular lenses (pIOLs), which are increasingly being used for the correction of higher myopic and hyperopic refractive errors.

METHODS: In a case series of 20 patients (39 eyes), the position of the pIOL to the natural lens and the cornea was evaluated under photopic (135 lux) and low mesopic (<1 lux) circumstances with anterior segment optical coherence tomography.

RESULTS: The distance between the pIOL and the natural lens decreased, and congruently, the distance from the pIOL to the corneal endothelium increased under low mesopic circumstances.

CONCLUSIONS: The distance between the pIOL and the corneal endothelium increases when the pupil dilates under dark circumstances, contributing to the already excellent safety data available on pIOL implantation. [*J Refract Surg.* 2009;25:394-396.]

Iris-fixated anterior chamber phakic intraocular lenses (pIOLs) are increasingly being used for the correction of higher myopic and hyperopic refractive errors.¹⁻³ Although safety data on these lenses are excellent when strict inclusion criteria for surgery are applied,^{4,5} some physiological characteristics of the eye with a pIOL implantation still need further elucidation. Although several studies have investigated the influence of accommodation on the position of the pIOL,⁶⁻⁸ the effect of darkness-induced pupillary dilation on pIOL position has yet to be reported.

From the Department of Ophthalmology, University Eye Center, Maastricht, The Netherlands.

The authors have no financial interest in the materials presented herein.

The authors thank Frenne Verbakel for technical support and the collection of data that were used in this research.

Correspondence: Lars P.J. Cruysberg, MD, PhD, Dept of Ophthalmology, University Eye Center Maastricht, PO Box 5800, NL-6202 AZ Maastricht, The Netherlands. Tel: 31 43 3875346; Fax: 31 43 3875343; E-mail: lcruysberg@gmx.net

Received: June 7, 2008

Accepted: October 14, 2008

Posted online: December 15, 2008

PATIENTS AND METHODS

The position of the pIOL (Artisan; Ophtec BV, Groningen, The Netherlands) to the natural lens and the corneal endothelium was evaluated under ambient photopic (135 lux) and low mesopic (<1 lux) circumstances with Visante Optical Coherence Tomography (OCT; Carl Zeiss Meditec Inc, Dublin, Calif). Nineteen patients received bilateral pIOLs, one patient had a unilateral pIOL implant. All patients (male/female = 8/12) were myopic preoperatively, with a mean spherical equivalent refractive error of -12.50 ± 5.40 diopters (D). Average patient age at the time of this study was 51.9 ± 9.6 years (range: 33 to 67 years). All patients had stable refractions when the scans were performed.

A single examiner scanned all eyes and performed the measurements with a caliper system provided by the manufacturer. All patients received a myopic pIOL with an optic size of 6 mm. Shortest distances were measured between the pIOL and the natural lens, between the pIOL and the center of the cornea, and between the peripheral edge of the pIOL and the corneal endothelium. Statistics were performed with a paired *t* test. Values are given as mean \pm standard deviation.

RESULTS

Figures 1 and 2 show the distance of the natural lens to the pIOL, and the distance between the peripheral edge of the pIOL and the corneal endothelium, in light and dark, respectively.

For the right eye (n=19), the distance between the pIOL and the natural lens decreased by 0.08 ± 0.07 mm from light to dark ($P < .001$). Congruently, the distance from the pIOL to the corneal endothelium increased by 0.08 ± 0.06 mm ($P < .001$). The distance between the peripheral edge of the pIOL and the corneal endothelium increased 0.10 ± 0.10 mm ($P < .001$) on the nasal side and 0.10 ± 0.08 mm ($P = .001$) on the temporal side.

For the left eye (n=20), from light to dark, a decrease of the pIOL–natural lens distance of 0.05 ± 0.09 mm ($P = .035$) was observed, as well as an increase of 0.04 ± 0.08 mm ($P = .043$) of the pIOL–corneal endothelium distance. The peripheral edge of the pIOL diverged from the corneal endothelium by 0.07 ± 0.09 mm ($P = .003$) nasally and 0.04 ± 0.11 ($P = .078$) temporally, going from light to dark. Results are displayed in a scatter diagram (Fig 3).

DISCUSSION

It is apparent that the average distance between the pIOL and the natural lens decreases when the pupil dilates under dark circumstances. The measured increased distance between the pIOL and the corneal endothelium is congruent with this outcome.

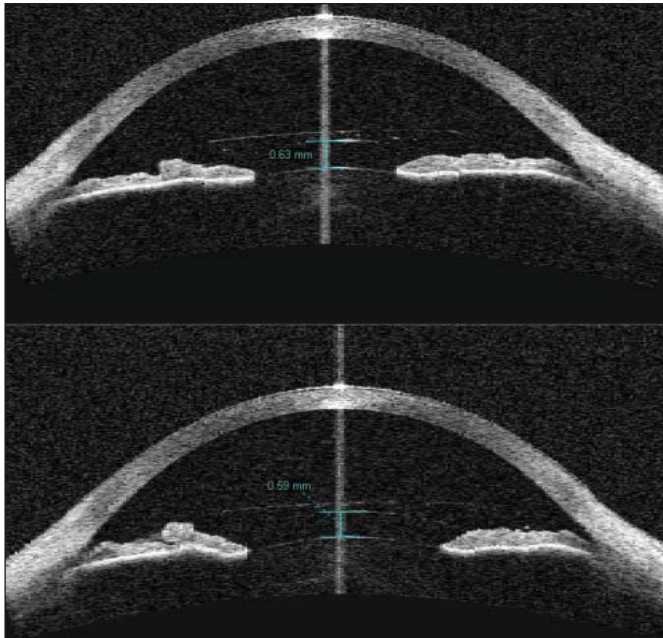


Figure 1. Visante OCT (Carl Zeiss Meditec Inc, Dublin, Calif) images showing the location of the phakic intraocular lens (pIOL) in reference to the natural lens and the cornea in light (upper panel) and dark (lower panel) circumstances. Note the pIOL movement towards the natural lens under low mesopic circumstances (distance pIOL-natural lens 0.59 mm) compared to the photopic situation (distance pIOL-natural lens 0.63 mm).

Using Visante OCT, it is expected to have some degree of target-induced accommodation. Although this potentially could change the position of the pIOL, this phenomenon would occur both in light and dark circumstances, preserving the difference between the photopic and low mesopic measurements.

It should be noted that anterior movement of the natural lens could occur due to over-accommodation under dark circumstances,⁹ which could potentially also shorten the distance between the pIOL and the natural lens. However, the distance between the pIOL and the natural lens was reported to remain constant during accommodation,⁷ in agreement with Helmholtz's theory of accommodation, which is characterized by a forward movement of the diaphragm iris-crystalline lens. It is conceivable that accommodation-induced miosis under light circumstances would result in an anterior motion of both the natural lens as well as the pIOL, thereby keeping the distance between them roughly unaffected. Our findings suggest that change in pupil-size, rather than accommodation, would have more of an impact on pIOL movement.

In the literature, Kohnen et al¹⁰ describe a case in which a patient received pIOL implantation in both eyes. The postoperative recovery for the right eye was uneventful, but in the left eye a myopic shift of 4.00 D was observed 10 days after implantation. After pharma-

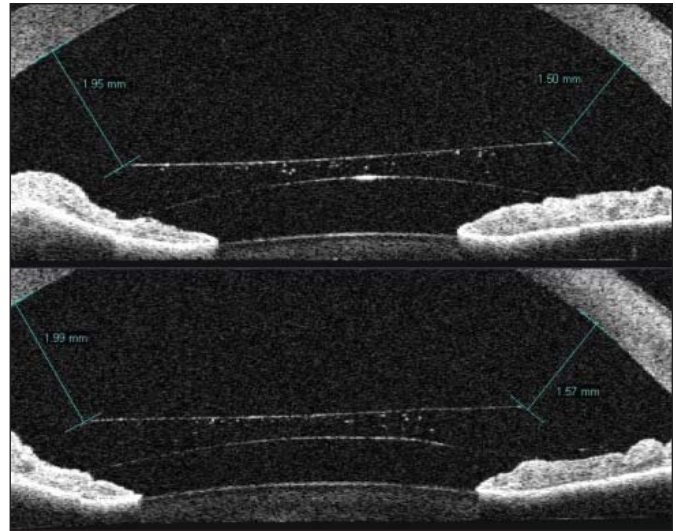


Figure 2. Detailed Visante OCT (Carl Zeiss Meditec Inc, Dublin, Calif) images in photopic (upper panel) and low mesopic (lower panel) circumstances. Note that the distance between the peripheral edge of the phakic intraocular lens (pIOL) and the corneal endothelium increases under low mesopic circumstances (1.99 mm and 1.57 mm) compared with the photopic state (1.95 mm and 1.50 mm), whereas at the same time the distance between the pIOL and the natural lens decreases.

cological pupil dilation with tropicamide this myopic shift completely disappeared. According to the authors, one of the possible causes of this acute emmetropization could be an increase in the pIOL-natural lens distance after dilation with tropicamide. Interestingly, in our study almost all of our patients showed an actual decrease of the pIOL-natural lens distance after darkness-induced pupil dilation. Similarly, the fellow eye of the patient experiencing the myopic shift also showed a decrease of the pIOL-natural lens distance after cycloplegia, as did the left eye after re-enclavation of the pIOL. The reason for this is not fully understood, but the authors hypothesized that a shifting distance between the pIOL and the crystalline lens, a pulling action of the pIOL on the ciliary body, or a mechanical stimulation by the pIOL to local innervation or vascularization leading to ciliary muscle contraction all could be contributing factors.

The posterior displacement of the pIOL in dark would translate to a slight hyperopic shift under scotopic/low mesopic circumstances. However, even for high myopic correction this is only 0.25 D. The increased distance of the peripheral edge of the pIOL to the corneal endothelium under low mesopic conditions is an important outcome, contributing to the already excellent safety data available on pIOL implantation when strict inclusion criteria are observed. In general, a safety margin of 1.5-mm distance from the peripheral edge of the pIOL to the corneal endothelium is applied

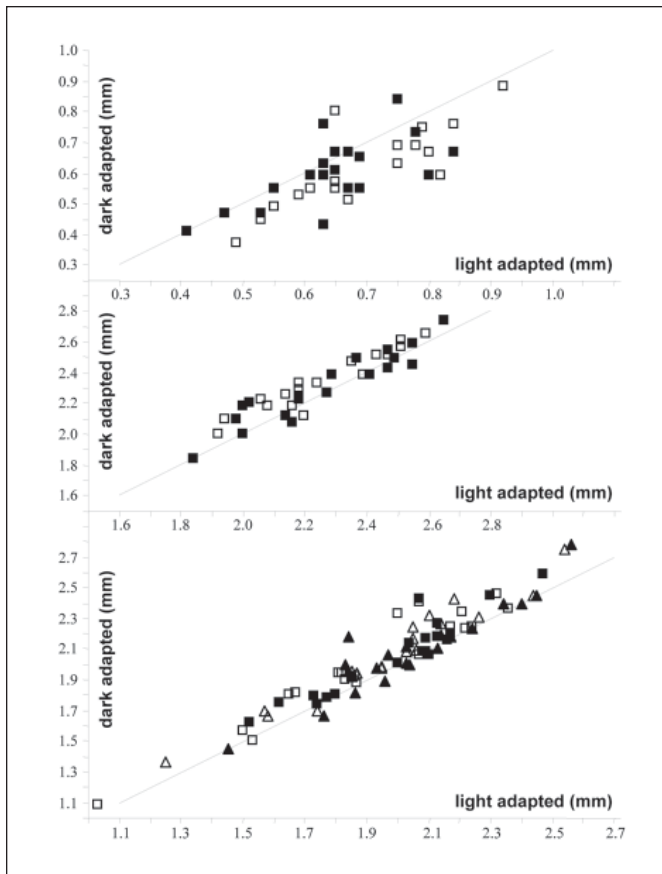


Figure 3. Scatter diagrams showing the difference between the photopic and low mesopic adapted condition for the distance between the natural lens and the phakic intraocular lens (pIOL) (upper panel), the distance between the corneal endothelium and the center of the pIOL (middle panel), and the distance between the cornea and edge of the pIOL optic (lower panel). Open symbols signify data of the right eye and closed symbols of the left eye. Squares in the lower panel represent data taken at the nasal site, triangles show data taken at the temporal site. The solid lines show the equality.

in photopic conditions. This distance becomes even greater in dark circumstances, thereby further decreasing the risk of endothelial cell loss.

REFERENCES

1. Budo C, Hessloehl JC, Izak M, Luyten GP, Menezo JL, Sener BA, Tassignon MJ, Termote H, Worst JG. Multicenter study of the Artisan phakic intraocular lens. *J Cataract Refract Surg.* 2000;26:1163-1171.
2. Saxena R, Landes M, Noordzij B, Luyten GP. Three-year follow-up of the Artisan phakic intraocular lens for hypermetropia. *Ophthalmology.* 2003;110:1391-1395.
3. Baumeister M, Bühren J, Kohnen T. Position of angle-supported, iris-fixated, and ciliary sulcus-implanted myopic phakic intraocular lenses evaluated by Scheimpflug photography. *Am J Ophthalmol.* 2004;138:723-731.
4. Tahzib NG, Nuijts RM, Wu WY, Budo CJ. Long-term study of Artisan phakic intraocular lens implantation for the correction of moderate to high myopia: ten-year follow-up results. *Ophthalmology.* 2007;114:1133-1142.
5. Benedetti S, Casamenti V, Benedetti M. Long-term endothelial changes in phakic eyes after Artisan intraocular lens implantation to correct myopia: five-year study. *J Cataract Refract Surg.* 2007;33:784-790.
6. Baikoff G, Lutun E, Wei J, Ferraz C. Contact between 3 phakic intraocular lens models and the crystalline lens: an anterior chamber optical coherence tomography study. *J Cataract Refract Surg.* 2004;30:2007-2012.
7. Guell JL, Morral M, Gris O, Gaytan J, Sisquella M, Manero F. Evaluation of Verisyse and Artiflex phakic intraocular lenses during accommodation using Visante optical coherence tomography. *J Cataract Refract Surg.* 2007;33:1398-1404.
8. Sekundo W, Bissmann W, Tietjen A. Behaviour of the phakic iris-claw intraocular lens (Artisan/Verisyse) during accommodation: an optical coherence biometry study. *Eur J Ophthalmol.* 2007;17:904-908.
9. Leibowitz HW, Owens DA. Night myopia and the intermediate dark focus of accommodation. *J Opt Soc Am.* 1975;65:1121-1128.
10. Kohnen T, Cichocki M, Bühren J, Baumeister M. Intermittent myopic shift of 4.0 diopters after implantation of an Artisan iris-supported phakic intraocular lens. *J Cataract Refract Surg.* 2005;31:1444-1447.