

Posterior Iris Fixation of the Iris-Claw Intraocular Lens Implantation through a Scleral Tunnel Incision

MEHMET BAYKARA, HIKMET OZCETIN, SAMI YILMAZ, AND ÖZGÜR BÜLENT TIMUÇIN

- **PURPOSE:** To evaluate the technique, efficacy, and safety of posterior iris fixation of iris-claw intraocular lens (IOLs) implantation through a scleral tunnel incision for aphakia correction.
- **DESIGN:** Noncomparative, interventional case series.
- **METHODS:** A secondary posterior iris fixation of the Artisan iris-claw IOL (Ophthec BV, Groningen, The Netherlands) was implanted for aphakia correction in the authors' clinical practice. Uncorrected visual acuity, best spectacle-corrected visual acuity (BSCVA), astigmatism, manifest refraction, lens position, pigment dispersion, and intraocular pressure (IOP) were evaluated in 32 consecutive eyes of 32 patients.
- **RESULTS:** BSCVA was 20/40 or better in 28 eyes (87.50%) during the mean follow-up time (nine months). Mean postoperative spherical equivalent was -0.70 diopters (D; standard deviation [SD], 0.47 D) at six months after surgery. Mean prediction error was -0.13 D (SD, 0.28 D), and mean absolute prediction error was 0.26 D (SD, 0.15 D). Preoperative mean astigmatism was -1.08 D (SD, 0.55 D; range, 0.0 to -2.0 D). At six months after surgery, mean astigmatism was -2.1 D (SD, 0.81 D; range, -0.75 to -3.75 D). There was no significant postoperative IOP increase. Lens position, evaluated by Oculus Pentacam (Pentacam 70700; Oculus, Wetzlar, Germany) and ultrasound biomicroscopy [UBM] (Ophthalmic Technologies Inc, Toronto, Ontario, Canada), was parallel to the iris plane.
- **CONCLUSIONS:** Posterior iris fixation of the iris-claw IOL implantation through a scleral tunnel incision is a safe procedure and an effective option for aphakic eyes without capsule support. (Am J Ophthalmol 2007;144:586–591. © 2007 by Elsevier Inc. All rights reserved.)

THE SURGICAL CORRECTION OF APHAKIC EYES WITHOUT adequate capsular support usually presents a difficult management problem. Debate persists between selections of an angle-supported anterior chamber intraocular lens (IOLs) or a sutured posterior chamber IOL.^{1–3} There is no consensus on the indications, relative safety, or efficacy of these alternatives.

AJO.com Supplemental Videos available at AJO.com.

Accepted for publication Jun 4, 2007.

From the Department of Ophthalmology, Uludag University School of Medicine, Bursa, Turkey.

Inquiries to Mehmet Baykara, Department of Ophthalmology, Uludag University School of Medicine, 16059 Gorukle/Bursa, Turkey; e-mail: mehmetbaykara@yahoo.com; obtimucin@myynet.com

Scleral-fixated IOLs have disadvantages, including that the suturing technique is difficult, surgical time is long, and intraocular manipulation is excessive, even with the use of newer techniques. However, the surgical procedure of a recently developed angle-supported anterior chamber IOL is safe and fast, and the IOL is easy to implant in the anterior chamber; vitreous manipulations usually are not required. However, angle-supported anterior chamber IOLs also are associated with complications, some of which are direct consequences of the presence of haptics in the iridocorneal angle.⁴

In 1986, the first iris-claw IOL was implanted in a phakic eye by Worst and Fechner. Some studies already have indicated favorable visual outcomes and a low incidence of intraoperative and postoperative complications with the current model.^{5–7} The Artisan Aphakia IOL (Ophthec BV, Groningen, The Netherlands), one of the latest versions of the iris-fixated IOL, is a single-piece polymethyl methacrylate (PMMA) which has the longest record of safety as an IOL material. The PMMA IOL haptics attach to the iris with clips on both sides of the optic. The haptics have fine fissures to capture, through enclavation, a fold of midperipheral iris stroma, where the iris is virtually immobile, less vascularized, and less reactive.⁸ This makes the iris-claw IOL independent of anterior segment size.

However, a 5.4-mm posterior corneal incision is needed for the Artisan Aphakia implantation procedure because of the PMMA material. The scleral tunnel incision for cataract surgery was designed to reduce astigmatism and to create a more secure wound.⁹ The implantation of the iris-claw IOL behind the iris better preserves the anatomy of the anterior segment with respect to the iridocorneal angle. In this study, we evaluated the technique, visual results, and Pentacam (Pentacam 70700; Oculus, Wetzlar, Germany) and ultrasound biomicroscopy [UBM] (Ophthalmic Technologies Inc, Toronto, Ontario, Canada) evaluations of secondary posterior fixation of Artisan Aphakia iris-claw IOL implantation through a scleral tunnel incision for aphakia correction and management of potential complications.

METHODS

THIS STUDY CONCERNED 32 EYES OF 32 PATIENTS WITH ages ranging from 45 to 80 years (20 men, 12 women) who underwent iris-claw IOL implantation by the same surgeon (M.B.) between October 21, 2005 and August 14, 2006 at

Uludag University, Bursa, Turkey. All patients were fully informed of the details and possible risks of the procedure, and informed consent was obtained from each patient before his or her inclusion in the study.

Inclusion criteria were as follows: complicated cataract surgery with extensive capsule rupture with or without vitreous loss. Exclusion criteria for iris-claw IOL implantation were iris defect, fixed dilated pupil, glaucoma, recurrent uveitis history, and proliferative diabetic retinopathy.

Preoperative and postoperative evaluations included subjective refraction, uncorrected visual acuity (UCVA), best spectacle-corrected visual acuity (BSCVA), keratometry, IOLMaster (Zeiss Humphrey, Zeiss Meditec, Jena, Germany) evaluation, anterior segment evaluation by the Oculus Pentacam, IOL position seen by the UBM, slit-lamp examination, Goldmann applanation tonometry, indirect fundus examination, and gonioscopy. Postoperative examinations were performed at first day, the first week, and one, two, six, and nine months after surgery.

The Artisan Aphakia iris-claw lens is a PMMA IOL with an 8.5-mm length, a 1.04-mm maximum height, and a 5.0-mm clear optical zone. It is available in convex plano and biconvex design. The optic power was calculated by using the SRK/T formula. The manufacturer's recommendation is 115.0. We assumed a surgeon's factor A constant of 116.5. IOL calculations were performed for all patients before surgery. Thirty-two consecutive postoperative refractions in spherical equivalents (SE) at one month and at six months were compared with the computerized target noted at the time of surgery. Target refraction was defined as the calculated refraction on the printout for a given power of implant. Thirty-two consecutive postoperative SE measurements at six months and preoperative target SE measurements were compared with the Wilcoxon signed-rank test. IOL power was altered in an attempt to obtain 1 diopter (D) of residual myopia in older patients; our choice was to favor a slight residual myopia. In general, the refraction aim was between emmetropia and -1.0 D, but varied according to individual circumstances.

• **SURGICAL TECHNIQUE:** Ocular anesthesia was general, retrobulbar, or peribulbar, depending on patient needs and surgeon preference. Eyes were prepared by cleaning the area with povidone-iodine (Betadine), isolating the lashes, and inserting a lid speculum. The surgical technique was as follows under retrobulbar anesthesia (4 ml proportional combination of mepivacaine 2% and bupivacaine 0.75%): the operative eye was prepared properly and draped in a sterile manner. The first plane of a 4-mm long and 5-mm width scleral tunnel incision is at 12 o'clock, and two vertical paracentral paracentesis (at the 10- and 2-o'clock positions) were performed. Bi-manual anterior vitrectomy was performed before iris-claw IOL insertion with a vitrectomy system (Dorc Associate System, Zuidland, The Netherlands). After an intracameral injection of acetylcholine 1% through the

paracentesis, cohesive viscoelastic material (sodium hyaluronate 1%) was placed behind the pupillary plane to tamponade the vitreous. Then the second plane of the scleral tunnel incision was performed. The iris-claw IOL was inserted through the scleral tunnel upside-down, in a reversed position (rounded side down). The iris-claw IOL was rotated with a hook into a horizontal position from 3 to 9 o'clock and centered over the pupil. A lens fixation forceps was introduced through the scleral incision. With the aid of lens fixation forceps, the iris-claw IOL was slipped through the pupil area, maintained horizontally with the forceps, then recentered over the pupil behind the iris plane with the haptics positioned again at 3 o'clock and 9 o'clock. The correct orientation of the iris-claw IOL should be checked before iris entrapment by haptics. At the same time, through the paracentesis, a modified blunt enclavation needle was introduced and the iris was entrapped by applying gentle pressure over it through the slotted center of the lens haptic. Too much pressure on the pupillary margin should be avoided by not engaging too much tissue in the claw mechanism, and the claw should not be placed too close to the iris root to prevent interference with iris movement. Displacement, ovalization, and pupil deformation should be prevented by meticulously positioning the iris claw with an adequate amount of iris tissue to guarantee pupil movement. The maneuver then was repeated on the other side, achieving perfect iris-claw IOL centration under the pupil. All manipulations were performed under viscoelastic protection. Peripheral slit iridectomy was not performed at all. Finally, all the viscoelastic material was removed carefully through an automated irrigation and aspiration system, and the conjunctiva was closed by cautery. Gentamicin 20 mg and dexamethasone 3 mg were injected subconjunctivally. Ofloxacin and aggressive dexamethasone drops were prescribed after surgery, tapered, and then discontinued within four to eight weeks. Patients were examined on postoperative days, after which follow-up was based on the individual patient's condition. Many aphakic eyes lack good pupil function, and pre-existing pathologic mydriasis is probably best managed with pupilloplasty immediately before iris-claw IOL insertion to ensure enclavation (see Supplemental Videos available at AJO.com).

RESULTS

PREOPERATIVE BSCVA WAS 20/40 OR BETTER IN SEVEN EYES (21.87%). At the first postoperative month, BSCVA was 20/40 or better in 15 eyes (46.87%), and at the second postoperative month, BSCVA was 20/40 or better in 26 eyes (81.25%). BSCVA was 20/40 or better in 28 eyes (87.50%) at the ninth postoperative month. Postoperative UCVA was equal to or better than preoperative BSCVA in 100% of eyes (32 eyes of 32 patients) at nine months of follow-up. All eyes in our series were noted to have a

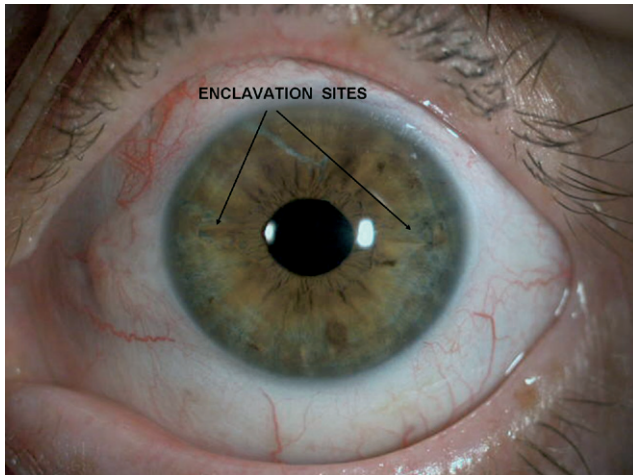


FIGURE 1. Photograph demonstrating an aspect of the anterior segment after posterior iris fixation of the iris-claw intraocular lens (IOLs). An oval shape to the pupil typically is not noted in the physiologic pupil size unless too much iris tissue was enclavated. Neither iridotomy nor iridectomy were not performed.

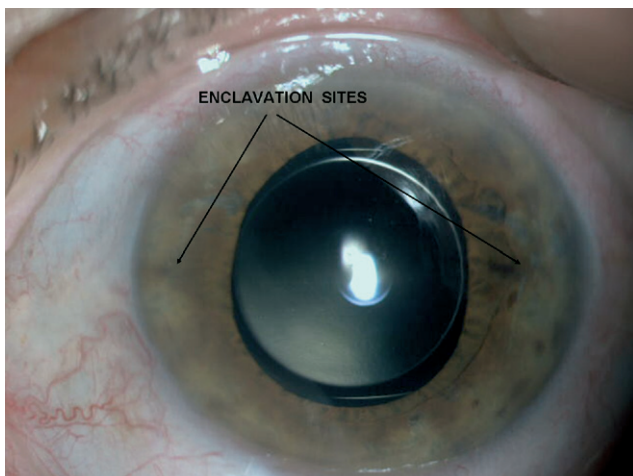


FIGURE 2. Slit-lamp photograph demonstrating posterior iris fixation of the iris-claw intraocular lens (IOLs) after pupillary dilatation.

well-centered IOL at the time of original placement and during the initial postoperative examinations. Postoperative diagnostic pupil dilation was unaffected (Figures 1 and 2). Nevertheless, persistent pupil ovalization from iris entrapment by haptics was seen in four eyes (12.5%) at the one-month follow-up examination. The goal of refraction was emmetropia or slight residual myopia. Mean preoperative SE refraction was 10.50 D (range, 8 to 14 D) in the 32 eyes; before surgery, our goal was a mean SE of -0.56 D (SD, 0.3 D; range, -0.12 to -1.12 D). The mean postoperative SE was -0.74 D (SD, 0.4 D) at the first month after surgery, and it was -0.70 D (SD, 0.47 D) at six months after surgery. The mean prediction error was




FIGURE 3. Scheimpflug slit-images demonstrating an aphakic posterior iris fixation of the iris-claw intraocular lens (IOLs).

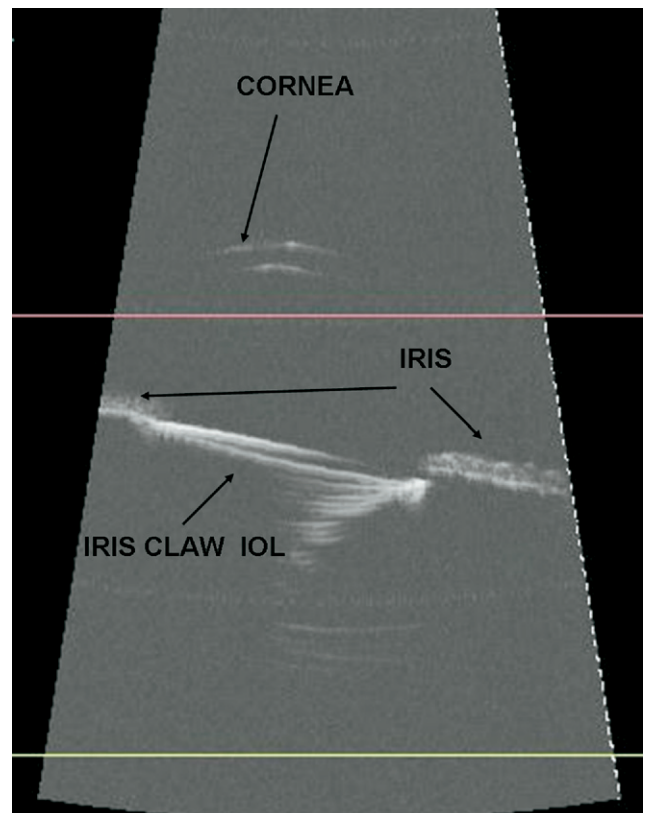


FIGURE 4. Postoperative longitudinal transverse ultrasound biomicroscopy (UBM) echogram demonstrating posterior iris fixation of the iris-claw intraocular lens (IOL) implanted under the iris. The IOL appears to be hyperechogenic with marked backscatter effect and the anterior chamber is deep.

-0.13 (SD, 0.28), and the mean absolute prediction error was 0.26 (SD, 0.15) at six months after surgery. According to the results of the Wilcoxon signed-rank test, there was no statistically significant difference between preoperative

target SE and six-month postoperative SE ($P > .05$). Preoperative mean astigmatism was -1.08 D (SD, 0.55 D; range, 0.0 to -2.0 D). At the first postoperative month, mean astigmatism was -2.18 D (SD, 0.78 D; range, -1.0 to -3.50 D). At the sixth postoperative month, mean astigmatism was -2.1 D (SD, 0.81 D; range, -0.75 to -3.75 D).

The lens position, anterior chamber depth, volume, and corneal topography were evaluated using the Pentacam (Figure 3). The lens position was analyzed using the UBM (Figure 4). The lens position was seen parallel to the iris plane with the Pentacam and UBM. Mean anterior chamber depth was 3.1 mm (range, 2.6 to 3.8 mm) before surgery and 3.2 mm (range, 2.7 to 3.9 mm) six months after the surgery; mean volume of the anterior chamber was 187 mm³ (range, 155 to 220 mm³) before surgery and 190 mm³ (range, 160 to 225 mm³) six months after surgery. During surgery, positive vitreous pressure and vitreous prolapse were observed in seven eyes (21.87%). Anterior vitrectomy was carried out successfully in these cases. Six (18.75%) of the eyes were found to have mild elevation of intraocular pressure at the postoperative first week that did not need treatment. Despite the lack of a slit-lamp–based quantitative image analysis, we did not observe a clinically significant higher incidence of pigment or nonpigment deposits on gonioscopic examination during the first month after IOL implantation. We observed no intraoperative or postoperative complications.

DISCUSSION

FOR DECADES, ANTERIOR^{10,11} AND SCLERAL-FIXATED POSTERIOR^{12,13} chamber IOLs have been the most popular type of lenses used in secondary IOL implantation in the absence of capsule support. In this series, we studied the posterior iris fixation of Artisan Aphakia iris-claw IOLs that have been used as a secondary IOL in aphakic patients. This surgical technique was designed to respect anterior segment anatomic features as closely as possible; the ideal position for the IOL after extracapsular cataract extraction is behind the iris plane. We confirmed that the anterior segment anatomic characteristics—normal anterior chamber depth and wide iridocorneal angle—were preserved with our technique.

The original reasons for working with this IOL were its location of placement in the eye, far from the corneal endothelium and avoiding the angle, and its larger optical zone. An important optical advantage is that, because of its fixation characteristics, centering the lens over the pupil is dependent on the surgeon's ability, rather than on the angle situation. The current generation of refractive, iris-fixated IOLs leave enough space between themselves and the endothelium to avoid harming the endothelium in phakic and aphakic eyes.¹⁴ Some authors have expressed concern about the potential for this iris-claw IOL to damage the iris or the corneal endothelium.^{15,16} The posterior position of the lens theoretically is safer because

of its distance from the corneal endothelium. We have not observed any corneal decompensation in our patients. We believe that using a sufficient amount of viscoelastic material during intraocular manipulation allows for separation of the tissue, protecting the endothelium.

Potential causes of the postoperative inflammation include acute iritis resulting from excessive intraoperative manipulation and chronic iritis resulting from excessive tension of the iris from the claw mechanism. We have not seen any case of acute or chronic iritis. However, the nine-month follow-up was too short to draw a conclusion about chronicity.

The anterior iris fixation of iris-claw IOLs cannot affect the pigment dispersion in the anterior chamber as long as the lens is fixed appropriately, because the amount of melanin granules in the anterior stroma of the iris is less than that in the iris pigment epithelium.¹⁷ Although some degree of immediate iris pigment epithelial loss occurs during surgery with iris fixation of a posterior chamber IOL, progressive pigment dispersion glaucoma has not been identified as a common late complication with this form of fixation in two large series.^{18,19} An IOL fixated firmly to the posterior iris surface may not create as much recurrent sweeping pigment epithelial trauma as an undersized IOL floating loosely in the sulcus.²⁰ The Artisan Aphakia iris-claw IOL has a substantially different lens design²¹ than previous generations of iris-fixated IOLs, which also were associated with complications. These lenses are anchored to the midperiphery of the iris. They have a vaulted design. This provides optimal clearance between iris and IOL. Except at the fixation points under the iris, they are slightly raised below the iris plane, which prevents them from interfering with the normal physiologic features of the iris, especially the posterior pigment epithelium, which has potential to trigger pigmentary dispersion. We did not expect to see secondary pupillary blocked glaucoma. Therefore, we did not have a preference for peripheral iridectomy. Pigmentary dispersion glaucoma has not been detected in this small group of eyes with limited follow-up. However, we expect pigment erosion secondary to posterior iris fixation of iris-claw IOL indentation to develop in some eyes. Future pigment erosion seems probable with the posterior iris fixation of the iris-claw IOL, but no conclusions can be drawn about the potential long-term consequences.

The main disadvantage of iris-claw IOL implantation has been wound size.²² A posterior corneal incision of at least 5.4 mm is needed for the procedure because of the single-piece PMMA material. Thus, postoperative astigmatism may be induced by this technique. For this reason, we preferred a scleral tunnel incision with a surgical procedure that normally does not require sutures. This, in turn, reduces the induced astigmatism. This technique has some advantages, including sutureless, self-sealing, and minimal surgically induced astigmatism. In our patients, we did not observe any complication related to the scleral tunnel incision. We believe that implanting the iris-claw IOL through a scleral tunnel promotes faster visual recovery and better visual outcomes that result from a lower postoperative induced-astigmatism and an in-

creased refractive accuracy. Moreover, in our experience, scleral tunnels are easier to enlarge than corneal tunnels. A scleral tunnel incision creates a strong wound that causes little induced corneal topographic change. In addition, the incision is self-sealing, even when its width is extended to 6.0 mm. However, using a crescent or disk knife to make a long tunnel is intricate and difficult for inexperienced surgeons. Mishaps such as early perforation can occur; thus, it is a procedure that requires suturing for sealing. In addition, the long tunnel limits manipulation during iris-claw IOL enclavation, one factor that complicates surgery.

If enclavation fails, dislocation of the iris claw IOL into the vitreous cavity results. Such a complication may result from weakly holding the IOL with forceps. In addition, inadequate tissue grasping also may cause the iris-claw haptics to become detached, especially in long-term care. We have not observed such complication. Theoretically, dislocation of the iris claw IOLs, which are posteriorly fixated, into the vitreous cavity does not seem possible. In a complete dislocation, both haptics of the iris-claw IOL are detached from their attachment point coincidentally or concomitantly. Because the visual quality deteriorates rapidly, posterior dislocation of the iris-claw IOL during posterior placement of the implant, although a remote possibility, can be recognized at an early stage and controlled or treated before it results in serious problems. Whereas for an anterior placement, there is a risk of not recognizing at an early stage dislocation of the iris-claw IOL, even with a similar one-sided spontaneous iris-claw haptic detachment.

After cataract surgery, corneal endothelial cell density decreases.^{23,24} Ravalico and associates reported that endothelial remodeling had already taken place and that endothelial cell loss was caused primarily by mechanical trauma to the endothelium at the time of surgery.²⁵ During anterior chamber lens implantation in phakic eyes, the highest surgical risk

for the endothelium is contact between the endothelium and the IOL or surgical instruments. This is also true in aphakic eyes, although from our point of view, factors such as anterior chamber collapse resulting from aphakic low scleral rigidity and the turbulence during the anterior vitrectomy maneuvers are more important. Compared with clear corneal incisions, scleral tunnel incisions were associated with lower postoperative endothelial damage, particularly at the 12-o'clock position. This is probably because the scleral tunnel incision is placed more posteriorly and therefore induces less direct and indirect endothelial trauma in patients with double surgical trauma, and thus a preference for scleral tunnel incisions seems logical.

Additionally, the implantation of the iris-claw IOL behind the iris better preserves the anatomic features of the anterior segment with respect to the iridocorneal angle. We must first demonstrate the safety and feasibility of this implantation style for aphakic posterior implantation. This series has shown the relative safety of posterior iris fixation of the iris-claw IOL implantation through a scleral tunnel incision in patients without adequate capsular support.

Until now, a simple method of combining posterior iris fixation of iris-claw IOL insertion through scleral tunnel technique, to our knowledge, has not been reported. More data are required to evaluate the mid-term and long-term safety of this lens style through a scleral tunnel for secondary implantation. Nevertheless, the simplicity of the procedure compared with transscleral sutured techniques, the reversible-adjustable fixation, reduced induced astigmatism, and the relatively low rate of associated complications compared with angle-supported anterior chamber lenses and scleral-fixated posterior chamber lenses make the iris-claw IOLs an attractive alternative. Further studies with a larger series and longer follow-up are needed to determine the safest technique and to confirm these conclusions.

THE AUTHORS INDICATE NO FINANCIAL SUPPORT. THIS STUDY WAS SELF-FUNDED. INVOLVED IN DESIGN AND CONDUCT OF study (M.B., O.B.T.); collection of data (S.Y., O.B.T.); analysis and interpretation of data (M.B., S.Y., O.B.T.); and preparation, review, and approval of the manuscript (M.B., H.O., O.B.T.). The study was designed and performed in accordance with the ethical standards of the Declaration of Helsinki, which was controlled and approved by the local ethical committee of our university.

REFERENCES

1. Evereklioglu C, Er H, Bekir NA, Borazan M, Zorlu F. Comparison of secondary implantation of flexible open-loop anterior chamber and scleral-fixated posterior chamber intraocular lenses. *J Cataract Refract Surg* 2003;29:301–308.
2. Ozmen AT, Dogru M, Erturk H, Ozcetin H. Transsclerally fixated intraocular lenses in children. *Ophthalmic Surg Lasers* 2002;33:394–399.
3. Zetterstrom C, Lundvall A, Weeber H Jr, Jeeves M. Sulcus fixation without capsular support in children. *J Cataract Refract Surg* 1999;25:776–781.
4. Sawada T, Kimura W, Kimura T, et al. Long-term follow-up of primary anterior chamber intraocular lens implantation. *J Cataract Refract Surg* 1998;24:1515–1520.
5. Fechner PU, van der Heijde GL, Worst JGF. The correction of myopia by lens implantation into phakic eyes. *Am J Ophthalmol* 1989;107:659–663.
6. Menezo JL, Martinez MC, Cisneros AL. Iris-fixated Worst claw versus sulcus-fixated posterior chamber lenses in the absence of capsular support. *J Cataract Refract Surg* 1996;22:1476–1484.
7. Guell JL, Velasco F, Malecaze F, Vasquez M, Gris O, Manero F. Secondary Artisan-Versys aphakic lens implantation. *J Cataract Refract Surg* 2005;31:2266–2271.
8. Lovisolo CF, Reinstein DZ. Phakic intraocular lenses. *Surv Ophthalmol* 2005;50:549–587.
9. Blumenthal M. Manual ECCE, the present state of the art. *Klin Monatsbl Augenheilkd* 1994;205:266–270.
10. Weene LE. Flexible open-loop anterior chamber intraocular lens implants. *Ophthalmology* 1993;100:1636–1639.

11. Rattigan SM, Ellerton CR, Chitkara DK, Smerdon DL. Flexible open-loop anterior chamber intraocular lens implantation after posterior capsule complications in extracapsular cataract extraction. *J Cataract Refract Surg* 1996;22:243–246.
12. McCluskey P, Harrisberg B. Long-term results using scleral-fixated posterior chamber intraocular lenses. *J Cataract Refract Surg* 1994;20:34–39.
13. Trimarchi F, Stringa M, Vellani G, Iato MS. Scleral fixation of an intraocular lens in the absence of capsular support. *J Cataract Refract Surg* 1997;23:795–797.
14. Budo C, Hessloehl JC, Izak M, et al. Multicentre study of the Artisan phakic intraocular lens. *J Cataract Refract Surg* 2000;26:1163–1171.
15. Menezo JL, Cisneros AL, Rodriguez-Salvador V. Endothelial study of iris-claw phakic lens: four year follow-up. *J Cataract Refract Surg* 1998;24:1039–1049.
16. Menezo JL, Avino JA, Cisneros A, Rodriguez-Salvador V, Martinez-Costa R. Iris-claw phakic intraocular lens for high myopia. *J Refract Surg* 1997;13:545–555.
17. Apple DJ, Naumann GOH, Manthey RM. Microscopic anatomy of the eye. In: Naumann GOH, Apple DJ, eds. *Pathology of the eye*. New York, New York: Springer-Verlag, 1986:19–62.
18. Schein OD, Kenyon KR, Steinert RF, et al. A randomized trial of intraocular lens fixation techniques with penetrating keratoplasty. *Ophthalmology* 1993;100:1437–1443.
19. Zeh WG, Price FW Jr. Iris fixation of posterior chamber intraocular lenses. *J Cataract Refract Surg* 2000;26:1028–1034.
20. Condon GP. Simplified small-incision peripheral iris fixation of an AcrySof intraocular lens in the absence of capsule support. *J Cataract Refract Surg* 2003;29:1663–1667.
21. Dick HB, Augustin AJ. Lens implant selection with absence of capsular support. *Curr Opin Ophthalmol* 2001;12:47–57.
22. Tehrani M, Dick HB, Schwenn O, Bloom E, Schmidt AH, Koch HR. Postoperative astigmatism and rotational stability after artisan toric phakic intraocular lens implantation. *J Cataract Refract Surg* 2003;29:1761–1766.
23. Rao GN, Aquavella JV, Goldberg SH, Berk SL. Pseudophakic bullous keratopathy: relationship to preoperative corneal endothelial status. *Ophthalmology* 1984;91:1135–1140.
24. Coli AF, Price FW Jr, Whitson WE. Intraocular lens exchange for anterior chamber intraocular lens-induced corneal endothelial damage. *Ophthalmology* 1993;100:384–393.
25. Ravalico G, Botteri E, Baccara F. Long-term endothelial changes after implantation of anterior chamber intraocular lenses in cataract surgery. *J Cataract Refract Surg* 2003;29:1918–1923.



Biosketch

Mehmet Baykara, MD, received his medical degree and specialty training from Uludag University School of Medicine in Bursa, Turkey. He worked as a fellow at the The Rosen Eye Surgery Centre with Mr Emanuel S. Rosen in 2001. Dr Baykara has been working as an Associated Professor in Ophthalmology at the Uludag University School of Medicine. He specializes in cataract, refractive, glaucoma, and anterior segment surgery departments.



Biosketch

Hikmet Ozcetin, MD, is a professor of Clinical Ophthalmology at Uludag University School of Medicine in Bursa, Turkey. He received his medical degree from Istanbul University School of Medicine and completed his Ophthalmology Residency at the Hacettepe University Hospital. In 1983, he worked as a fellow with Mr Fyodorov at Moscow Research Institute of Eye Microsurgery on radial keratotomy and clear lens surgery. Dr Ozcetin was involved in the establishment of the Turkish Society of Cataract and Refractive Surgery and became its director from 1990 to 1994 and 1998 to 2000. His research field has been radial keratotomy, phakic IOLs, and clear lens surgery. Dr Ozcetin has published more than 70 papers in international and national medical journals and has written five books, in Turkish, on cataract, myopia, and their managements.