

Long-term Follow-up of Endothelial Cell Change after Artisan Phakic Intraocular Lens Implantation

Ruchi Saxena, MD,¹ Sharmila S. Boekhoorn, MD,² Paul G. H. Mulder, PhD,² Bastiaantje Noordzij,¹ Gabriel van Rij, MD, PhD,¹ Gre P. M. Luyten, MD, PhD^{1,3}

Objective: To report endothelial cell densities (ECDs) and their correlation to anterior chamber depth (ACD) after implantation of the Artisan intraocular phakic lens.

Design: Prospective observational case series.

Participants: Three hundred eighteen eyes of 173 myopic patients treated with the Artisan iris-fixed phakic intraocular lens (IOL).

Methods: Eyes with an ACD ranging between 2.89 and 4.5 mm were implanted with the Artisan phakic IOL. Endothelial cell density measurements were performed preoperatively and at each follow-up examination using a noncontact specular microscope.

Main Outcome Measures: Endothelial cell density (cells per square millimeter).

Results: Follow-up ranged between 1 (82 eyes) and 7 years (13 eyes) (mean, 35.3 ± 20.7 [standard deviation] months per eye). After 3 years, there was a significant loss in ECD ($P \leq 0.03$). At 5 years, mean observed endothelial cell loss was 8.3% (5.3% corrected for a natural endothelial cell loss of 0.6% a year). Endothelial cell density loss remained progressive throughout our follow-up period. After 3 years, a significant negative correlation between ACD and endothelial cell loss was revealed ($P \leq 0.03$). Patient age, gender, refractive error, incision size, and side of the eye were not correlated to ECD loss. All corneas remained clear throughout the study.

Conclusion: After 3 years, a significant ECD loss was revealed. This ECD loss was significantly negatively correlated to the ACD. We therefore suggest that eyes just meeting the minimum ECD requirement have greater ACDs to compensate for possible greater endothelial cell loss and that patients with shallow anterior chambers have higher ECDs. Artisan phakic lens implantation in young eyes narrowly meeting the minimum criteria of endothelial cell density (2000 cells/mm²) and ACD (2.6 mm) should perhaps be reevaluated, due to longer exposure to higher rates of endothelial cell loss. *Ophthalmology* 2008;115:608–613 © 2008 by the American Academy of Ophthalmology.



The Artisan lens was first introduced by Worst in 1978 for aphakic eyes under the name Iris Claw. In 1986, refractive surgeons began to implant the iris-fixed lens in phakic myopic eyes. Thereafter, developments also led to lenses for the correction of hyperopia and mixed

astigmatism. More recently, a foldable version of the lens, the Artiflex, was introduced. Multicenter clinical trials have demonstrated that these lenses are safe and have a high efficacy.^{1–3} However, from the time of its use, there have been concerns that this anterior chamber (AC) lens could damage the endothelial cell layer due to its close proximity to the cornea.^{4,5} In fact, an earlier biconcave model was modified to a convex–concave lens for this reason.⁶ The manufacturer advises the use of the Artisan lens only in eyes with an endothelial cell density (ECD) > 2000 cells/mm² and an AC depth (ACD) > 2.6 mm (from the corneal epithelium to the crystalline lens). Furthermore, patients are advised not to rub their eyes after lens implantation, as possible warping of the peripheral cornea may cause the endothelial cell layer to rub against the intraocular lens (IOL). Still, most studies have not revealed significant endothelial cell loss, although most had relatively short follow-ups.^{3,7–9} Our previous research in hyperopic patients demonstrated an

Originally received: December 1, 2006.

Final revision: May 20, 2007.

Accepted: May 21, 2007.

Available online: August 7, 2007.

Manuscript no. 2006-1383.

¹ Department of Ophthalmology, Erasmus Medical Center, Rotterdam, Netherlands.

² Department of Epidemiology & Biostatistics, Erasmus University, Rotterdam, Netherlands.

³ Department of Ophthalmology, University Medical Center Leiden, Leiden, Netherlands.

The authors have no proprietary or financial interest in any of the products or equipment mentioned.

Reprint requests to Ruchi Saxena, MD, Department of Ophthalmology, Erasmus MC, s-Gravendijkwal 230, 3015 CE Rotterdam, Netherlands.

Table 1. Patient Population Demographics (318 Eyes, 173 Patients)

| | |
|---|--|
| Age (yrs) | 38.5 ± 10.1 (range, 18–61) |
| Male | 34.1% |
| Mean spherical refractive error (diopters) | -12.25 ± 4.20 (range, -1.00 to -23.50) |
| Mean anterior chamber depth (mm) | 3.70 ± 0.30 (range, 2.89–4.50) |
| Mean preoperative endothelial cell density (cells/mm ²) | 2817 ± 356 (range, 1993–3979) |
| Type of lens (n) | |
| 5.0 mm | 152 (57 toric) |
| 6.0 mm | 149 |
| Artiflex | 17 |

inversely proportional relationship between the ACD and endothelial cell loss in our 3- and 12-month follow-ups.¹⁰

In this study, we examine the long-term relationship between ACD and endothelial cell loss in myopic eyes.

Materials and Methods

The following inclusion criteria were used in this study: ACD > 2.6 mm; ECD > 2000 cells/mm²; pupil (in scotopic light conditions) < 6 mm; stable refractive error for a minimum of 1 year; no corneal, iris, or pupil abnormalities; and general good health. Eyes having undergone more than one operation were excluded from analysis after their subsequent procedure.

Preoperative examinations included subjective and objective refractive error with and without cyclopentolate 1.0% eyedrops, best-corrected visual acuity (Snellen), Javal keratometry, applanation tonometry, slit-lamp examination, fundus examination, and ECD. The ACD (distance between corneal epithelium and crystalline lens) and axial length were measured by A-scan immersion biometry using OcuScan (Alcon, Irvine, CA). The results from the ultrasound with the highest and straightest peaks from 10 different measurements (with a standard deviation of ≤7) were used. All ECD measurements were performed on an SP-2000P unit (Topcon, Tokyo, Japan). These were based on photographs of the central cornea. Between 1996 and 2002, these consisted of the average of 2 manual ECDs where the center of a minimum of 50 cells was marked (center or dot technique). If there was a large difference between the 2 counts, another ECD measurement would be

performed. After 2002, we used automated measurements with the retracing method by means of the IMAGEnet software program (Topcon), with the same specular microscope.¹¹ All complete cells on the image were used to measure the cell density. The value of 0.6% per year was used to estimate natural endothelial cell loss.¹²

Each patient was informed about the procedure and signed a detailed informed consent form in accordance with the Helsinki Declaration. The lens power was calculated using the van der Heijde formula. All lens implantations were performed according to protocol by one experienced surgeon (GPML).¹⁰ We received approval from the institutional review board/ethics committee of our institution for this study.

Statistics

We used paired Student's *t* tests to test for differences between preoperative and postoperative endothelial cell densities. A mixed model analysis of variance was applied to determine a relationship between endothelial cell loss and ACD, correcting for the factors age, gender, left or right eye, refractive error (higher power IOLs are thicker), and lens type (Artiflex, 5.0 mm, and 6.0 mm). Spatial correlation structure of the repeated measurements within an eye was employed. SAS for Windows software (SAS Institute, Cary, NC) and SPSS statistical software (version 11.0, SPSS Inc., Chicago, IL) were used for data analysis.

Results

Patient demographics are listed in Table 1. Three hundred eighteen eyes implanted with the Artisan Myopia Claw Lens of 173 patients with a minimum follow-up of 1 year were included. Patients were operated between February 1997 and September 2004. Mean follow-up was 35.3 ± 20.7 months per eye. Patients were excluded from the study after they had undergone lens exchange (n = 5), cataract extraction (CE) (n = 4), or retinal detachment surgery (n = 1) or experienced a pupillary block glaucoma (n = 1). The surgeon (GPML) chose to include one eye with an ECD of 1993 cells/mm² (which narrowly missed the inclusion criteria) after conferring with the patient. Data of some of these eyes have been published in previous reports.^{2,3,8}

Table 2 shows the endothelial cell loss between 3 months and 7 years postoperatively. There is an initial yet insignificant rise in endothelial cells in the first postoperative year. Endothelial cell loss was significant from 3 years onwards, also when corrected for an expected natural cell loss of 0.6% per year.¹²

Table 2. Mean Endothelial Cell Density (ECD) and Standard Deviation (SD) over 7 Years

| Period | No. of Eyes | Mean ECD (Cells/mm ²) ± SD | Mean ECD Change (Cells/mm ²) ± SD | Mean Observed Percentage ECD Change | Mean Expected Percentage ECD Change in an Unoperated Eye with 0.6% Cell Loss/Year | Mean Observed – Expected ECD Change |
|--------------|-------------|--|---|-------------------------------------|---|-------------------------------------|
| Preoperative | 318 | 2817 ± 356 | NA | NA | NA | NA |
| 3 mos | 220 | 2856 ± 385 | -34 ± 269 | +1.9 | -0.2 | +2.1 |
| 6 mos | 248 | 2848 ± 425 | -37 ± 296 | +1.7 | -0.3 | +2.0 |
| 1 yr | 251 | 2813 ± 426 | -7 ± 290 | +0.5 | -0.6 | +1.1 |
| 2 yrs | 168 | 2777 ± 376 | 42 ± 327 | -0.8 | -1.2 | +0.4 |
| 3 yrs | 122 | 2729 ± 342 | 96 ± 406* | -2.2 | -1.8 | -0.4 |
| 4 yrs | 69 | 2616 ± 307 | 291 ± 502* | -6.5 | -2.4 | -4.1 |
| 5 yrs | 51 | 2581 ± 293 | 285 ± 501* | -8.3 | -3.0 | -5.3 |
| 6 yrs | 28 | 2560 ± 270 | 380 ± 608* | -9.1 | -3.5 | -5.5 |
| 7 yrs | 13 | 2451 ± 256 | 557 ± 805* | -12.6 | -4.1 | -8.5 |

NA = not applicable.

**t* test, preoperative versus postoperative, *P* ≤ 0.03.

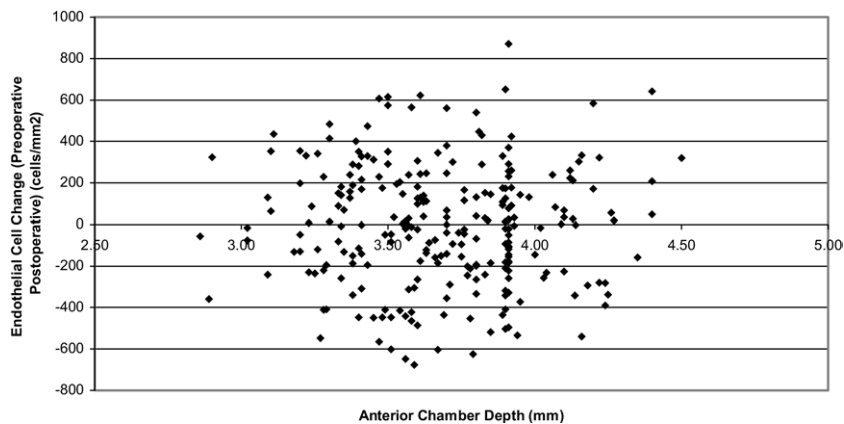


Figure 2. Relationship between anterior chamber depth and endothelial cell loss (preoperative endothelial cell density [ECD] – postoperative ECD) per patient at 1 year postoperatively (n = 251). Mixed model analysis of variance ($P > 0.05$) is corrected for patient age, refractive error, gender, left or right eye, and lens type.

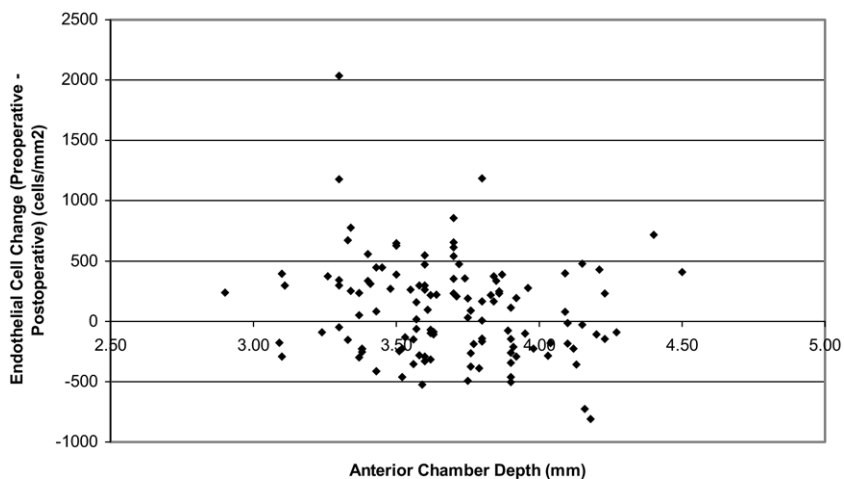


Figure 4. Relationship between anterior chamber depth and endothelial cell loss (preoperative endothelial cell density [ECD] – postoperative ECD) per patient at 3 years postoperatively (n = 122). Mixed model analysis of variance ($P = 0.03$) is corrected for patient age, refractive error, gender, left or right eye, and lens type.

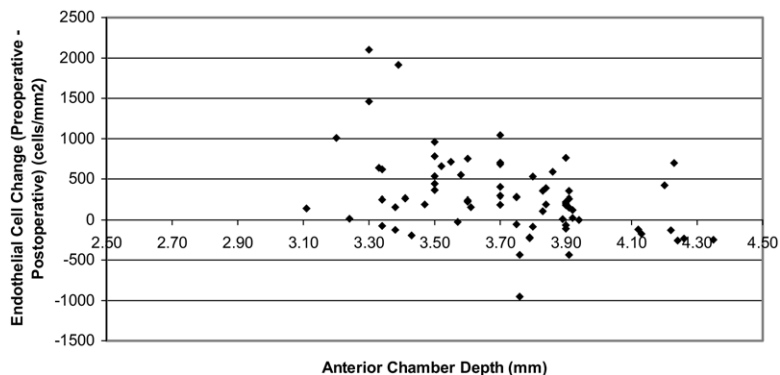


Figure 5. Relationship between anterior chamber depth and endothelial cell loss (preoperative endothelial cell density [ECD] – postoperative ECD) per patient at 4 years postoperatively (n = 69). Mixed model analysis of variance ($P = 0.002$) is corrected for patient age, refractive error, gender, left or right eye, and lens type.

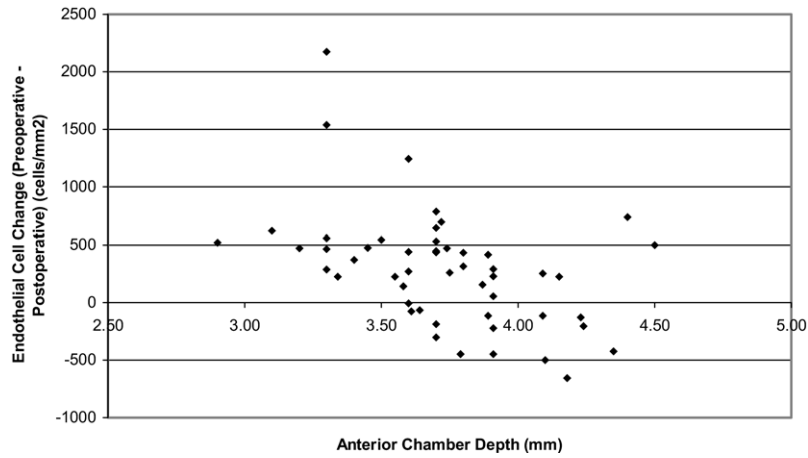


Figure 6. Relationship between anterior chamber depth and endothelial cell loss (preoperative endothelial cell density [ECD] – postoperative ECD) per patient at 5 years postoperatively (n = 51). Mixed model analysis of variance ($P = 0.0001$) is corrected for patient age, refractive error, gender, left or right eye, and lens type.

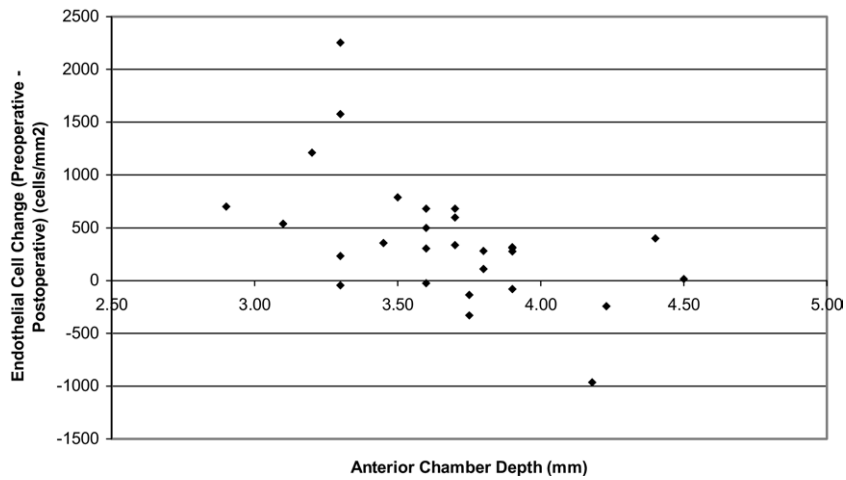


Figure 7. Relationship between anterior chamber depth and endothelial cell loss (preoperative endothelial cell density [ECD] – postoperative ECD) per patient at 6 years postoperatively (n = 28). Mixed model analysis of variance ($P = 0.0001$) is corrected for patient age, refractive error, gender, left or right eye, and lens type.

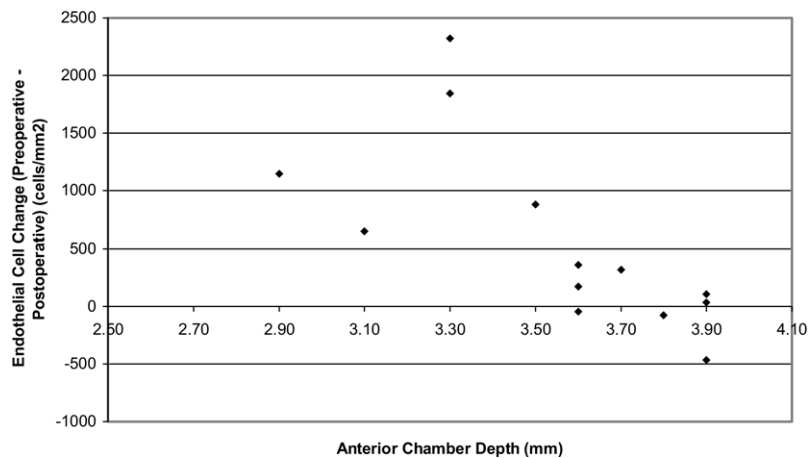


Figure 8. Relationship between anterior chamber depth and endothelial cell loss (preoperative endothelial cell density [ECD] – postoperative ECD) per patient at 7 years postoperatively (n = 13). Mixed model analysis of variance ($P < 0.0001$) is corrected for patient age, refractive error, gender, left or right eye, and lens type.

Figures 1 to 8 (Figs 1 and 3 available at <http://aaajournal.org>) display the relationship between ACD and ECD, corrected for patient age, refractive error, gender, left or right eye, and lens type. After 3 years, a significant negative correlation was revealed.

All corneas remained clear throughout our follow-up period. There were no significant differences in endothelial cell loss between the 3 different lens types (Artiflex, 5 mm, and 6 mm require incisions of 3.2, 5.2, and 6.2 mm, respectively). Age and gender of the patient and refractive error of the lens (difference in lens thickness) did not show a correlation with endothelial cell loss, nor did the side of the eye.

Discussion

In our study, we found a significant endothelial cell loss in our patient population starting at 3 years after implantation of the Artisan iris-fixated phakic IOL. Endothelial cell loss in our population, 8.3% (5.3% when correcting for natural loss), was relatively higher than that of other studies.¹³⁻¹⁶ However, some of these studies had a relatively shorter follow-up.^{13,14,16} Additionally, similar to other reports, there was an initial yet insignificant increase in cells the first postoperative year.^{1,7,10,16} Though we did not account for this preoperatively, we believe that the increase in ECD may have been caused by endothelial cell migration from the peripheral to the central cornea after contact lens discontinuation by some of our patients, although this pattern of cell distribution has been disputed.¹⁷⁻¹⁹ Moreover, ECD measurements have been found to be less accurate immediately postoperatively.²⁰ The size of the incision did not appear to play a role in cell loss, reinforcing previously reported results.¹⁴ Other studies on the Artisan lens do confirm our findings of progressive endothelial cell loss.^{4,15} Continued endothelial cell loss has also been noted in pseudophakic eyes 10 years after CE.²¹

Furthermore, we found a significant negative correlation between ACD and loss of endothelium. Menezo et al also found a correlation with ACD after 6 months of their 4-year endothelial study and noted significant postoperative endothelial cell loss. As the cell hexagonality remained stable after 2 years, loss of endothelium was attributed to the implantation procedure rather than to the lens itself. The correlation between ACD and cell loss after half a year was considered to be a possible consequence of intraoperative contact.¹⁵ In our study, the negative correlation between endothelial cell loss and ACD only became evident after 3 years and remained significant up to our 7-year follow-up. The factors mentioned previously, as well as corneal wound reorganization, may have blurred a relationship between ACD and decrease in ECD in earlier postoperative years.^{15,22}

One patient with preoperative ECDs of 2910 (right eye) and 2706 (left eye) had ECDs of 586 (right) and 863 (left) after 7 years with clear corneas. Serial ECD measurements made the first postoperative year (7 times) showed a continual progressive loss; however, the greatest ECD loss occurred between years 1 and 2 (before the switch to IMAGENet). We could not explain the dramatic decrease in ECD, as the corneas were unremarkable preoperatively, as were the implant procedures. The patient did not rub his eyes and was not known to have allergies. He did

undergo uncomplicated strabismus surgery on both eyes within 1 year of Artisan lens implantation, although the procedures took place after the greatest amount of cell loss had already taken place.

We performed endothelial cell counts using the center or dot technique before 2002 and the retracing method thereafter.¹¹ Thus, the cell measurements of our longer follow-up patients were calculated using 2 different counting methods on the same specular microscope. On regular inspection, the calibration was checked but showed no differences before and after 2002. Although significant ECD loss was only noted after 3 years of follow-up (whereby some patients were operated before we switched to the IMAGENet program), a similar pattern of loss was found among our hyperopic patients, with whom all follow-up examinations took place before the IMAGENet system was being used.¹⁰ Nonetheless, it has been demonstrated that the center or dot technique is not as precise as the retracing method, which could question the accuracy of our (preoperative) measurements, although these could have been both underestimated or overestimated.¹¹ Analysis of cell hexagonality and polymegathism would have strengthened this study, but unfortunately, these data were not available on most eyes operated before 2002. The study is further limited by the number of patients available for follow-up examinations; at 3 years, data from only 122 of the 318 eyes were available, and at 7 years, from only 13. This partial follow-up was due to the majority of patients having been operated on more recently, whereby the data are not yet available.

Although our study showed significant endothelial cell loss, all of the corneas remained clear. Still, we do find the cell loss noteworthy and offer an approach to the inclusion criteria other than what the manufacturer advises. First, considering the progressive endothelial cell loss we encountered, we recommend lifelong patient follow-up. Patients should be made aware of this before being operated. We further suggest a stricter inclusion criteria for younger patients, proposing ACDs of ≥ 3.5 mm. This could offset the decrease in ACD with age, which we have found to be 0.12 mm/decade (Cheng YYY, Bhagwandien ACE, Wolfs RCW, Luyten GPM, submitted for publication, 2006). Moreover, it could partially compensate for cell loss after lens implantation. Analogous suggestions were also made by Fechner et al in 1998.²³ Most importantly, we advise that some of the inclusion criteria no longer be looked at individually but as a whole: patient age, ACD, and ECD should be considered jointly. For example, young patients with relatively shallow ACs and ECDs just above 2000 cells/mm² should perhaps no longer be considered for implantation of these lenses. Longer follow-up studies of endothelial cell loss in relation to the ACD are necessary before definitive criteria, including patient age, can be reasonably determined. We suggest that surgeons use their clinical judgment when assessing young potential candidates narrowly meeting the inclusion criteria for the Artisan phakic IOL.

Our study showed a significant progressive endothelial cell loss after 3 years and a significant negative correlation between endothelial cell loss and ACD. We suggest caution

in operating young patients who narrowly meet the inclusion criteria for ACD and ECDs.

References

1. Bartels MC, Santana NT, Budo C, et al. Toric phakic intraocular lens for the correction of hyperopia and astigmatism. *J Cataract Refract Surg* 2006;32:243–9.
2. Bartels MC, Saxena R, van den Berg TJ, et al. The influence of incision-induced astigmatism and axial lens position on the correction of myopic astigmatism with the Artisan toric phakic intraocular lens. *Ophthalmology* 2006;113:1110–7.
3. Budo C, Hessloehl JC, Izak M, et al. Multicenter study of the Artisan phakic intraocular lens. *J Cataract Refract Surg* 2000;26:1163–71.
4. Landesz M, Worst JG, van Rij G. Long-term results of correction of high myopia with an iris claw phakic intraocular lens. *J Refract Surg* 2000;16:310–6.
5. Menezo JL, Cisneros A, Hueso JR, Harto M. Long-term results of surgical treatment of high myopia with Worst-Fechner intraocular lenses. *J Cataract Refract Surg* 1995;21:93–8.
6. Landesz M, Worst JG, Siertsema J, van Rij G. Negative implant: a retrospective study. *Doc Ophthalmol* 1993;83:261–70.
7. Guell JL, Vazquez M, Malecaze F, et al. Artisan toric phakic intraocular lens for the correction of high astigmatism. *Am J Ophthalmol* 2003;136:442–7.
8. Landesz M, van Rij G, Luyten G. Iris-claw phakic intraocular lens for high myopia. *J Refract Surg* 2001;17:634–40.
9. Pop M, Payette Y. Initial results of endothelial cell counts after Artisan lens for phakic eyes. An evaluation of the United States Food and Drug Administration Ophtec Study. *Ophthalmology* 2004;111:309–17.
10. Saxena R, Landesz M, Noordzij B, Luyten GP. Three-year follow-up of the Artisan phakic intraocular lens for hypermetropia. *Ophthalmology* 2003;110:1391–5.
11. van Schaick W, van Dooren BT, Mulder PG, Volker-Dieben HJ. Validity of endothelial cell analysis methods and recommendations for calibration in Topcon SP-2000P specular microscopy. *Cornea* 2005;24:538–44.
12. Bourne WM, Nelson LR, Hodge DO. Central corneal endothelial cell changes over a ten-year period. *Invest Ophthalmol Vis Sci* 1997;38:779–82.
13. Alio JL, de la Hoz F, Perez-Santonja JJ, et al. Phakic anterior chamber lenses for the correction of myopia: a 7-year cumulative analysis of complications in 263 cases. *Ophthalmology* 1999;106:458–66.
14. Benedetti S, Casamenti V, Marcaccio L, et al. Correction of myopia of 7 to 24 diopters with the Artisan phakic intraocular lens: two-year follow-up. *J Refract Surg* 2005;21:116–26.
15. Menezo JL, Cisneros AL, Rodriguez-Salvador V. Endothelial study of iris-claw phakic lens: four year follow-up. *J Cataract Refract Surg* 1998;24:1039–49.
16. Asano-Kato N, Toda I, Hori-Komai Y, et al. Experience with the Artisan phakic intraocular lens in Asian eyes. *J Cataract Refract Surg* 2005;31:910–5.
17. Amann J, Holley GP, Lee SB, Edelhauser HF. Increased endothelial cell density in the paracentral and peripheral regions of the human cornea. *Am J Ophthalmol* 2003;135:584–90.
18. Perez-Santonja JJ, Sahla HF, Alio JL. Evaluation of endothelial cell changes 1 year after excimer laser in situ keratomileusis. *Arch Ophthalmol* 1997;115:841–6.
19. Wiffen SJ, Hodge DO, Bourne WM. The effect of contact lens wear on the central and peripheral corneal endothelium. *Cornea* 2000;19:47–51.
20. Wirbelauer C, Wollensak G, Pham DT. Influence of cataract surgery on corneal endothelial cell density estimation. *Cornea* 2005;24:135–40.
21. Bourne WM, Nelson LR, Hodge DO. Continued endothelial cell loss ten years after lens implantation. *Ophthalmology* 1994;101:1014–22, discussion 1022–3.
22. Werblin TP. Long-term endothelial cell loss following phacoemulsification: model for evaluating endothelial damage after intraocular surgery. *Refract Corneal Surg* 1993;9:29–35.
23. Fechner PU, Singh D, Wulff K. Iris-claw lens in phakic eyes to correct hyperopia: preliminary study. *J Cataract Refract Surg* 1998;24:48–56.

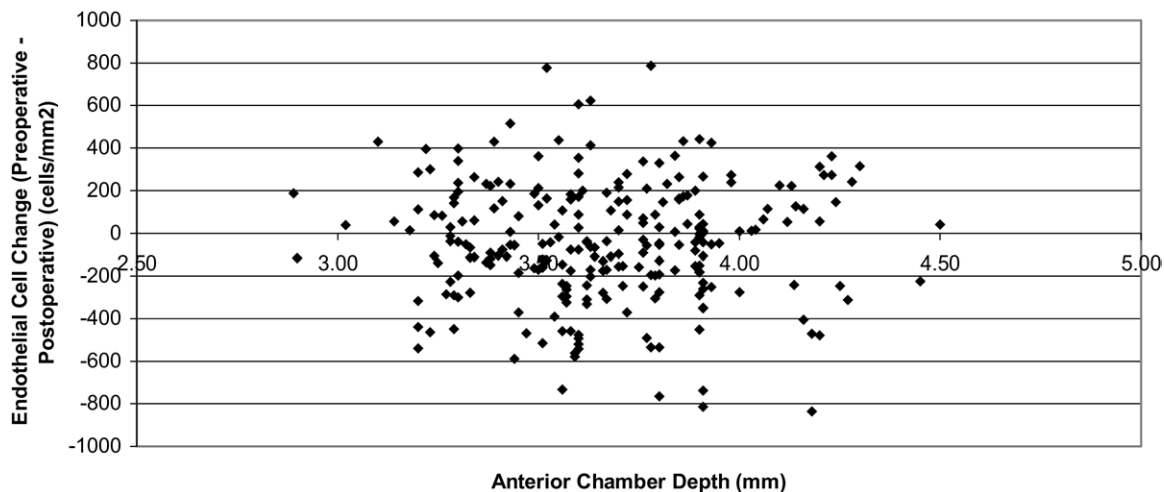


Figure 1. Relationship between anterior chamber depth and endothelial cell loss (preoperative endothelial cell density [ECD] – postoperative ECD) per patient at 6 months postoperatively (n = 248). Mixed model analysis of variance ($P>0.05$) is corrected for patient age, refractive error, gender, left or right eye, and lens type.

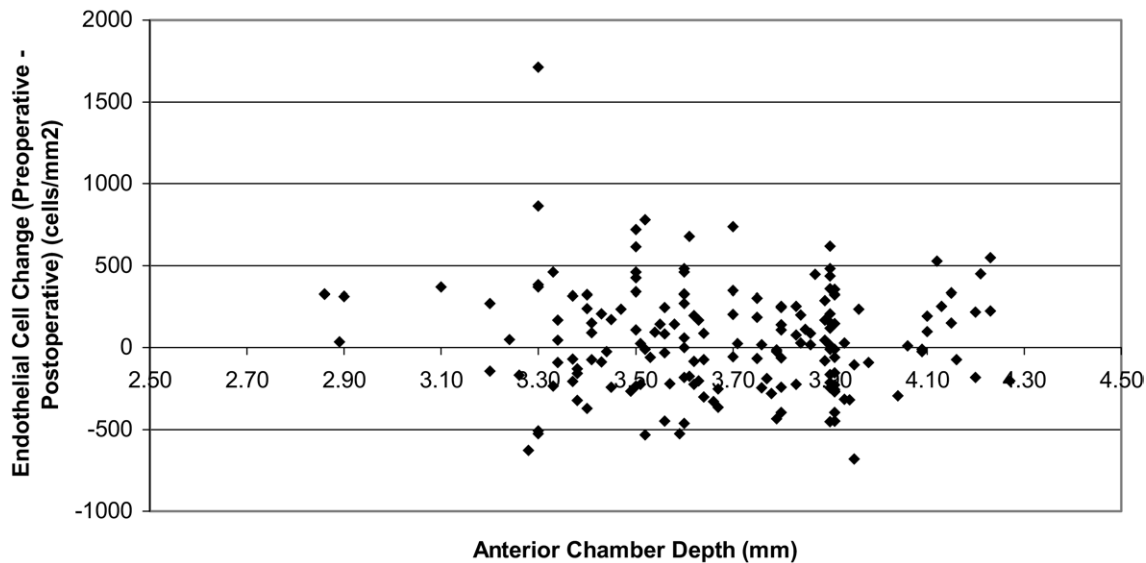


Figure 3. Relationship between anterior chamber depth and endothelial cell loss (preoperative endothelial cell density [ECD] – postoperative ECD) per patient at 2 years postoperatively (n = 168). Mixed model analysis of variance ($P>0.05$) is corrected for patient age, refractive error, gender, left or right eye, and lens type.