

Endothelial Cell Loss After Toric Iris-fixated Phakic Intraocular Lens Implantation: Three-year Follow-up

Mana Tehrani, MD; H. Burkhard Dick, MD

ABSTRACT

PURPOSE: To study quantitative changes in endothelial cell count after implantation of the toric iris-fixated phakic intraocular lens.

METHODS: A prospective, non-randomized, self-controlled clinical trial was conducted of 40 eyes (28 myopic, 12 hyperopic) of 23 patients with high ametropia and astigmatism. Non-contact computer-assisted endothelial microscopy was performed before and 1, 2, and 3 years after surgery.

RESULTS: In the myopic group, mean preoperative endothelial cell count was 3179 ± 531 cells/mm² (range: 1800 to 3900 cells/mm²). The mean intra-individual endothelial cell loss was $-1.83 \pm 2.25\%$ (range: -9.09% to 0%) in the first year; $-1.83 \pm 2.95\%$ (range: -7.74% to 3.80%) in the second year; and $-3.20 \pm 4.43\%$ (range: -14.25% to 1.91%) three years after surgery, compared to preoperative values. In the hyperopic group, mean preoperative endothelial cell count was 3107 ± 125 cells/mm² (range: 2932 to 3300 cells/mm²). The mean endothelial cell loss was $-1.63 \pm 1.76\%$ (range: -3.23% to 1.67%) in the first year; $-0.05 \pm 1.25\%$ (range: -1.65% to 1.75%) in the second year; and $-2.88 \pm 2.03\%$ (range: -5.33% to -0.13%) three years after surgery, compared to preoperative values.

CONCLUSIONS: Annual cumulative cell loss was -1.9% for the myopic group and -1.6% for the hyperopic group, which is two to three times greater than physiological annual cell loss in normal eyes without surgery. An annual endothelial cell count analysis is highly recommended in every patient after iris-claw lens implantation to detect potential progressive cell loss at an early stage. [*J Refract Surg.* 2007;23:172-177.]

Intraocular procedures with phakic lenses represent a promising alternative in the correction of myopia, hyperopia, and astigmatism. The advantages of using phakic intraocular lenses (PIOLs) include the ability to correct high refractive errors up to 20.00 diopters (D), preservation of accommodation, and reversibility of the procedure.¹ The iris-claw PIOL has been successfully implanted over several years in phakic eyes for the correction of refractive errors.¹⁻⁹ However, progressive endothelial cell loss remains a major concern with anterior chamber PIOLs.⁸

Because placement of the PIOL torus in the exact astigmatism axis is mandatory,^{1,10-12} toric iris-fixated PIOL enclavation can often be associated with increased surgical manipulation in the anterior chamber. Intraoperative re-enclavation maneuvers may be necessary to finally position the PIOL torus exactly where it is intended. Several studies with short-term follow-up have addressed endothelial cell loss after implantation of the spherical iris-fixated PIOL.¹³⁻¹⁵ To our knowledge, there have been no previous reports about endothelial cell loss after implantation of the toric iris-fixated PIOL with longer follow-up.^{1,11} This prospective study was designed to evaluate 3-year follow-up changes in endothelial cell loss after implantation of the toric iris-fixated PIOL.

PATIENTS AND METHODS

A prospective study involving 23 patients (40 eyes) who underwent surgery at the University Hospital, Department of

From the Department of Ophthalmology, Johannes Gutenberg-University, Mainz, Germany (Tehrani); and Center for Vision Science, Ruhr University Eye Hospital, Bochum, Germany (Dick).

The authors have no proprietary or financial interest in the materials presented herein.

Presented in part at the American Society of Cataract and Refractive Surgery meeting; March 18-22, 2006; San Francisco, Calif.

Correspondence: Mana Tehrani, MD, Dept of Ophthalmology, Johannes Gutenberg-University, Langenbeckstr. 1, 55101 Mainz, Germany. Tel: 49 6131 17 2589; E-mail: mtehrani@hotmail.de

Received: December 19, 2005

Accepted: June 27, 2006

Posted online: December 15, 2006

Ophthalmology, Mainz, Germany, from February 2000 to September 2001 (consecutive series) was conducted. Eyes were divided into a myopic group (n=28) and hyperopic group (n=12). All eyes were examined before and 1, 2, and 3 years after surgery.

Patients aged >18 years, with stable refraction for at least 1 year and astigmatism >1.50 D, with an otherwise normal ophthalmologic examination, and with unsatisfactory correction with spectacles or contact lenses for medical, professional, or personal requirements, were included in the study. All patients were fully informed about the details and possible risks of the procedure. Written informed consent was obtained from all patients before surgery in accordance with the Declaration of Helsinki. The study was approved by the local ethics committee. Exclusion criteria were anisometropia, anterior segment pathology, inadequate eyelid closure, endothelial cell count <1800 cells/mm², anterior chamber depth <3.0 mm, abnormal iris or pupil function, fixed pupil size >4.5 mm, recurrent or chronic uveitis, any form of cataract, previous corneal or intraocular surgery, intraocular pressure (IOP) >21 mmHg, glaucoma or family history of glaucoma, retinal detachment or family history of retinal detachment, pre-existing macular degeneration or macular pathology, systemic diseases, chronic treatment with corticosteroids or any immunosuppressive treatment or state, and pregnancy.

The toric Artisan lens (Ophtec BV, Groningen, The Netherlands; Verisyse, Advanced Medical Optics Inc, Santa Ana, Calif), consists of Perspex CQ-UV polymethylmethacrylate with Tinuvin 326, a benzotriazole exhibiting effective ultraviolet light filtration up to approximately 400 nm. The optic diameter is 5.0 mm and the overall length 8.5 mm. Available PIOL powers range from -3.00 to -23.50 D for myopia and +2.00 to +12.00 D for hyperopia, with a cylindrical correction from 1.00 to 7.00 D in 0.50-D increments.

PRE- AND POSTOPERATIVE VISITS

Pre- and postoperative endothelial cell counts were performed using the RhineTec Sea Eagle endothelial non-contact specular microscope (RhineTec, Krefeld, Germany). The surface of the endothelium that was scanned measured 970×720 μm. Fifty images were automatically generated to analyze the center of the cornea. Automatic hexagonal cell count (with optional manual cell count) was performed, and mean values were derived. Percentage loss in endothelial cell count (ECC) was calculated using the following formula:

$$\text{ECC (\%)} = \frac{\text{ECC}_{\text{pre}} - \text{ECC}_{\text{post}}}{\text{ECC}_{\text{pre}}}$$

Preoperative preparation was the same as for typical cataract surgery but included miotic drops (pilocarpine 1% to 2%) to prepare the iris for lens fixation. A superior sclerocorneal self-sealing 5.1- to 5.3-mm incision and two paracenteses were created in all eyes. A cohesive ophthalmic viscosurgical device (Healon OVD, Advanced Medical Optics Inc) was injected through the paracenteses to maintain a sufficient anterior chamber depth and protect endothelial cells. The precise cylindrical axial orientation of the PIOL was determined using marks on the limbus that had been placed immediately before surgery or natural structures such as iris crypts, pigments, or vessels identified via photographs. The lens was then enclavated onto the iris. If necessary, a re-enclavation maneuver was performed to ensure precise placement of the PIOL torus at the intended astigmatism axis. At the end of the implantation procedure all viscoelastic material was removed.

Endothelial cell count was evaluated 1, 2, and 3 years postoperatively. A descriptive statistical analysis was conducted using SPSS Version 11.0 (SPSS Inc, Chicago, Ill). Continuous variables were described with mean, standard deviation, median, minimum, and maximum values. Box plots were used for annual analysis of endothelial cell loss.

RESULTS

Patient age ranged from 21 to 61 years in the myopic group, and from 25 to 49 years in the hyperopic group. Twenty-three eyes were female, and 17 eyes were male. Patient demographic data are shown in Table 1.

MYOPIC GROUP

The mean preoperative spherical equivalent refraction was -9.84 ± 4.98 D (range: -21.50 to -2.50 D). The mean anterior chamber depth was 3.67 ± 0.36 mm (range: 3.03 to 4.23 mm). The mean preoperative endothelial cell count was 3179 ± 531 cells/mm² (range: 1800 to 3900 cells/mm²). One year postoperatively, the mean change in endothelial cell count was 3276 ± 313 cells/mm², indicating an intraindividual cell change of $-1.83 \pm 2.25\%$ (range: -9.09% to 0%). Two years postoperatively, the mean endothelial cell count was 3069 ± 523 cells/mm², indicating a $-1.83 \pm 2.95\%$ mean loss (range: -7.74% to 3.80%). Three years postoperatively, the mean endothelial cell count was 2925 ± 444 cells/mm², signifying a mean loss of $-3.20 \pm 4.43\%$ (range: -14.25% to 1.91%).

HYPEROPIC GROUP

The mean preoperative spherical equivalent refraction was $+3.43 \pm 1.58$ D (range: $+1.50$ to $+6.25$ D). The mean anterior chamber depth was 3.32 ± 0.266 mm

TABLE 1

Summary of Preoperative Data for Myopic and Hyperopic Eyes That Underwent Artisan Phakic Intraocular Lens Implantation

	Myopic Eyes	Hyperopic Eyes
Mean spherical equivalent (range) (D)	-9.84±4.98 (-21.50 to -2.50)	+3.43±1.58 D (+1.50 to +6.25)
Mean sphere (range) (D)	-8.08±5.09 (-19.00 to -0.50)	+5.104±1.56 (+3.50 to +6.50)
Mean cylinder (range) (D)	-3.58±1.26 (-7.00 to -1.75)	-3.37±0.88 (-4.25 to -1.50)
Range of anterior chamber depth (mm)	3.03 to 4.23	2.99 to 3.84
Range of axial length (mm)	23.16 to 31.84	20.69 to 22.69
Range of implant power (D)	-3.25 to -20.00	+2.00 to +7.50

(range: 2.99 to 3.84 mm). The mean preoperative endothelial cell count was 3107 ± 125 cells/mm² (range: 2932 to 3300 cells/mm²). One year postoperatively, the mean endothelial cell count was 3063 ± 104 cells/mm², indicating a mean cell loss of $-1.63 \pm 1.76\%$ (range: -3.23% to 1.67%). Two years postoperatively, the mean endothelial cell count was 3024 ± 139 cells/mm², representing a $-0.05 \pm 1.25\%$ mean loss of endothelial cells (range: -1.67% to 1.75%). Three years postoperatively, the mean endothelial count was 3028 ± 171 cells/mm², indicating a mean loss of $-2.88 \pm 2.03\%$ (range: -5.33% to -0.13%) of endothelial cells.

The mean cumulative endothelial cell loss per year was -1.9% in the myopic group and -1.6% in the hyperopic group. Descriptive analysis and *P* values are given in Table 2.

Figures 1 and 2 represent the absolute change in mean endothelial cell count per year and the relative endothelial cell count losses over time per group.

COMPLICATIONS

No intraoperative complications occurred. Postoperatively, one eye experienced transient corneal edema, which resolved completely after 1 week. Immediately after surgery, two eyes experienced increased intraocular pressure (IOP), which normalized without the need for local therapy after 1 day. A postoperative wound leak with low IOP (4 to 8 mmHg) and flattening of the anterior chamber occurred in one eye, requiring a suture closure of the corneoscleral tunnel incision. Successful repositioning of the lens was performed in one hyperopic eye 1 week postoperatively because of deviation from the target axis.

DISCUSSION

Progressive endothelial cell loss is a major concern in anterior chamber PIOLs. Several studies^{2,15} have addressed this potential mid- and long-term complication

after implantation of the iris-fixated IOL in phakic eyes with variable outcomes. Especially for the hyperopic eye with small anterior segment anatomy, long-term evolution in terms of segment anatomical changes and long-term perspective is of high interest.

Our study represents the first report of endothelial cell count changes after implantation of the toric iris-fixated PIOL in a 3-year follow-up. The mean individual endothelial cell loss in the myopic group was -1.83% 1 year postoperatively, -1.83% 2 years postoperatively, and -3.20% 3 years postoperatively compared to preoperative values. In the hyperopic group, the mean intraindividual endothelial cell loss was -1.63% 1 year postoperatively, -0.05% 2 years postoperatively, and -2.88% 3 years postoperatively, compared to preoperative values.

Several studies have been published addressing this type of complication after iris-claw lens implantation; the majority of studies were performed for myopic correction.

For myopic eyes Landesz et al^{2,3} reported a progressive endothelial cell loss of -5.5% after 6 months, -7.2% after 12 months, and 9.1% after 2 years. Their 2001 study showed no significant change in endothelial cell density from baseline.² Perez-Santonja et al^{4,13} described an endothelial cell loss of -7.3% at 3 months, -10.6% at 6 months, -13.0% at 1 year, and -17.6% at 2 years after implantation. Menezo et al¹⁴ reported a mean endothelial loss of -3.9% at 6 months, -6.6% at 1 year, -9.2% at 2 years, -11.7% at 3 years, and -13.4% at 4 years after implantation. At 2 years after implantation, the hexagonality and coefficient variation in endothelial cell size were close to the preoperative levels. The morphological changes recovered, suggesting that endothelial damage occurred primarily during the surgical procedure. A correlation was detected between anterior chamber depth or implant power and amount of endothelial cell loss. The

TABLE 2

Relative and Absolute Intraindividual Endothelial Cell Change for Myopic and Hyperopic Eyes That Underwent Artisan Phakic Intraocular Lens Implantation

Endothelial Cell Count (%)						
Follow-up	N	Median (Quartile 1 and Quartile 3)	Range	P Value	Mean	SD
Myopic group						
1 y	28	-1.39 (-2.77/0)	-9.09 to 0	.001	-1.83	2.25
2 y	28	-1.80 (-3.95/-0.46)	-7.74 to 3.8	.013	-1.83	2.95
3 y	28	-2.44 (-4.71/-0.668)	-14.25 to 1.91	.021	-3.20	4.43
Hyperopic group						
1 y	12	-2.13 (-3.12/-0.27)	-3.23 to 1.67	.125	-1.63	1.76
2 y	12	0.20 (-1.44/0.863)	-1.67 to 1.75	1	-0.05	1.25
3 y	12	-2.88 (-4.83/-1.05)	-5.33 to -0.13	.063	-2.88	2.03
Endothelial Cell Count (cells/mm ²)						
Follow-up	N	Median (Quartile 1 and Quartile 3)	Range	P Value	Mean	SD
Myopic group						
Preop	28	3350 (2900/3525)	1800 to 3900	–	3179	531
1 y	28	3300 (3050/3525)	2675 to 3822	–	3276	313
2 y	28	3192 (2735/3486)	1778 to 3764	–	3069	523
3 y	28	2983 (2782/3190)	1812 to 3425	–	2925	444
Hyperopic group						
Preop	12	3085 (3000/3225)	2932 to 3300	–	3107	125
1 y	12	3050 (3000/3174)	2900 to 3212	–	3063	104
2 y	12	3037 (2886.5/3114)	2850 to 3256	–	3024	139
3 y	12	3020 (2918/3170)	2717 to 3200	–	3028	171

SD = standard deviation

Top half of the table represents relative changes and the bottom half represents absolute changes.

shallower the anterior chamber depth or the higher the implant power (thicker PIOL), the higher the cell loss. However, a comparison to our results is difficult because Menezo et al used bi-concave models, and we implanted the current, modified model, which is convex-concave.

In the US Food and Drug Administration clinical study of 765 eyes implanted with the Artisan PIOL, Pop and Payette¹⁵ reported implantation of the myopic iris-claw lens did not result in significant change in endothelial cell density up to 2 years after surgery. Percentage change from baseline at 6, 12, and 24 months was $-0.09 \pm 16.39\%$, $-0.78 \pm 16.35\%$, and $0.78 \pm 17.41\%$, respectively. No correlation between implant power and endothelial cell loss was observed. In a study of 60 myopic eyes, Benedetti et al¹⁶ reported a mean endothelial cell loss of -2.8% at 4 months, -3.9% at 12 months, and -5.4% at 24 months.

In a clinical study of 57 hyperopic eyes, Alio et al⁹ reported an overall corneal endothelial cell loss of -9.4% at 1-year follow-up. In a prospective study including 27 myopic eyes with a mean preoperative astigmatism of -3.43 ± 0.81 D that underwent toric correction via toric iris-claw lens implantation, Guell et al¹¹ demonstrated a mean gain of endothelial cells of -2.9% 12 months postoperatively. In 16 eyes that underwent toric iris-claw lens implantation for correction of postkeratoplasty astigmatism, Nuijts et al¹⁷ reported a mean endothelial cell loss of $-7.6 \pm 18.9\%$ at 3 months and $-16.6 \pm 20.4\%$ at last follow-up (18 months). Dick et al¹ demonstrated a 4.5% mean total loss of endothelial cell count in 70 eyes after toric iris-claw lens implantation during the first 6 months after surgery.

Our data revealed lower significant endothelial cell loss values compared to those described by Dick et al¹

3-year Follow-up of Toric Iris-fixated PIOLs/Tehrani & Dick

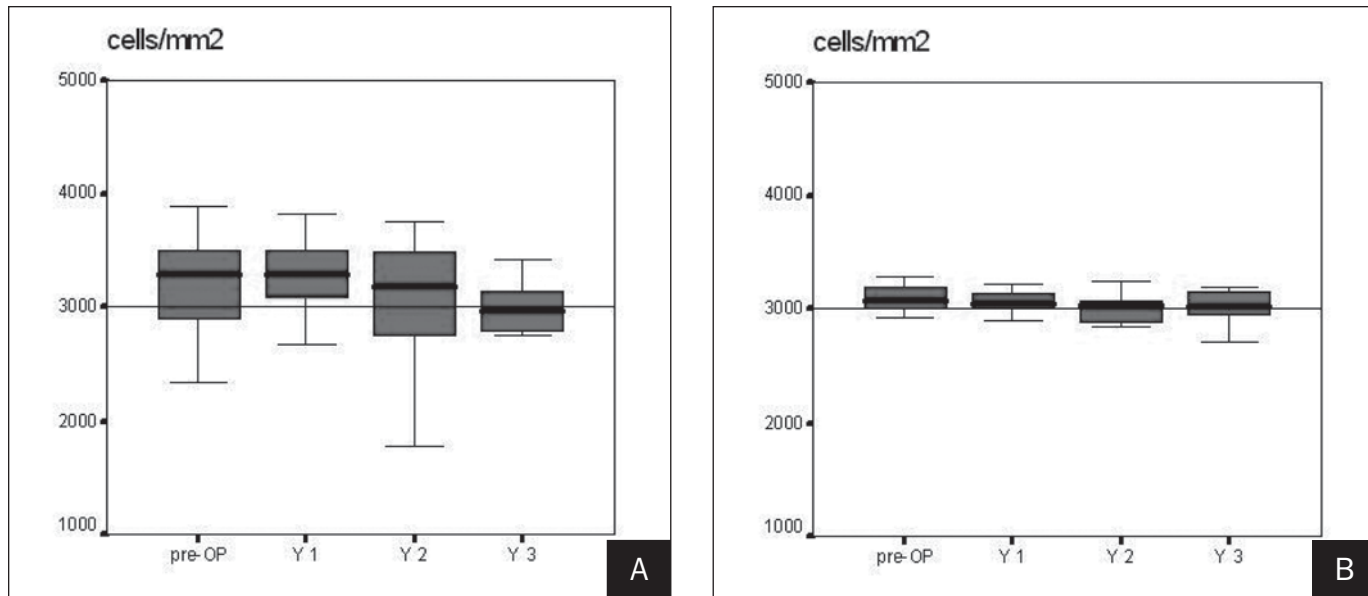


Figure 1. Change in cell count per year during 3-year follow-up after implantation of the toric Artisan iris-fixated PIOL in **A)** myopic (n=28) and **B)** hyperopic eyes (n=12). Horizontal lines indicate medians and 1st and 3rd quartiles, while vertical extensions indicate minimum/maximum values.

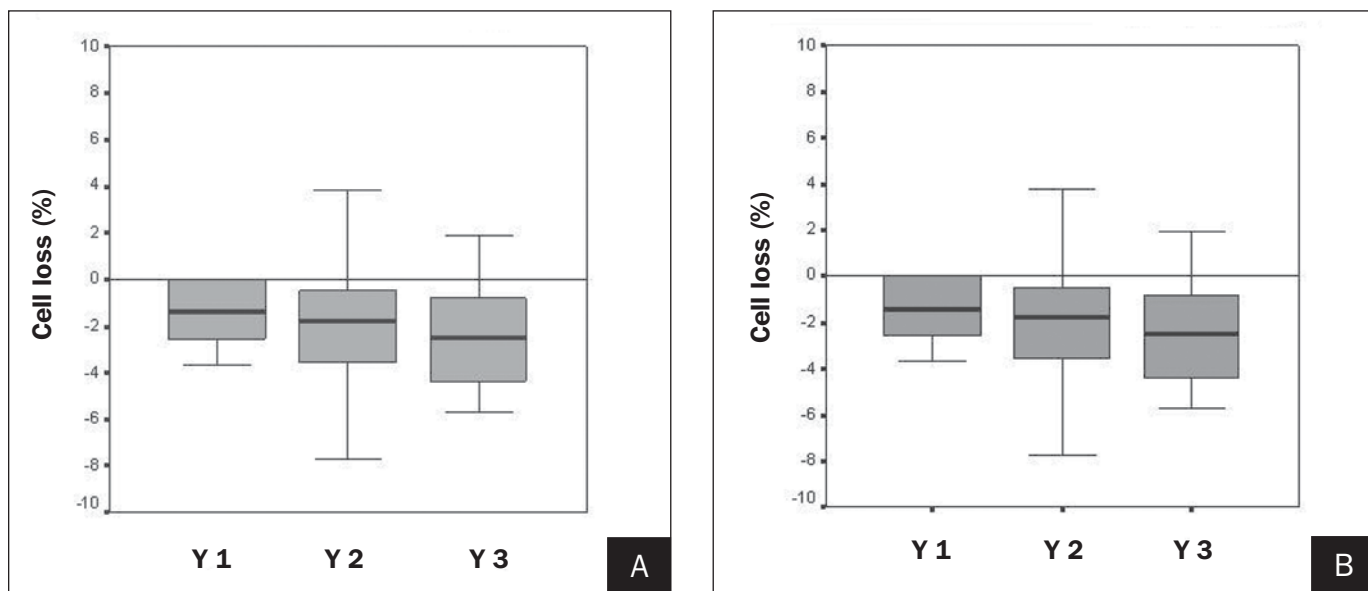


Figure 2. Relative change in mean intraindividual endothelial cell count for **A)** myopic (n=28) and **B)** hyperopic (n=12) eyes. Box plots represent 1st and 3rd quartiles.

or Nujits et al¹⁷ but higher than physiological annual cell loss. In longitudinal studies, average physiological annual endothelial cell loss rate in normal eyes is reported to be approximately 0.3% to 0.6%. Bourne et al¹⁸ found a mean cell loss of $0.6 \pm 0.5\%$ per year over a 10-year period. Higher rates of chronic endothelial cell loss occur after anterior segment intraocular surgery such as cataract surgery (approximately 2.5% per year from 1 to 10 years after surgery) or penetrating keratoplasty (approximately 7.8% per year from 3 to 5 years after surgery).

Intraoperative endothelial cell loss could occur in

hyperopic eyes, particularly those with a shallow anterior chamber. Extensive eye rubbing and PIOL dislocation due to insufficient iris enclavation may also cause endothelial cell loss.⁸ Thus, strict patient selection, extensive surgical training, patient education (eg, instructing patients not to rub the eye excessively after surgery), and diligent follow-up are crucial factors in decreasing the risk of progressive endothelial cell loss.

The results of our study emphasize the importance of excluding eyes with a central anterior chamber depth <3.0 mm and a preoperative endothelial cell

count <1800 cells/mm². All patients in this study were strongly encouraged to return annually for an endothelial cell count analysis. Meticulous follow-up is important, especially with eyes having low baseline cell counts.

REFERENCES

- Dick HB, Alio J, Bianchetti M, Budo C, Christiaans BJ, El-Danassoury MA, Guell JL, Krumeich J, Landesz M, Loureiro F, Luyten GP, Marinho A, Rahhal MS, Schwenn O, Spirig R, Thomann U, Venter J. Toric phakic intraocular lens: European multicenter study. *Ophthalmology*. 2003;110:150-162.
- Landesz M, van Rij G, Luyten G. Iris-claw phakic intraocular lens for high myopia. *J Refract Surg*. 2001;17:634-640.
- Landesz M, Worst JG, van Rij G. Long-term results of correction of high myopia with an iris claw phakic intraocular lens. *J Refract Surg*. 2000;16:310-316.
- Perez-Santonja JJ, Bueno JL, Zato MA. Surgical correction of high myopia in phakic eyes with Worst-Fechner myopia intraocular lenses. *J Refract Surg*. 1997;13:268-281.
- Budo C, Hessloehl JC, Izak M, Luyten GP, Menezo JL, Sener BA, Tassignon MJ, Termote H, Worst JG. Multicenter study of the Artisan phakic intraocular lens. *J Cataract Refract Surg*. 2000;26:1163-1171.
- Alio JL. Advances in phakic intraocular lenses: indications, efficacy, safety, and new designs. *Curr Opin Ophthalmol*. 2004;15:350-357.
- Guell JL, Velasco F. Phakic intraocular lens implantation. *Int Ophthalmol Clin*. 2002;42:119-130.
- Dick HB, Tehrani M. Phakic intraocular lenses. Current status and limitations [German]. *Ophthalmologe*. 2004;101:232-245.
- Alio JL, Mulet ME, Shalaby AM. Artisan phakic iris claw intraocular lens for high primary and secondary hyperopia. *J Refract Surg*. 2002;18:697-707.
- Alio JL, Mulet ME, Gutierrez R, Galal A. Artisan toric phakic intraocular lens for correction of astigmatism. *J Refract Surg*. 2005;21:324-331.
- Guell JL, Vazquez M, Malecaze F, Manero F, Gris O, Velasco F, Hulin H, Pujol J. Artisan toric phakic intraocular lens for the correction of high astigmatism. *Am J Ophthalmol*. 2003;136:442-447.
- Alio JL, Galal A, Mulet ME. Surgical correction of high degrees of astigmatism with a phakic toric-iris claw intraocular lens. *Int Ophthalmol Clin*. 2003;43:171-181.
- Perez-Santonja JJ, Iradier MT, Sanz-Iglesias L, Serrano JM, Zato MA. Endothelial changes in phakic eyes with anterior chamber intraocular lenses to correct high myopia. *J Cataract Refract Surg*. 1996;22:1017-1022.
- Menezo JL, Cisneros AL, Rodriguez-Salvador V. Endothelial study of iris-claw phakic lens: four year follow-up. *J Cataract Refract Surg*. 1998;24:1039-1049.
- Pop M, Payette Y. Initial results of endothelial cell counts after Artisan lens for phakic eyes: an evaluation of the United States Food and Drug Administration Ophtec Study. *Ophthalmology*. 2004;111:309-317.
- Benedetti S, Casamenti V, Marcaccio L, Brogioni C, Assetto V. Correction of myopia of 7 to 24 diopters with the Artisan phakic intraocular lens: two-year follow-up. *J Refract Surg*. 2005;21:116-126.
- Nuijts RM, Abhilakh Missier KA, Nabar VA, Japing WJ. Artisan toric lens implantation for correction of postkeratoplasty astigmatism. *Ophthalmology*. 2004;111:1086-1094.
- Bourne WM, Nelson LR, Hodge DO. Central corneal endothelial cell changes over a ten-year period. *Invest Ophthalmol Vis Sci*. 1997;38:779-782.