

# Artisan iris-fixated toric phakic and aphakic intraocular lens implantation for the correction of astigmatic refractive error after radial keratotomy

Nayyirih G. Tahzib, MD, Fred A.G.J. Eggink, PhD, Monica T.P. Odenthal, MD, Rudy M.M.A. Nuijts, MD, PhD

We report 2 patients who had radial keratotomy (RK) to correct myopia. The first patient developed a postoperative hyperopic shift and cataract. Nine years post RK, she had intracapsular cataract extraction and implantation of an Artisan aphakic intraocular lens (IOL). Twenty years post RK, hyperopia and astigmatism progressed to  $+7.0 -5.75 \times 100$  with a best corrected visual acuity (BCVA) of 20/20. Due to contact lens intolerance, the Artisan aphakic IOL was exchanged for an Artisan toric aphakic IOL. Three months later, the BCVA was 20/20 with  $+1.0 -0.50 \times 130$ . The second patient demonstrated residual myopic astigmatism 6 years after bilateral RK and had become contact-lens intolerant. An Artisan toric phakic IOL was implanted in both eyes. Four months later, the BCVA was 20/25 with a refraction of  $+0.25 -1.0 \times 135$  and 20/20 with a refraction of  $-1.0 \times 40$ . Both patients were satisfied with the visual outcomes.

*J Cataract Refract Surg* 2007; 33:531–535 © 2007 ASCRS and ESCRS

Before the introduction of excimer laser technology, radial keratotomy (RK) was the most commonly performed refractive surgical procedure to correct myopia. The development of a hyperopic shift and diurnal fluctuations in visual acuity are common and troublesome side effects after this refractive surgery procedure.<sup>1–4</sup> The development of high astigmatism is a less common side effect.<sup>1,5</sup>

Implantation of an Artisan toric phakic or aphakic intraocular lens (IOL) (Ophtec BV) is another option to correct astigmatic error, allowing spherical and cylindrical correction in a single procedure.<sup>6–9</sup> The Artisan IOL is made of poly(methyl methacrylate) and has a convex–concave optic with a spherical anterior surface and a spherocylindrical posterior surface

with a 5.0 mm optical zone. The aphakic model is also available with a convex–convex optic configuration. In recent studies of Artisan toric IOL implantation in phakic eyes, 63% to 73% of eyes were within  $\pm 0.50$  diopters (D) of the predicted correction, with a best corrected visual acuity (BCVA) improvement in 65.7% to 70% of eyes.<sup>6–8</sup>

We present 2 patients. One had progressive hyperopia and astigmatism after RK for the correction of moderate myopia followed by intracapsular cataract extraction with implantation of an Artisan aphakic IOL. The other patient presented with bilateral residual myopia after a bilateral RK procedure. Artisan toric aphakic or phakic IOLs were implanted in both patients with satisfactory refractive outcomes.

In both patients, IOL power calculations were performed by Ophtec BV. The axis of the cylinder identified by the subjective refraction was used to determine the axis of surgical enclavation. Toric IOLs are available with the cylinder in line with the haptics or at an angle of 90 degrees with the haptics.<sup>8</sup> An IOL with the cylinder in line with the haptics is recommended when the preoperative cylinder is between 0 degree and 45 degrees or between 135 degrees and 180 degrees. The Artisan toric phakic IOL (pIOL) is available in cylindrical powers up to  $+7.0$  D and the Artisan toric aphakic IOL, in cylindrical powers up to

Accepted for publication October 30, 2006.

From the Department of Ophthalmology (Tahzib, Eggink, Nuijts), Academic Hospital Maastricht, and the Department of Ophthalmology (Odenthal), the Diaconessenhuis, Leiden, The Netherlands.

No author has a financial or proprietary interest in any material or method mentioned.

Corresponding author: Nayyirih G. Tahzib, MD, Department of Ophthalmology, Academic Hospital Maastricht, P. Debyealaan 25, 6202 AZ, Maastricht, The Netherlands. E-mail: nta@soog.azm.nl.

+4.0 D. These IOLs are custom- and patient-designed. The IOL power was calculated to achieve emmetropia. The enclavation sites were marked on the limbus with a marker before surgical implantation, with the patient sitting upright.

## CASE REPORTS

### Case 1

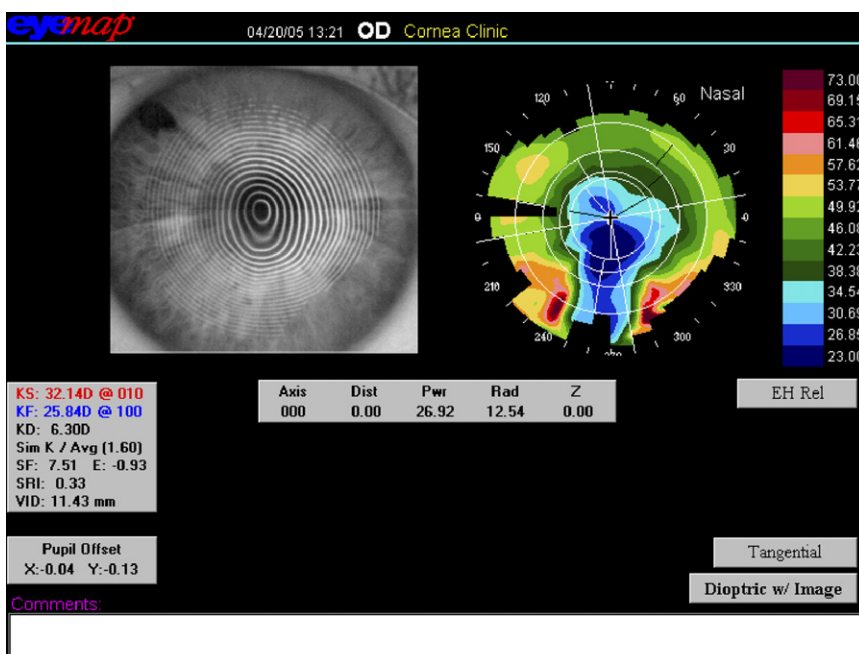
A 74-year-old woman was referred to our clinic because of progressive visual complaints in the right eye. Twenty years earlier, she had had bilateral uneventful RK to correct moderate myopia of  $-5.0$  D in both eyes. The procedure included 8 RK incisions in the right eye, which demonstrated a progressive hyperopic shift postoperatively. Nine years after the RK procedure, uneventful intracapsular cataract extraction with subsequent implantation of an Artisan aphakic IOL (power 23.0 D) was performed in the right eye. After this procedure, the BCVA was 20/25 with  $+3.0 -4.0 \times 120$ .

Twenty years after the RK procedure, the preoperative BCVA in the right eye was 20/20 with a refraction of  $+7.0 -5.75 \times 100$ . Topographic keratometry (EyeMap EH-290, Alcon) was  $32.1 @ 10/25.8 @ 100$  (Figure 1). The endothelial cell density (ECD) was  $1633 \text{ cells/mm}^2$  (Noncon ROBO Pachy SP-9000, Konan Medical, Inc.). The anterior chamber depth (ACD) was 3.45 mm (Visante OCT, Carl Zeiss AG) and the axial length, 26.04 mm. The intraocular pressure (IOP) was 13 mm Hg.

Intraocular lens power calculations were performed (Haigis formula) using the topographically derived keratometric (K)1 (32.1 D) and K2 (25.8 D) meridians and the axial length. This resulted in IOL powers of 24.6 D (K1) and 30.5 D (K2) for emmetropia. In addition, the patient's residual refractive error in the eye with the Artisan aphakic IOL was taken into account in selecting the necessary IOL power. Because the maximum cylindrical power is +4.0 D, an IOL with a power of  $+24.0 +4.0 \times 0$  was custom made to be implanted in the 10-degree axis. Based on this (suboptimal) calculation for emmetropia, the residual refraction was estimated as  $+3.0 -2.5 \times 100$ , suitable for spectacle correction.

The Artisan aphakic IOL was exchanged for an Artisan toric aphakic IOL through a 5.3 mm corneoscleral incision. After rotation, the IOL was fixated in the 10-degree axis with the use of a disposable enclavation needle (Ophtec BV). The wound was sutured with 4 interrupted 10-0 nylon sutures. The postoperative medical regimen consisted of topical tobramycin 0.3% combined with dexamethasone 0.1% (TobraDex) and ketorolac trometamol 0.5% (Acular) 4 times daily for 3 weeks in a tapered regimen and 3 times daily for 1 week, respectively.

Ten months after the IOL exchange, the patient's visual complaints had disappeared. The BCVA was 20/20 with a refraction of  $+1.00 -1.00 \times 120$ . Topographic keratometry was  $34.0 @ 20/26.9 @ 110$ . The ECD was  $1383 \text{ cells/mm}^2$ , and endothelial cell loss of the preoperative ECD was 15.3%. The IOP was



**Figure 1.** (Case 1) Corneal topography image before implantation of an Artisan toric aphakic IOL demonstrates the large variability (approximately 23 to 38 D) in corneal powers in the 3.0 mm zone.

12 mm Hg. Slitlamp examination showed a clear and centered IOL (Figure 2).

## Case 2

A 43-year-old woman visited our clinic in April 2005 with bilateral visual complaints. In 1995, she had had a bilateral RK procedure for the correction of high myopia in both eyes. The pre-RK refraction was  $-10.5 -2.0 \times 142$  in the right eye and  $-11.25 -2.0 \times 1$  in the left eye. The procedure included 12 RK incisions in both eyes. Ten years postoperatively, the refraction was  $-6.0 -3.5 \times 135$  in the right eye and  $-6.0 -3.0 \times 45$  in the left eye. Due to the patient's contact-lens intolerance, bilateral implantation of an Artisan toric pIOL was scheduled to correct the residual myopia and astigmatism.

Preoperatively, the BCVA was 20/30 with a refraction of  $-6.0 -3.5 \times 130$  in the right eye and 20/30 with a refraction of  $-6.5 -3.0 \times 40$  in the left eye. Topographic keratometry was 40.0 @ 50/37.4 @ 140 and 39.7 @ 120/37.4 @ 30, respectively (Figure 3). The ECD was 2117 cells/mm<sup>2</sup> and 1971 cells/mm<sup>2</sup>, respectively, and the ACD, 3.28 mm and 3.25 mm, respectively. The IOP was 14 mm Hg in both eyes.

Intraocular lens power calculations for postoperative emmetropia were performed using the corneal curvature, adjusted ACD, and manifest spherical equivalent of the patient's subjective refractive error (van der Heijde formula). This resulted in an IOL power of  $-6.47 -3.23 \times 130$  for the right eye and  $-6.93 -2.75 \times 40$  for the left eye. As a result of the preference for positioning an Artisan IOL horizontally or at an oblique angle, an IOL with a dioptric power of  $-6.5 -3.0 \times 90$  was fixated in the 40-degree axis in

the right eye and an IOL with a dioptric power of  $-7.0 -2.5 \times 0$  was fixated in the 40-degree axis in the left eye.

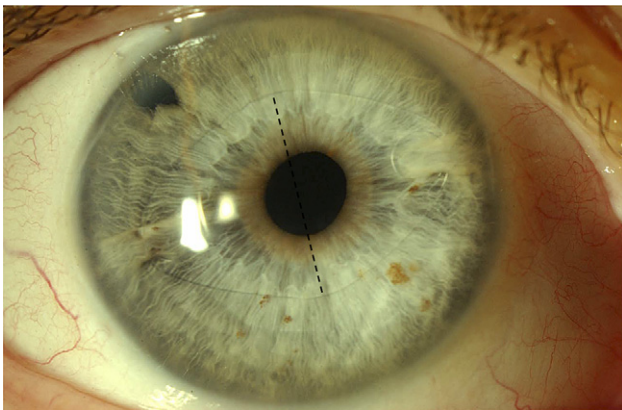
An Artisan toric pIOL was implanted in the right eye and then 2 weeks later, in the left eye. The surgical technique and postoperative medications were the same as in the first case. Four months after implantation, the patient reported the visual complaints had disappeared and she was very satisfied. The uncorrected visual acuity was 20/25 in the right eye and 20/30 in the left eye. The BCVA was 20/25 with a refraction of  $+0.25 -1.0 \times 135$  and 20/20 with a refraction of  $-1.0 \times 40$ , respectively. Topographic keratometry was 40.6 @ 57/37.4 @ 147 in the right eye and 39.4 @ 130/37.1 @ 40 in the left eye. The ECDs were 2120 cells/mm<sup>2</sup> and 1946 cells/mm<sup>2</sup>, respectively. Endothelial cell loss compared with the preoperative ECD was  $-0.14\%$  and  $1.27\%$  for the right and left eye, respectively. The IOP was 16 mm Hg in both eyes. Slitlamp examination showed clear and centered IOLs (Figure 4).

## DISCUSSION

Although RK procedures initially achieve satisfactory refractive outcomes, side effects are known to occur. Clinical studies show that the development of a hyperopic shift after RK occurs with a frequency of 17% to 43%, with an additional incidence of 1% to 2% each year.<sup>1,3,4,10-14</sup> This is due to the long-term instability of the refraction, which is related to the ongoing effect of the procedure and possible insufficient corneal stability.<sup>10,15</sup> The development of irregular astigmatism after RK can be induced by the intersection of the incisions with the visual axis or by the eccentricity of the optical zone.<sup>5</sup>

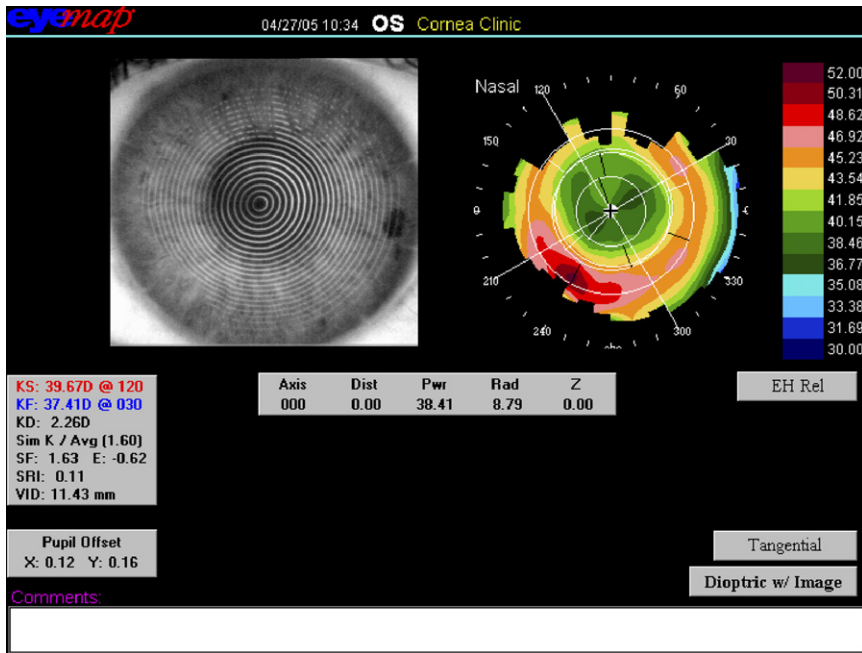
We cannot explain why the topographical K-values for calculation of the IOL powers led to such a favorable outcome in the first case. One explanation could be that among the variable corneal powers in the 3.0 mm zone (Figure 1), the selected K-value was by chance the most appropriate one. In the second case, the K-values probably regressed toward the corneal curvature parameters prior to the RK since it is unlikely that the K-values after RK (mean value 38.7 D and 38.6 D, right and left eye) were comparable to the pre-RK refractions of  $-11.5$  D and  $-12.50$  D in the right and left eyes, respectively. Following this hypothesis, the topographically measured error might have been smaller.

Various techniques can be used to treat a residual refractive error following RK. Myopic astigmatism can be corrected by a contact lens, but this may be complicated by contact-lens intolerance.<sup>16</sup> The lasso-string suture acts as an immediate solution for symptomatic



**Figure 2.** (Case 1) A slitlamp photograph taken 1 month after implantation of an Artisan toric aphakic IOL for the correction of progressive hyperopia and astigmatism after cataract surgery in an eye that had been treated with RK. The IOL was enclavated along the 10-degree axis (perforated line marks the 90-degree meridian axis of the toric IOL).



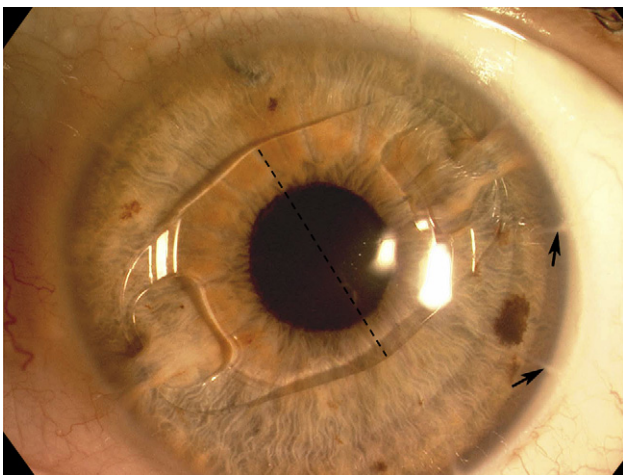


**Figure 3.** (Case 2, left eye) Corneal topography image before Artisan toric pIOL implantation for the correction of residual myopia in an eye that had been treated with 12 RK incisions. The image shows a well-centered optical zone and regular astigmatism.

overcorrected hyperopic eyes after RK but seems to have a diminishing effect over time.<sup>17,18</sup> Photorefractive keratectomy and laser in situ keratomileusis did not appear to be reasonable options in our 2 cases because of the magnitude of the refractive error and the possible consequences of the development of haze and flap complications.<sup>19–23</sup> Clear lens extraction could be considered in the second case but would not sufficiently treat the astigmatism; it also has a higher risk for postoperative retinal detachment.<sup>24,25</sup> Implantation of a (phakic) toric posterior chamber IOL might

have been a suitable option in the second case.<sup>26,27</sup> Since the spectacle BCVA after RK was  $\geq 20/25$  in both eyes, indicating no significant visual loss from irregular astigmatism, penetrating keratoplasty (PKP) was not a viable option. The implantation of toric iris-fixated IOLs in eyes without prior surgery and post-PKP eyes appears to be a safe and predictable method for correcting high levels of astigmatism, with 63% to 73% of treated eyes within  $\pm 0.50$  D of the predicted correction and a BCVA improvement in 65.7% to 70% of eyes.<sup>7–9,28</sup> To our knowledge, implantation of an Artisan toric IOL in RK eyes has not been described and therefore the long-term visual stability and safety data are unknown. During the procedure, we aimed to avoid wound dehiscence of the RK incisions by making a corneoscleral tunnel 1.5 mm from the limbus.

The amount of endothelial cell loss after Artisan IOL implantation in phakic eyes has been shown to vary and can be as high as 12%.<sup>29–32</sup> However, studies of endothelial cell loss in eyes that had Artisan toric IOL implantation after PKP show a loss close to 30% after 24 months, which suggests that corneal grafts are more susceptible to endothelial cell loss. As far as we know, there are no data in the literature about the long-term effects of the Artisan aphakic IOL on the corneal endothelium.<sup>9,33</sup> Our first case of implantation of the Artisan toric IOL in an aphakic eye demonstrated an endothelial cell loss close to 14%. We believe this is an acceptable loss in this patient considering the limited treatment options and the significant visual complaints. The second case of implantation of Artisan toric IOLs in phakic eyes showed a low endothelial cell



**Figure 4.** (Case 2, left eye) Slitlamp photograph taken 4 months after implantation of an Artisan toric pIOL for the correction of residual myopia in an eye that had been treated with RK (arrows indicate RK incisions). The pIOL was enclavated along the 40-degree axis (perforated line marks the 90-degree meridian axis of the toric pIOL).

loss of  $-0.14\%$  and  $1.27\%$  in the right and left eyes, which agrees with the cell loss in previous reports.

In summary, our first case was successfully treated by implantation of an Artisan toric aphakic IOL and the second case had a similar satisfactory outcome after the implantation of an Artisan toric pIOL. In RK eyes, the removal option can be an important advantage of the Artisan IOL, especially when dealing with potentially progressive refractive error changes after corneal refractive surgery.

## REFERENCES

1. Waring GO III, Lynn MJ, McDonnell PJ. Results of the Prospective Evaluation of Radial Keratotomy (PERK) Study 10 years after surgery; the PERK Study Group. *Arch Ophthalmol* 1994; 112:1298–1308
2. Kemp JR, Martinez CE, Klyce SD, et al. Diurnal fluctuations in corneal topography 10 years after radial keratotomy in the Prospective Evaluation of Radial Keratotomy Study. *J Cataract Refract Surg* 1999; 25:904–910
3. Deitz MR, Sanders DR, Raanan MG, DeLuca M. Long-term (5- to 12-year) follow-up of metal-blade radial keratotomy procedures. *Arch Ophthalmol* 1994; 112:614–620
4. Salz JJ, Salz JM, Salz M, Jones D. Ten years experience with a conservative approach to radial keratotomy. *Refract Corneal Surg* 1991; 7:12–22
5. McDonnell PJ, Caroline PJ, Salz J. Irregular astigmatism after radial and astigmatic keratotomy. *Am J Ophthalmol* 1989; 107:42–46
6. Alió JL, Mulet ME, Gutiérrez R, Galal A. Artisan toric phakic intraocular lens for correction of astigmatism. *J Refract Surg* 2005; 21:324–331
7. Güell JL, Vazquez M, Malecaze F, et al. Artisan toric phakic intraocular lens for the correction of high astigmatism. *Am J Ophthalmol* 2003; 136:442–447
8. Dick HB, Alio J, Bianchetti M, et al. Toric phakic intraocular lens: European multicenter study. *Ophthalmology* 2003; 110:150–162
9. Tahzib NG, Cheng YYY, Nuijts RMMA. Three-year follow-up analysis of Artisan toric lens implantation for correction of post-keratoplasty ametropia in phakic and pseudophakic eyes. *Ophthalmology* 2006; 113:976–984
10. Gimbel H, Sun R, Kaye GB. Refractive error in cataract surgery after previous refractive surgery. *J Cataract Refract Surg* 2000; 26:142–144
11. Koch DD, Liu JF, Hyde LL, et al. Refractive complications of cataract surgery after radial keratotomy. *Am J Ophthalmol* 1989; 108:676–682
12. Lyle WA, Jin GJC. Intraocular lens power prediction in patients who undergo cataract surgery following previous radial keratotomy. *Arch Ophthalmol* 1997; 115:457–461
13. Packer M, Brown LK, Hoffman RS, Fine IH. Intraocular lens power calculation after incisional and thermal keratorefractive surgery. *J Cataract Refract Surg* 2004; 30:1430–1434
14. Seitz B, Langenbucher A. Intraocular lens power calculation in eyes after corneal refractive surgery. *J Refract Surg* 2000; 16:349–361
15. Hjortdal JØ, Böhm A, Kohlhaas M, et al. Mechanical stability of the cornea after radial keratotomy and photorefractive keratectomy. *J Refract Surg* 1996; 12:459–466
16. Alió JL, Belda JI, Artola A, et al. Contact lens fitting to correct irregular astigmatism after corneal refractive surgery. *J Cataract Refract Surg* 2002; 28:1750–1757
17. Miyashiro MJ, Yee RW, Patel G, et al. Lasso procedure to revise overcorrection with radial keratotomy. *Am J Ophthalmol* 1998; 126:825–827
18. Damiano RE, Forstot SL, Frank CJ, Kasen WB. Purse-string sutures for hyperopia following radial keratotomy. *J Refract Surg* 1998; 14:408–413
19. Lyle WA, Jin GJC. Laser in situ keratomileusis for consecutive hyperopia after myopic LASIK and radial keratotomy. *J Cataract Refract Surg* 2003; 29:879–888
20. Lipshitz I, Man O, Shemesh G, et al. Laser in situ keratomileusis to correct hyperopic shift after radial keratotomy. *J Cataract Refract Surg* 2001; 27:273–276
21. Shah SB, Lingua RW, Kim CH, Peters NT. Laser in situ keratomileusis to correct residual myopia and astigmatism after radial keratotomy. *J Cataract Refract Surg* 2000; 26:1152–1157
22. Azar DT, Tuli S, Benson RA, Hardten DR. Photorefractive keratectomy for residual myopia after radial keratotomy; the PRK After RK Study Group. *J Cataract Refract Surg* 1998; 24:303–311
23. Francesconi CM, Nosé RAM, Nosé W. Hyperopic laser-assisted in situ keratomileusis for radial keratotomy-induced hyperopia. *Ophthalmology* 2002; 109:602–605
24. Muraine M, Siahmed K, Retout A, Brasseur G. Phacoémulsification après kératectomie radiaire; analyse topographique et réfractive sur une période de 18 mois (à propos d'un cas). *J Fr Ophtalmol* 2000; 23:265–269
25. Colin J, Robinet A, Cochener B. Retinal detachment after clear lens extraction for high myopia; seven-year follow-up. *Ophthalmology* 1999; 106:2281–2284; discussion by M Stirpe, 2285
26. Pineda-Fernández A, Jaramillo J, Vargas J, et al. Phakic posterior chamber intraocular lens for high myopia. *J Cataract Refract Surg* 2004; 30:2277–2283
27. Sanders DR, Brown DC, Martin RG, et al. Implantable contact lens for moderate to high myopia: phase 1 FDA clinical study with 6 month follow-up. *J Cataract Refract Surg* 1998; 24:607–611
28. Tehrani M, Dick HB. Iris-fixated toric phakic intraocular lens: three-year follow-up. *J Cataract Refract Surg* 2006; 32:1301–1306
29. Pop M, Payette Y. Initial results of endothelial cell counts after Artisan lens for phakic eyes; an evaluation of the United States Food and Drug Administration Ophtec Study. *Ophthalmology* 2004; 111:309–317
30. Budo C, Hessloehl JC, Izak M, et al. Multicenter study of the Artisan phakic intraocular lens. *J Cataract Refract Surg* 2000; 26:1163–1171
31. Menezo JL, Cisneros AL, Rodriguez-Salvador V. Endothelial study of iris-claw phakic lens: four year follow-up. *J Cataract Refract Surg* 1998; 24:1039–1049
32. Budo C, Bartels MC, van Rij G. Implantation of Artisan toric phakic intraocular lenses for the correction of astigmatism and spherical errors in patients with keratoconus. *J Refract Surg* 2005; 21:218–222
33. Kanellopoulos AJ. Penetrating keratoplasty and Artisan iris-fixated intraocular lens implantation in the management of aphakic bullous keratopathy. *Cornea* 2004; 23:220–224