

4. Lee JB, Kim JS, Choe C, Seong GJ, Kim EK. Comparison of two procedures: photorefractive keratectomy versus laser in situ keratomileusis for low to moderate myopia. *Jpn J Ophthalmol.* 2001;45:487-491.
5. Comaish IF, Lawless MA. Progressive post-LASIK keratectasia: biomechanical instability or chronic disease process? *J Cataract Refract Surg.* 2002;28:2206-2213.
6. Seiler T, Quurke AW. Iatrogenic keratectasia after LASIK in a case of forme fruste keratoconus. *J Cataract Refract Surg.* 1998;24:1007-1009.
7. Argento C, Cosentino MJ, Tytiun A, Rapetti G, Zarate J. Corneal ectasia after laser in situ keratomileusis. *J Cataract Refract Surg.* 2001;27:1440-1448.
8. Ou RJ, Shaw EL, Glasgow BJ. Keratectasia after laser in situ keratomileusis (LASIK): evaluation of the calculated residual stromal bed thickness. *Am J Ophthalmol.* 2002;134:771-773.
9. Amoils SP, Deist MB, Gous P, Amoils PM. Iatrogenic keratectasia after laser in situ keratomileusis for less than -4.0 to -7.0 diopters of myopia. *J Cataract Refract Surg.* 2000;26:967-977.
10. Rao SK, Srinivasan B, Sitalakshmi G, Padmanabhan P. Photorefractive keratectomy versus laser in situ keratomileusis to prevent keratectasia after corneal ablation. *J Cataract Refract Surg.* 2004;30:2623-2628.

## Artisan Phakic Intraocular Lens Implantation After Retinal Detachment Surgery

J.K. Chung, MD; Jae Bum Lee, MD; Sung Jin Lee, MD

### ABSTRACT

**PURPOSE:** To report three cases of Artisan phakic intraocular lens (PIOL) implantation to correct myopic refractive error after previous retinal detachment surgery treated with scleral encircling.

**METHODS:** Artisan PIOLs were implanted in a 29-year-old man with  $-21.0 -2.0 \times 180$  manifest refraction and best spectacle-corrected visual acuity (BSCVA) of 20/40 (case 1), a 28-year-old woman with BSCVA of 20/20 and  $-8.5 -1.0 \times 180$  manifest refraction (case 2), and a 44-year-old man with BSCVA of 20/32 and  $-11.75 -1.75 \times 10$  manifest refraction (case 3).

*From the Department of Ophthalmology, Soonchunhyang University Hospital, Seoul, Korea (Chung, SJ Lee); and Bundang Yonsei Plus Eye Clinic, Sungnam, Korea (JB Lee).*

*The authors have no proprietary interest in the materials presented herein.*

*Correspondence: Sung Jin Lee, MD, Dept of Ophthalmology, Soonchunhyang University Hospital, #657 Hannam-dong Youngsangu, Seoul 140-743, Korea. Tel: 82 2 709 9357; Fax: 82 2 798 7797; E-mail: wismile@unitel.co.kr*

*Received: November 7, 2005*

*Accepted: May 9, 2006*

*Posted online: June 9, 2006*

**RESULTS:** In case 1, 24 months after implantation of the Artisan PIOL, uncorrected visual acuity (UCVA) was 20/40. In case 2, 24 months after surgery, UCVA was 20/32. In case 3, 3 months after surgery, UCVA was 20/32. There was no formation of new breaks, progressive vitreoretinal traction, or complications.

**CONCLUSIONS:** The Artisan PIOL may provide an alternative method to correct high myopia after retinal detachment surgery. [*J Refract Surg.* 2006;22:820-823.]

Multiple refractive surgical techniques are available for correcting myopia, offering freedom from the use of spectacles and contact lenses. Current refractive surgery includes intraocular procedures that alter corneal refractive power. Laser in situ keratomileusis (LASIK) and photorefractive keratectomy have gained wide acceptance as the procedure of choice for correction of low and moderate myopia. However, laser-assisted refractive surgery for the correction of high myopia remains problematic. Present limitations are related to corneal thickness and degree of myopic refractive error in keratomileusis. Complications such as glare, halo, and corneal ectasia are common with difficulty ensuring accurate correction.<sup>1,2</sup>

Myopic refractive errors are common in patients who develop retinal detachment.<sup>3,4</sup> In addition, myopic changes may also be induced with a scleral buckling procedure because of the changes in axial length, anterior chamber depth, and position of the crystalline lens.<sup>5,6</sup> Therefore, many patients who previously underwent retinal detachment surgery request refractive surgery for correction of myopia. Although there are reports of LASIK after retinal detachment surgery in the literature, this report describes Artisan myopic phakic intraocular lens (PIOL) (OPHTEC BV, Groningen, The Netherlands) implantation results.

### PATIENTS AND METHODS

Three eyes of three patients with myopic refractive error were studied. All patients underwent conventional encircling procedure for primary rhegmatogenous retinal detachment and requested to be spectacle- or contact lens-independent. Written informed consent was obtained from each patient.

Preoperative data included age, sex, ocular history, type of previous ocular surgery, and time elapsed between retinal detachment surgery and Artisan lens implantation. Preoperative evaluation of the enrolled eye included manifest and cycloplegic refraction, complete eye examination, uncorrected and best spectacle-corrected visual acuity (UCVA and BSCVA, respectively) in both eyes, keratometric power, ul-

trasonographic A-scan to measure anterior chamber depth, and endothelial cell count. Postoperative examinations were scheduled at 1 day, 1 week, and 1, 3, 6, 12, and 24 months after surgery. Each postoperative examination included UCVA, BSCVA, manifest refraction, slit-lamp examination results, fundus examination findings, endothelial cell count, subjective complaints, and complaints or adverse reactions that occurred. All pre- and postoperative examinations were performed by the same person.

A single laser iridotomy was performed on the peripheral iris at the 1 or 11 o'clock position prior to PIOL implantation, and the pupil was constricted pharmacologically 2 hours before. Surgery was performed under topical anesthesia with 2% lidocaine. Two vertical paracentesis were performed for iris enclavation. Corneal incision was approximately equal to the lens optic diameter. The lens was then completely introduced in one step under an ophthalmic viscosurgical device (Healon G.V.; Advanced Medical Optics, Santa Ana, Calif) to avoid contact of the front part of the intraocular lens with the crystalline lens. The lens was rotated 90° so that the axis lay perpendicular to the direction of insertion. After grasping the optic of the lens with Budo forceps (Duckworth and Kent Ltd, Baldock Herts, England), a small knuckle of iris tissue was drawn through the pincer of each haptic with an enclavation needle (Artisan, OPHTEC BV). The viscosurgical device was removed and the wound closed with a suture. The diopter of the lens was calculated with the patient's refractive error, anterior chamber depth, and keratometric values (van der Heijde formula).

**CASE REPORTS**

**CASE 1**

A 29-year-old man presented with previous rhegmatogenous retinal detachment in the left eye treated with scleral encircling and cryotherapy 10 years before with complete reattachment. On preoperative examination, UCVA in the left eye was counting fingers at 3 feet and BSCVA was 20/40 with  $-21.0 -2.0 \times 180$  manifest refraction. Anterior chamber depth in the left eye was 3.490 mm, endothelial cell density was 2752 cells/mm<sup>2</sup>, and central corneal thickness was 513 μm (Table).

There were no intra- and postoperative complications. Uncorrected visual acuity stabilized at 1 month, and manifest refraction was  $-0.75 -1.0 \times 165$  with BSCVA of 20/32 and UCVA of 20/40. Twelve months after surgery, manifest refraction was  $-0.75 -0.5 \times 160$ , BSCVA was 20/32, and UCVA was 20/40. Twenty-four months after surgery, refractive error was  $-0.75 -0.5 \times 170$ , BSCVA was 20/32, and UCVA was 20/40 (Fig). There were no

TABLE

**Characteristics of Patients Who Underwent Artisan PIOL Implantation After Retinal Detachment Surgery**

	Case 1	Case 2	Case 3
Age (y)	29	28	44
Sex	Male	Female	Male
UCVA	CF 3 feet	CF 4 feet	NA
BSCVA	20/40	20/20	20/32
Refractive error (spherical equivalent, D)	-22.0	-9.0	-10.875
Axial length (mm)	33.01	26.71	26.78
Endothelial cell count (cell/mm <sup>2</sup> )	2752	2846	NA
Corneal refraction (D)	41.75/45	43.25/45.25	45.5/47.25
Anterior chamber depth (mm)	3.490	3.252	2.550
Central corneal thickness (μm)	513	473	476

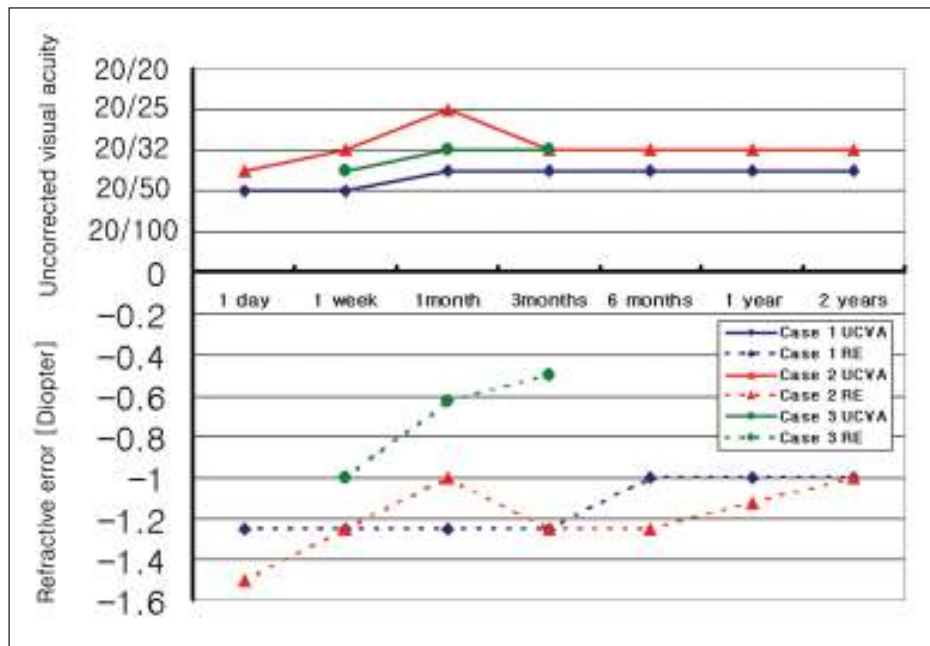
PIOL = phakic intraocular lens, UCVA = uncorrected visual acuity, BSCVA = best spectacle-corrected visual acuity, CF = counting fingers, D = diopter, NA = not available

undetected breaks, formation of new breaks, or progressive vitreoretinal traction on indirect ophthalmoscopic examination.

**CASE 2**

A 28-year-old woman presented with previous retinal detachment in the right eye, which occurred 2 years prior to presentation and was treated with scleral encircling with 4-mm silicone sponge, external subretinal drainage, and argon laser photocoagulation with a laser indirect ophthalmoscope with complete reattachment. The patient also had inferior temporal retinal detachment with two horseshoe tears not affecting the macula. On preoperative examination, UCVA in the right eye was counting fingers at 4 feet and BSCVA was 20/20 with  $-8.5 -1.0 \times 180$  manifest refraction. Anterior chamber depth in the right eye was 3.252 mm, endothelial cell density was 2846 cells/mm<sup>2</sup>, and central corneal thickness was 473 μm (Table).

Manifest refraction at 1 month was plano  $-2.0 \times 70$ , BSCVA was 20/20 and UCVA was 20/25. Three months after surgery, UCVA was decreased at 20/32 and BSCVA was 20/20 with manifest refraction of  $-0.25 -2.0 \times 70$ . Twelve months after surgery, manifest refraction was  $-0.25 -1.75 \times 80$  with BSCVA of 20/20 and UCVA of



**Figure.** Changes in uncorrected visual acuity (UCVA) and spherical equivalent refractive error (RE) (diopters) after Artisan lens implantation.

20/32. Twenty-four months after surgery, refractive error was  $-0.25 -1.50 \times 80$ , BSCVA was 20/20, and UCVA was 20/32 (see Fig). The pre-existing breaks were effectively closed by proper positioning of the scleral buckle with adequate chorioretinal adhesion 2 years after Artisan PIOL implantation. There were no undetected breaks, formation of new breaks, or progressive vitreoretinal traction on indirect ophthalmoscopic examination.

**CASE 3**

The chart was reviewed of a 44-year-old man who received Artisan PIOL implantation at a local private eye clinic. Thirteen years prior to chart review he had retinal detachment in the left eye treated with scleral buckle encircling with complete reattachment. On preoperative examination, BSCVA in the left eye was 20/32 with  $-11.75 -1.75 \times 10$  manifest refraction. Uncorrected visual acuity was not available. Anterior chamber depth in the right eye was 2.550 mm, endothelial cell density was not available, and central corneal thickness was 476  $\mu\text{m}$  (Table). The crystalline lens was clear without sign of cataract.

One week after surgery, manifest refraction was  $-0.25 -2.5 \times 100$ , UCVA was 20/40, and BSCVA was 20/25. One month after surgery, manifest refraction was  $-0.25 -0.75 \times 90$ , BSCVA was 20/25, and UCVA was 20/32. At the patient's last follow-up visit, 3 months after surgery, manifest refraction was  $-0.25 -0.50 \times 80$ , BSCVA was 20/25, and UCVA was 20/32 (see Fig). There were no significant vitreoretinal changes on indirect ophthalmoscopic examination or complication during the 3-month follow-up period.

**DISCUSSION**

Several recent studies demonstrate successful results with Artisan iris-supported PIOLs to correct moderate to high myopia.<sup>7,8</sup> This is an alternative to other types of refractive surgery that involve ablating the corneal stroma. In previous studies, successful correction of myopic refractive error after retinal detachment surgery was reported.<sup>9,10</sup> However, refractive surgery is less predictable at correcting higher levels of myopia and is sometimes not feasible due to inadequate corneal thickness.<sup>1</sup>

In this report, patients had improvement in UCVA without decrease in BSCVA. In two eyes (cases 1 and 3), the measured UCVA was 20/40 and 20/32, respectively, with no change in BSCVA before or after Artisan PIOL implantation. Further, there was no formation of new breaks or progressive vitreoretinal traction during the follow-up period. Postoperative myopic astigmatism remains problematic.

The removal of buckle for any reason (eg, displacement of the buckle, infection, inflammation, and recurrent retinal detachment) may alter the refractive status, which is of concern in patients undergoing LASIK. However, Artisan PIOL implantation is superior to LASIK in this setting because of the reversibility of the procedure as it is exchangeable or removable.<sup>10</sup> Development of corneal ectasia is another concern of performing LASIK after scleral buckling.<sup>1</sup> Sinha et al<sup>9</sup> reported that conjunctival scarring after retinal detachment surgery hampered the function of the suction ring of the microkeratome, which prevented a solid hold on the ocular surface. Visualization of the peripheral

retina was not significantly hindered in these patients as the pupil could be significantly dilated in all cases.

Clear lens extraction is an alternative method to correct myopic errors in highly myopic patients. Using this method increases the risk of retinal detachment and cystoid macular edema and may result in the loss of accommodation. Colin et al<sup>11</sup> reported that the incidence of retinal detachment after clear lens extraction nearly doubled that estimated for patients with myopia  $>-10.0$  diopters who did not undergo surgery, and hence increased with posterior capsule rupture or YAG laser capsulotomy.

A surgeon's concern is whether Artisan lens implantation after retinal detachment surgery increases the chance of recurrent retinal detachment. Although it is unclear that the risk of retinal detachment after PIOL implantation is higher than spontaneously occurring retinal detachment in high myopia, there have been reports of retinal complications, such as detachment or tear after other types of anterior chamber PIOL implantation.<sup>12,13</sup> However, there is only one case report of retinal complication after Artisan lens surgery.<sup>14</sup> van der Meulen et al<sup>15</sup> reported 19 cases of retinal detachment after Artisan lens implantation. The patients had undergone the first eye surgery several months before and the Artisan lens was implanted in aphakic eyes as a second procedure due to capsule rupture, trauma, or subluxation of the IOL. Therefore, the relation between Artisan lens implantation and retinal detachment is still unknown. The authors speculate that a much lower rate of retinal detachment after Artisan PIOL implantation than other types of PIOLs may be related to character of the lens. Artisan lenses differ from other types of PIOLs because they are fixed to the midperipheral portion of the iris, which is its only contact with the iris surface. It does not interfere with normal physiology of the iris or the angle structure.<sup>16</sup> Although there are some differences in surgical procedures, the recurrence rate of retinal detachment after phacoemulsification in eyes that had previous retinal detachment surgery was similar to that of new occurrence of retinal detachment in fellow eyes without retinal detachment before phacoemulsification.<sup>17</sup>

Artisan PIOL implantation should be considered for the treatment of myopic refractive errors after retinal detachment surgery. This is an alternative procedure to LASIK. Additional studies with larger sample size and longer follow-up will be helpful in establishing

safety guidelines and improving efficacy for this procedure.

## REFERENCES

1. Knorz MC, Wiesinger B, Liermann A, Seiberth V, Liesenhoff H. Laser in situ keratomileusis for moderate and high myopia and myopic astigmatism. *Ophthalmology*. 1998;105:932-940.
2. Seiler T, Koufala K, Richter G. Iatrogenic keratectasia after laser in situ keratomileusis. *J Refract Surg*. 1998;14:312-317.
3. Schepens CL, Marden D. Data on the natural history of retinal detachment. Further characterization of certain unilateral non-traumatic cases. *Am J Ophthalmol*. 1966;61:213-226.
4. Risk factors for idiopathic rhegmatogenous retinal detachment. The Eye Disease Case-Control Study Group. *Am J Epidemiol*. 1993;137:749-757.
5. Smiddy WE, Loupe DN, Michels RG, Enger C, Glaser BM, de-Bustros S. Refractive changes after scleral buckling surgery. *Arch Ophthalmol*. 1989;107:1469-1471.
6. Larsen JS, Syrdalen P. Ultrasonographic study on changes in axial eye dimensions after encircling procedure in retinal detachment study. *Acta Ophthalmol (Copenh)*. 1979;57:337-343.
7. Maloney RK, Nguyen LH, John ME. Artisan phakic intraocular lens for myopia: short-term results of a prospective, multicenter study. *Ophthalmology*. 2002;109:1631-1641.
8. Landes M, Worst JG, van Rij G. Long-term results of correction of high myopia with an iris claw phakic intraocular lens. *J Refract Surg*. 2000;16:310-316.
9. Sinha R, Dada T, Verma L, Chaudhury DB, Tandon R, Vajpayee RB. LASIK after retinal detachment surgery. *Br J Ophthalmol*. 2003;87:551-553.
10. Belda JI, Ruiz-Moreno JM, Perez-Santonja JJ, Alio JL. Laser in situ keratomileusis to correct myopia after scleral buckling for retinal detachment. *J Cataract Refract Surg*. 2003;29:1231-1235.
11. Colin J, Robinet A, Cochener B. Retinal detachment after clear lens extraction for high myopia: seven-year follow-up. *Ophthalmology*. 1999;106:2281-2284.
12. Ruiz-Moreno JM, Alio JL, Perez-Santonja JJ, de la Hoz F. Retinal detachment in phakic eyes with anterior chamber intraocular lenses to correct severe myopia. *Am J Ophthalmol*. 1999;127:270-275.
13. Martinez-Castillo V, Boixadera A, Verdugo A, Elies D, Coret A, Garcia-Arumi J. Rhegmatogenous retinal detachment in phakic eyes after posterior chamber phakic intraocular lens implantation for severe myopia. *Ophthalmology*. 2005;112:580-585.
14. Hernaez-Ortega MC, Soto-Pedre E. Giant retinal tear after iris claw phakic intraocular lens. *J Refract Surg*. 2004;20:839-840.
15. van der Meulen I, Gunning F, Henry Y, de Vries-Knoppert W, Gortzak-Moorstein N, de Smet MD. Management of retinal detachments in pseudophakic patients with Artisan lenses. *J Cataract Refract Surg*. 2002;28:1804-1808.
16. Menezes JL, Martinez MC, Cisneros AL. Iris-fixated Worst claw versus sulcus-fixated posterior chamber lenses in the absence of capsular support. *J Cataract Refract Surg*. 1996;22:1476-1484.
17. Igarashi C, Hayashi H, Hayashi K. Phacoemulsification after retinal detachment surgery. *J Cataract Refract Surg*. 2004;30:1412-1417.