

A retrospective analysis of the first Indian experience on Artisan phakic intraocular lens

Sirisha Senthil, MS, FRCS; Kasu Prasad Reddy, MRCOphth; Ravisankar, DO; Srilakshmi, DO

Purpose: To evaluate the efficacy, safety, predictability and stability of implanting a polymethylmethacrylate phakic intraocular lens (PIOL) in high myopia.

Materials and Methods: A retrospective analysis of the data of patients who underwent Artisan phakic IOL implantation between 2002 and 2003 with a follow-up of at least 24 months.

Results: An Artisan myopia lens was implanted in 60 eyes of 36 patients with preoperative myopia ranging from -5.0 to -24.0 D. Mean patient age was 22.6 years. Mean spherical equivalent of manifest refraction stabilized by the first postoperative week. At three months follow-up, 54 eyes (90%) had a postoperative refraction within ± 1 D emmetropia and 45 eyes (75%) had uncorrected visual acuity of 20/40 or better. Seven eyes (11.6%) had loss of one Snellen line and none had loss of two Snellen lines or more at three months. The mean endothelial cell loss was 3.8% at three months, 5.2% at six months, 5.25% at 12 months and 6.38% at two years, which was not significant. Postoperative complications included anterior chamber reaction in two eyes (3.3%), rise in intraocular pressure in six eyes (10%) and dislocation of PIOL in two eyes (3.3%).

Conclusion: Implantation of Artisan myopia lens to correct high myopia resulted in a stable and fairly predictable refractive outcome with few complications. Significant endothelial damage was not detected in two years of follow-up.

Key words: Artisan, phakic intraocular lens, refractive surgery.

Indian J Ophthalmol 2006;54:251-5

Lasik is the most widely performed procedure for correction of myopia.¹ At our center, the rejection rate for lasik stands at 33%, the most common cause being thin cornea. Alternatives to lasik include implantation of a phakic intraocular lens (PIOL) and refractive lens exchange.

Strampelli and Barraquer introduced PIOLs in the 1950s to correct refractive errors.¹⁻³ Artisan phakic IOLs provide satisfactory results in refractive surgery for correction of myopia, hyperopia and astigmatism.^{1,2} The advantages of this procedure are preservation of accommodation, better quality of vision, potential reversibility of this procedure and stability and predictability of refractive outcome. The potential risks are cataract development,¹⁻³ sub-clinical intraocular inflammation,³⁻⁵ endothelial cell loss,^{3,6-9} intraocular pressure (IOP) rise¹⁰⁻¹² and risk of retinal detachment.^{3,13} To our knowledge, there is no Indian data published on anterior chamber iris supported PIOLs (PubMed Search).

The aim of the study was to evaluate the clinical and refractive results of Artisan phakic IOLs (Ophtec BV,

Groningen, The Netherlands) implanted in patients with high myopia.

Materials and Methods

A retrospective analysis of all patients who underwent Artisan phakic IOL implantation at our center between January 2002 and July 2003 was performed. A total of 60 eyes of 36 patients with follow-up of at least 24 months were included. The same surgeon (KPR) performed all surgical procedures at our hospital. A signed informed consent was taken from all patients before the procedure.

Patients >18 years of age with stable refractive error for at least one year and anterior chamber depth >2.9 mm, endothelial cell count >2000/mm², IOP <20 mmHg and not suitable for Lasik due to thin cornea were offered this procedure. Patients with corneal pathology, uveitis, glaucoma, maculopathy or retinopathy and those with previous corneal or intraocular surgery were not considered for this procedure.

A complete preoperative ocular examination was done on all patients, including an A scan biometry (BioMedix Optotechnik and Devices, Echorule 1, Bangalore, India), Goldmann appplanation tonometry (Haag Streit, Bern, Switzerland), keratometry and pachymetry (Orbscan II, Version 3, Bausch and Lomb, Rochester, NY) and endothelial cell count (Topcon 2000-p, Tokyo, Japan). The preoperative refraction required for calculating the power of the intraocular lens (IOL) was performed with and without cycloplegia

Maxivision Eye Hospital, Alladin Mansion, Begumpet, Hyderabad - 500 016, India

Correspondence to Dr. Sirisha Senthil, Maxivision Eye Hospital, Alladin Mansion, Begumpet, Hyderabad - 500016, India. E-mail: siddharth142@sify.com

Manuscript received: 3.8.05; Revision accepted: 1.7.06

(cyclopentolate hydrochloride 1.0%). Best spectacle corrected visual acuity (BSCVA) was measured before and after surgery. Dilated fundus examination including peripheral retinal screening was done. Three months prior to surgery, all patients underwent peripheral pan retinal photocoagulation (PPRP) of the peripheral retina with Argon Green Laser (Iris medical Oculight GL/GLX 532 nm). In this procedure, two rows of laser burns were applied to 360° periphery with extra coverage given for peripheral lattice and holes.

The Artisan myopia lenses used in our patients were convex-concave (models 206 and 204) iris fixated IOLs, designed by Jan Worst and manufactured by Ophtec BV, Groningen, The Netherlands. The overall length of the lens was 8.5 mm. The optic is manufactured in diameters of 5 and 6 mm. The 6 mm lens is available from -3 to -15.5 diopter (D) in half D steps and the 5 mm lens from -3 to -23.0 D in half D steps. Both lens designs are exactly the same and differ only in optical diameter and effective optical zone size. The height of either lenses does not exceed 0.95 mm. The power of the lens was calculated with the Van der Heijde's formula¹⁴ and was based on the refractive power of the cornea (mean corneal curvature, K), adjusted anterior chamber depth (ACD) and the patients spherical equivalent refractive error (spectacle correction at a 12.0-mm vertex).

The surgery was performed under peribulbar anesthesia with 2.5 ml marcaine and 2.5 ml lidocaine with hyaluronidase 150 IU in 34 patients and general anesthesia in two patients. One drop of 2% pilocarpine was instilled in the morning and 30 min prior to surgery.

The surgical protocol was the same for all patients. Two side port incisions were made at 2 o'clock and 11 o'clock positions. The anterior chamber was filled with Hyvisc plus (sodium hyaluronate solution, 14 mg/ml, Unimed Technologies Ltd. Halol, Gujarat). A clear corneal limbal incision of 6mm was made at 12 o'clock. The Artisan myopia lens was then introduced toward the 6 o'clock position, using a special forceps (Duckworth and Kent Ltd. Baldock Herts, England) designed for the claw lens. The lens was rotated using a lens rotator such that the haptics were at 3 and 9 o'clock positions. The PIOL was then held with a Budo forceps (Duckworth and Kent Ltd. Baldock Herts, England) at the outer part of the optic and the enclavation needle (Ophtec BV, Groningen, The Netherlands) passed through the paracenteses and iris tissue was enclavated [Fig. 1]. A peripheral iridectomy was performed with vannas scissors. After removing the viscoelastic from the anterior chamber the wound was closed with 10.0 nylon. Subconjunctival gentamicin was administered.

Postoperatively, prednisolone acetate eye drops 1%, six times daily tapering over four weeks and ofloxacin 0.3% (Nicholas Piramal India Ltd. Madhya Pradesh, India) eye drops four times daily for one week were used. Follow-up examinations were performed at one day, one week, three weeks, two-four months, six months and 12 months and annually thereafter. Patients with complications were examined more frequently.

Statistically significant differences between the means of the data samples were determined by one-way analysis of variance (ANOVA) and Kruskal-Wallis test. A probability

value <0.05 was considered statistically significant.

Results

Our patient population included 15 men and 21 women with a mean age of 22.6 ± 3.6 years (range: 18-32 years). All patients were followed up for 24 months. Preoperative myopia ranged from -5.0 to -24.0 D. Mean spherical equivalent refraction was -12.5 ± 4.96 D. The ACD ranged from 2.93 to 3.88 mm and the axial length (AL) ranged from 24.41 to 31.41 mm. Mean ACD was 3.24 ± 0.24 mm and mean AL was 25.77 ± 10.16 mm. The mean IOL power implanted was -13.11 ± 4.04 D (range: -5 to -22.5 D).

At three months, the uncorrected visual acuity (UCVA) was 20/20 or better in three eyes (5%), 20/30 or better in 34 eyes (56.6%) and 20/40 or better in 45 eyes (75%) [Fig. 2]. Forty-four eyes (73.3%) had refraction within ± 0.5 D, 54 eyes (90%) within ± 1 D, 59 eyes (98.3%) within ± 2 D [Figs. 3 and 4]. The postoperative refraction remained stable over a period of two years [Fig. 5]. The difference in mean spherical equivalent refraction at one week, three weeks, three months, six months, one and two years postoperatively was not statistically significant (ANOVA, $P=0.406$). The predictability was better in the lower level of myopia. Of the 20 eyes with myopia

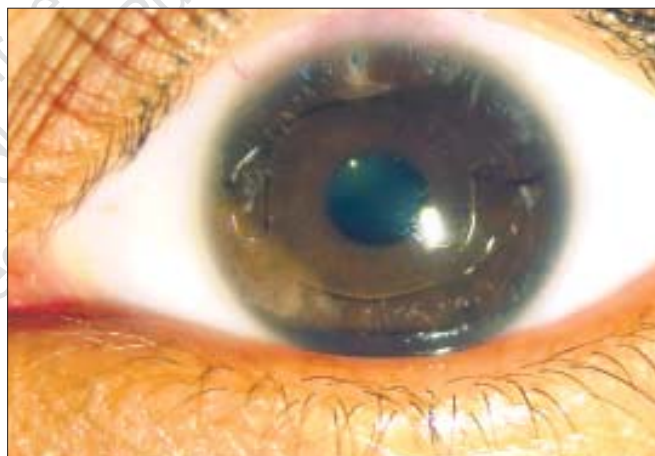


Figure 1: Photograph of eye with implanted Artisan Phakic IOL showing enclavation at 3 and 9 o'clock and Yag peripheral iridotomy at 12 o'clock

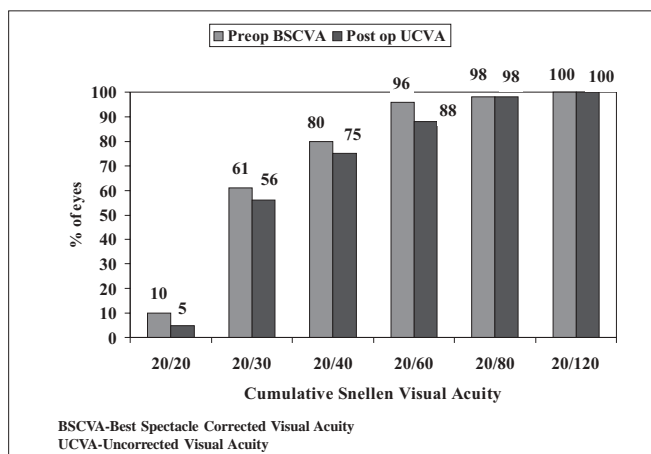


Figure 2: Comparison of preoperative best spectacle corrected visual acuity and postoperative uncorrected visual acuity

between -5 to -10 D, 19 (95%) had postoperative refraction within ± 1 D. In eyes with myopia ranging between -10.5 to -20 D, 33 out of 37 eyes (89%) had postoperative refraction within ± 1 D and in those with myopia between -20.5 to -24 D, two out of three eyes (66%) were within ± 1 D. The efficacy index was 0.93 at 24 months (average postop UCVA/average preop BSCVA). The mean preoperative astigmatism was -1.61 ± 1.07 D. By three months, the mean postoperative astigmatism was -0.4 ± 0.65 D. In terms of safety, BSCVA remained the same or improved in 53 eyes (88.3%). In seven eyes (11.6%) there was loss of one Snellen line. There was no loss of two Snellen lines in any patient [Fig. 6]. The safety index was 1.19 at 24 months (average postop BSCVA/average preop BSCVA).

The mean BCVA improved from 20/39 preoperatively to 20/32 postoperatively. Mean UCVA preoperatively was 20/384 and postoperatively was 20/41.

The endothelial cell count loss postoperatively [Fig. 7] was not statistically significant (ANOVA $P=0.406$). Mean density was 2741 ± 313 cells/mm² preoperatively, 2635 ± 315 cells/mm² at two-four months, 2598 ± 453 cells/mm² at six months, 2597 ± 320 cells/mm² at 12 months and 2566 ± 315 cells/mm² at two years.

In our study, postoperative complications included iritis,

IOP rise and dislocation of IOL. Anterior uveitis was observed in two eyes (3%) of which one eye had an inflammatory membrane with hypopyon. Both responded well to topical

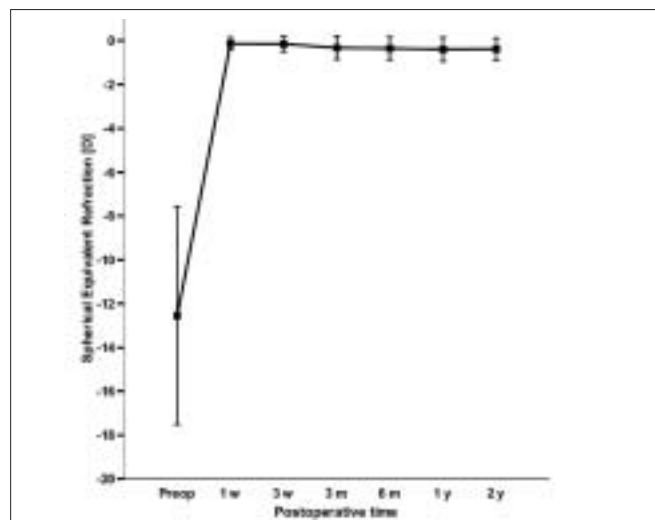


Figure 5: Stability of postoperative refraction over two years. Error bars indicate standard deviation

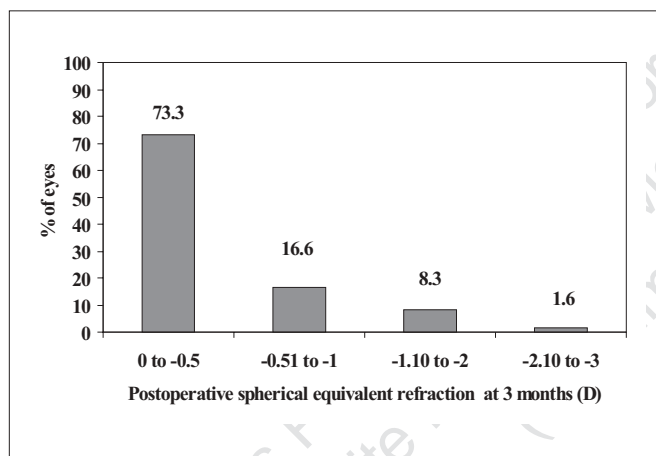


Figure 3: Postoperative spherical equivalent refractive outcome

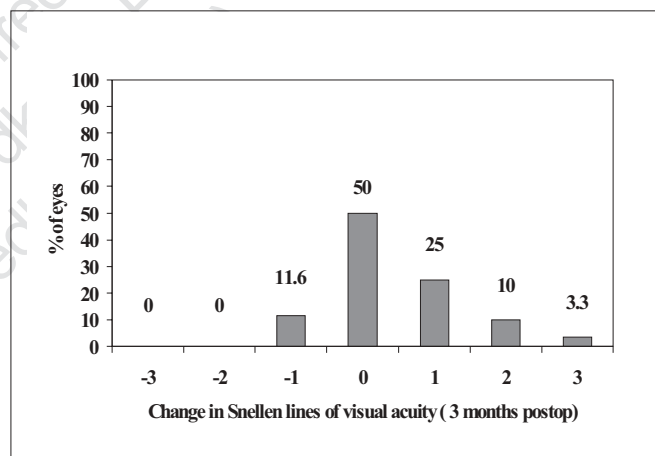


Figure 6: Change in postoperative spectacle corrected visual acuity

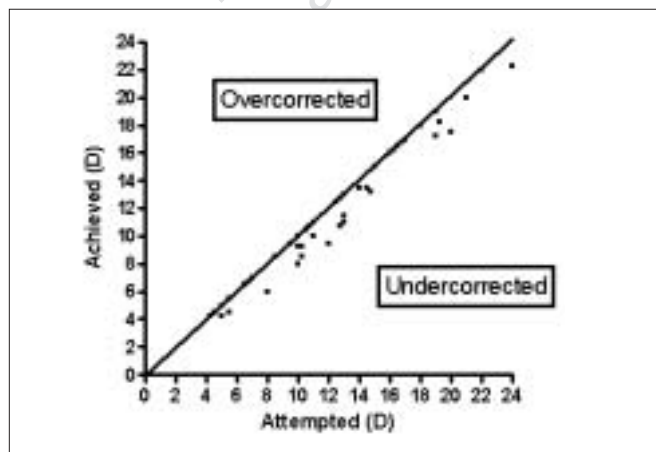


Figure 4: Scattergram of attempted versus achieved spherical equivalent refraction

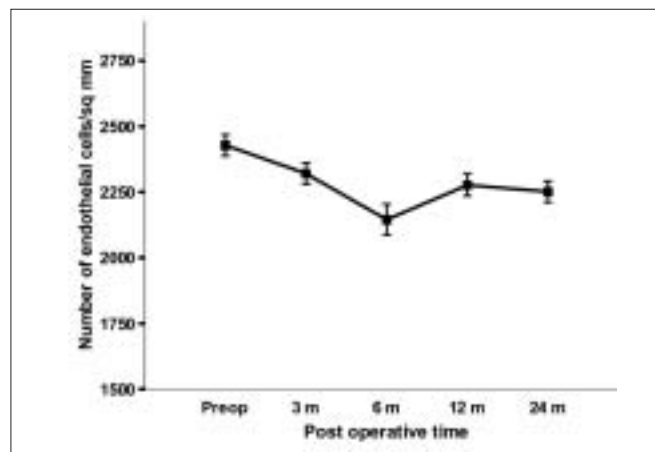


Figure 7: Mean endothelial cell density over two years. Error bars indicate standard deviation

and sub-conjunctival steroids and resolved completely. There was rise in IOP in six eyes (10%). In one eye IOP rise occurred in the first week after surgery, during the third to fourth postoperative weeks in three eyes and in the sixth postoperative week in two eyes. All of them were started on anti-glaucoma medication. As these eyes were thought to be steroid responders, the strength and dose of steroids were also reduced (fluoromethalone 0.1% starting four times daily and tapered over four weeks). In five eyes we were able to stop all the anti-glaucoma medication by 8-12 weeks. In one eye, there were intermittent spikes of high IOP with corneal edema and IOP was not controlled with maximal medical therapy. As the disc started showing glaucomatous damage the PIOL was explanted and clear lens extraction with trabeculectomy was done.

In two eyes, dislocation of PIOL occurred following trauma. In one eye, one haptic was dislocated which was repositioned surgically. One eye had dislocation of both haptics. The PIOL was explanted and clear lens extraction was performed in the same sitting.

Discussion

The primary outcome measure used to assess the effectiveness of refractive surgery was unaided postoperative visual acuity.^{15,16} In our study, at three months, 45 eyes (75%) achieved UCVA of 20/40 or better, which is comparable to 73.4% and 79.6% respectively in Landesz *et al.*⁶ and Benedetti *et al.*¹⁶

Secondary outcome measures included postoperative refraction within ± 0.5 to ± 1.0 D, postoperative astigmatism and mean endothelial cell loss. In our series, 44 eyes (73.3%) had postoperative refraction within ± 0.5 D, 54 eyes (90%) within ± 1 D and 59 eyes (98.3%) within ± 2 D. This was better compared to other published series where the postoperative refraction within ± 1 D ranged from 62.1% to 79.8%.^{14,16,17} In the US FDA study, 65% had a postoperative refraction of ± 0.5 D and 93% within ± 1 D.¹⁷ Mean preoperative astigmatism in our study was $-1.61\text{D} \pm 1.07\text{D}$. By three months, the astigmatism had reduced to -0.4 ± 0.65 D. This was comparable to other studies where preoperative astigmatism of 1.12 ± 0.8 D had reduced to 0.82 ± 0.62 D.¹⁸ In our study, seven eyes (11.6%) had loss of one Snellen line of visual acuity and there was no loss of two or more Snellen lines in any patient. Fifty-three eyes (88.3%) had either no loss or gained one or more lines of visual acuity. In comparison, the US FDA study showed that 5% of eyes lost one line and 95% had either no loss or gained one line or more.¹⁷ The efficacy index in our series was 0.93 that was comparable to two other published studies^{2,16} where the values were 0.93 and 0.84 respectively. Our safety index was 1.19, which was less than 1.31 reported by Budo *et al.*² and 1.12 and 1.39 in high and low myopia respectively reported by Benedetti *et al.*¹⁶

The mean endothelial cell loss in our series was 3.8% at three months, 5.2% at six months, 5.25% at 12 months and 6.38% at two years. The cell loss was more in the first few cases reflecting our learning curve. Some cases also showed a gain in endothelial cell density postoperatively. As reported by Landesz *et al.*, the variation in cell density measurement in healthy eyes ranged from 1.4 to 14.3 % with a mean of 6.2%.⁶

Several studies with Artisan iris claw lens implantation

reported endothelial damage and cell loss ranging from 6.5-13% at one year and 9.2-17.6% at two years.^{7,19-23} In our study, mean endothelial cell loss was similar to or lower than previously reported. Intraoperative complications like hyphema, traumatic cataract or iris prolapse were not encountered.

IOP rise was noted in six eyes (10%). After implantation of PIOLs, IOP rise can be caused by pupillary block, retained viscoelastic in the anterior chamber, decreased aqueous drainage due to trabecular mesh work block by fibrin, pigments and steroid responsiveness.²⁴ In five eyes the IOP was controlled medically and they were off medication within two-three months. In one eye with medically uncontrolled glaucoma, explantation of PIOL was done with clear lens extraction and trabeculectomy.

In our series, of the first four eyes that had a YAG peripheral iridotomy (PI) preoperatively, three eyes developed raised IOP postoperatively. Apart from retained viscoelastics after implantation of PIOL, increased pigment release following YAG PI in dark brown and black irides in the Indian population could be a possible cause. As our surgical skill and experience improved, we started doing a surgical PI instead of YAG PI and irrigation and aspiration was done thoroughly in all cases. Since then, we have noticed a decrease in the incidence of raised IOP postoperatively.

Postoperative iritis was noted in two eyes (3%). Inflammatory reaction in various studies ranged from 0-9.3%.^{3,16} An important complication associated with PIOLs is retinal detachment.^{3,4,13,14} We did not encounter any retinal detachment. Fencher *et al.*¹⁵ reported an incidence of 0.8% with iris-clipped PIOLs and Alio *et al.*⁴ reported 4.45% incidence with angle-supported PIOLs.

In our series all patients underwent prophylactic PRRP.²⁵ This procedure was done at least two-three months prior to surgery, to ensure good adhesion. We attribute the absence of postoperative retinal detachment to prophylactic PRRP. However, the efficacy of this procedure as a routine in all patients to prevent postoperative retinal detachment needs to be studied prospectively.

Glare or halos, which affect night vision and driving, is an important consideration in PIOL implantation. In our series, none experienced this complication, probably because Indian eyes have smaller pupil size compared to Caucasians. Other studies reported glare/haloes ranging from 6-8.8%.^{2,16} Other complications like iris atrophy,^{16,26} iris perforation,¹⁶ cataract development,²⁵ cystic wounds,³ Urrets Zavalía syndrome,^{27,28} vitreous hemorrhage,²⁹ ischemic optic neuropathy³⁰ and choroidal neovascularization,³¹ were not found in our series. Same surgeon performing all the procedures is the strength of the study. However, retrospective data, study from a single institution and possible bias are the limitations of the present study.

Conclusion

Our study results support the efficacy of phakic IOL as a refractive surgical procedure for correction of high myopia. It resulted in stable improvement in both UCVA and BSCVA over a two-year period with a few complications. The role of

PPRP as a prophylactic procedure to prevent postoperative retinal detachment and whether surgical PI results in lower incidence of postoperative IOP rise compared to YAG PI need to be studied prospectively. Longer follow-up is necessary to monitor for late complications.

References

- Rosen E, Gore C. Staar collamer posterior chamber phakic intraocular lens to correct myopia and hyperopia. *J Cataract Refractive Surg* 1998;24:526-606.
- Budo C, Hessloeh JC, Izak M, Luyten GP, Menezo JL, Sener BA, *et al.* Multicenter study of the Artisan phakic intraocular lens. *J Cataract Refract Surg* 2000;26:1163-71.
- Perez-Santonja JJ, Bueno JL, Zato MA. Surgical correction of high myopia in phakic eyes with Worst-Fechner myopia intraocular lenses. *J Cataract Surg* 1997;13:268-81.
- Alio JL, de la Hoz F, Ismail M. subclinical inflammatory reactions induced by phakic anterior chamber lenses for the correction of high myopia. *Ocular Immunol Inflammat* 1993;1:219-23.
- Prez-Santonja JJ, Iradier MT, Benitez del Castillo JM, Serrano JM, Zato MA. Chronic subclinical inflammation in phakic eyes with intraocular lenses to correct myopia. *J Cataract Refract Surg* 1996;22:183-7.
- Landesz M, van Rij G, Luyten G. Iris-claw phakic intraocular lens for high myopia. *J Cataract Refract Surg* 2001;17:634-40.
- Menezo JL, Cisneros AL, Rodriguez-Salvador V. Endothelial study of iris-claw phakic lens: Four year follow-up. *J Cataract Refract Surg* 1998;24:1039-49.
- Bourne WM, Nelson LR, Hodge DO. Central corneal endothelial cell changes over a ten-year period. *Invest Ophthalmol Vis Sci* 1997;38:779-82.
- Dick HB, Kohner T, Jacobi FK, Jacobi KW. Long-term endothelial cell loss following phacoemulsification through a temporal clear corneal incision. *J Cataract Refract Surg* 1996;22:63-71.
- Alio JL, de la Hoz F, Perez-Santonja JJ, Ruiz-Moreno JM, Quesada JA. Phakic anterior chamber lenses for the correction of myopia: A 7-year cumulative analysis of complications in 263 cases. *Ophthalmology* 1999;106:458-66.
- Arne JL, Lesueur LC. Phakic posterior chamber lenses for high myopia: Functional and anatomical outcomes. *J Cataract Refract Surg* 2000;26:369-74.
- Aguilar-Valenzuela L, Lleo-Perez A, Alonso-Munoz L, Casanova-Izquierdo J, Perez-Molto FJ, Rahhal MS. Intraocular pressure in myopic patients after Worst-Fechner anterior chamber phakic intraocular lens implantation. *J Refract Surg* 2003;19:131-6.
- Burton TC. The influence of refractive error and lattice degeneration on the incidence of retinal detachment. *Trans Am Ophthalmol Soc* 1989;87:145-57.
- Vander Heijde GL. Some optical aspects of implantation of an intra ocular lens in a myopic eye. *Eur J Implant Refract Surg* 1989;1:245-8.
- Perez-Santonja JJ, Alio JL, Jimenez-Alfaro I, Zato MA. Surgical correction of severe myopia with an angle-supported phakic intra ocular lens. *J Cataract Refract Surg* 2000;26:1288-302.
- Benedetti S, Casamenti V, Marcaccio L, Brogioni C, Assetto V. Correction of myopia of 7 to 24 Diopters with the Artisan Phakic intraocular lens: Two-year follow-up. *J Cataract Refract Surg* 2005;21:116-26.
- Kerry K. Assil The ARTISAN myopia lens: Interim results of the US FDA clinical study. <http://www.opthalmichyperguide.com> [posted March 2004] Accessed Dec 2005.
- Maloney RK, Nguyen LH, John ME. Artisan phakic intraocular lens for myopia: Short-term results of a prospective, multicenter study. *Ophthalmology* 2002;109:1631-41.
- Faulkner GD. Endothelial cell loss after phacoemulsification and insertion of silicone lens implants. *J Cataract Refract Surg* 1987;13:649-52.
- Hoffer KJ, Kraff MC. Normal endothelial cell count range. *Ophthalmology* 1980;87:861-6.
- Perez-Santonja JJ, Iradier MT, Sanz-Iglesias L, Serrano JM, Zato MA. Endothelial changes in phakic eyes with anterior chamber intraocular lenses to correct high myopia. *J Cataract Refract surg* 1996;22:1017-22.
- Werblin TP. Long-term endothelial cell loss following phacoemulsification: Model for evaluation endothelial damage after intraocular surgery. *Refract Corneal Surg* 1993;9:29-35.
- Landesz M, Worst JG, Siertsema JV, van Rij G. Correction of high myopia with the worst myopia claw intraocular lens. *J Cataract Refract Surg* 1995;11:16-25.
- Levy Y, Nemet P. Increased intraocular pressure with corticosteroid medication after photorefractive keratectomy. *Surv Ophthalmol* 1996;41:187-8.
- Aylward GW. Screening for retinal detachment. *J Med Screen* 2001;8:116-8.
- Menezo JL, Avino JA, Cisneros AL, Rodriguez-Salvador V, Martinez-Costa R. Iris claw phakic intraocular lens for high myopia. *J Cataract Refract Surg* 1997;13:545-55.
- Fechner PU, Van der Heijde GL, Worst JG. The correction of myopia by lens implantation into phakic eyes. *Am J Ophthalmol* 1989;107:659-63.
- Fechner PU, Strobel J, Wichmann W. Correction of myopia by implantation of a concave Worst-iris claw lens into phakic eyes. *Refract Corneal Surg* 1991;7:286-98.
- Nuzzi G, Cantu C. Vitreous hemorrhage following phakic anterior chamber intraocular lens implantation in severe myopia. *Eur J Ophthalmol* 2002;12:69-72.
- Perez-Santonja JJ, Bueno JL, Meza J, Garcia-Sandoval B, Serrano JM, Zato MA. Ischemic optic neuropathy after intraocular lens implantation to correct high myopia in a phakic patient. *J Cataract Refract Surg* 1993;19:651-4.
- Ruiz-Moreno JM, de la Vega C, Ruiz-Moreno O, Alio JL. Choroidal neovascularization in phakic eyes with anterior chamber intraocular lenses to correct high myopia. *J Cataract Refract Surg* 2003;29:270-4.

Source of Support: Nil, **Conflict of Interest:** None declared.