
Management of bipseudophakia with implantation of an iris claw lens

Milan G.J. Izak, MD, PhD, Liliana Werner, MD, PhD, Andrea M. Izak, MD, David J. Apple, MD

We discuss a case of bipseudophakia with secondary dislocation of a posterior chamber intraocular lens (IOL) into the anterior chamber that was managed by explantation of the anterior and posterior chamber IOLs and implantation of an iris claw IOL.

J Cataract Refract Surg 2003; 29:1445–1447 © 2003 ASCRS and ESCRS

The presence of a dislocated intraocular lens (IOL) in the vitreous carries the risk for delayed complications. The dislocated IOL may cause vitreous changes and trauma to the retina. Instability of the dislocated IOL may result in significant visual disturbances.^{1,2} In some eyes containing a posterior chamber (PC) IOL dislocated into the vitreous cavity, an anterior chamber (AC) IOL has been implanted without removal of the posteriorly dislocated IOL.

We have termed the condition in which an eye contains AC and PC IOLs *bipseudophakia* and recently described the first clinicopathological correlation of this condition in a human eye obtained post-mortem.³ We now report a case of bipseudophakia in which the patient presented with partial pupillary capture of the luxated IOL 5 years after implantation of the AC IOL.

Case Report

A 62-year-old white woman had right extracapsular cataract extraction with implantation of a single-piece poly(methyl methacrylate) PC IOL in March 1996. The left eye was pseudophakic with a best corrected visual acuity (BCVA) of 20/20. In April 1996, the patient presented with diplopia and PC IOL subluxation in the right eye. In May, a surgical procedure to reposition the PC IOL in combination with an anterior vitrectomy was unsuccessful. The PC IOL completely dislocated into the vitreous cavity. An AC IOL (Kelman Multiflex lens) was implanted in the right eye on the following day without attempted removal of the dislocated PC IOL. In September 1996, the BCVA in the right eye was 20/20.

In October 1996, the patient had preventive cryoretinopexy in the right eye. Three years later, she presented with hand motion acuity in the same eye. At this time, she was evaluated for the first time by 1 of us (M.G.J.I.). B-scan ultrasonography and indirect ophthalmoscopy revealed that the retina was detached in both upper quadrants (no retinal break was located) and the PC IOL was at 6 o'clock in the retinal periphery. The retinal detachment was treated with a scleral buckling procedure, cryotherapy, and instillation of air. The PC IOL was left in the vitreous cavity. In January 2000, aspiration of a secondary cataract was performed and the visual acuity improved from 20/300 to 20/32.

In February 2001, 5 years after implantation of the AC IOL, the patient presented with visual acuity reduced to hand motions. The PC IOL was back in the anterior segment. One haptic and part of the optic was captured through the deformed pupil. The AC IOL remained well positioned (Figure 1, A). Specular microscopy disclosed an endothelial cell count of 624 cells/mm².

The PC IOL was maneuvered into the anterior chamber. It was explanted through a 6.0 mm temporal scleral tunnel

Accepted for publication October 29, 2002.

From the Department of Ophthalmology, F.D. Roosevelt Hospital (M. Izak), Banka Bystrica, Slovak Republic, and the Moran Eye Center, University of Utah (Werner, A. Izak, Apple), Salt Lake City, Utah, USA.

Presented in part at the ASCRS Symposium on Cataract, IOL and Refractive Surgery, Philadelphia, Pennsylvania, USA, June 2002.

Supported in part by an unrestricted grant from Research to Prevent Blindness, Inc., New York, New York, USA.

None of the authors has a financial interest in any product mentioned.

Reprint requests to Liliana Werner, MD, PhD, Moran Eye Center, University of Utah, 50 North Medical Drive, Salt Lake City, Utah 84132, USA. Liliana.werner@hsc.utah.edu.

incision after a large anterior synechia at 10:30 was released. The AC IOL was then explanted without difficulty. Inspection confirmed that the central posterior capsule was intact, but retraction of the iris revealed zonular dialysis in the upper nasal quadrant. The pupil remained decentered and ovalized perpendicular to the axis of the AC IOL.

After aspiration of the Elschnig pearls, an iris claw IOL (Artisan aphakic lens) was implanted (Figure 1, *B*). The site of fixation of the IOL was determined by the pupil decentration. The procedure was uneventful. The visual acuity improved to 20/32 in the first postoperative week. The retina remained attached, and specular microscopy disclosed 524 endothelial cells/mm².

The explanted AC and PC IOLs from the right eye were submitted to the Center for Biodevices and evaluated in March 2001. Gross (macroscopic) analysis of the IOLs was performed, and gross pictures were taken using a camera (Nikon N905 AF) fitted to an operating microscope (Leica/Wild MZ-8 Zoom Stereomicroscope, Vashaw Scientific, Inc.). The IOLs were then evaluated under an Olympus light microscope and photographed. Gross and microscopic examination

of the explanted IOLs revealed crystalline deposits on the IOL surfaces, probably caused by precipitation of viscoelastic material (Figures 2 and 3, *A*). Small fragments of uveal tissue and pigment were found on 1 AC IOL haptic (Figure 3, *B*). No other abnormality was noted.

Discussion

Management of a dislocated IOL remains controversial, especially in the absence of symptoms or retinal complications.⁴ Many options for treatment have been reported, including aphakic correction with spectacles or contact lenses, implantation of a secondary AC IOL, repositioning the dislocated IOL with or without suturing, and explantation of the dislocated IOL and replacement by another AC, PC, or iris-fixated IOL.¹⁻⁶ Williams et al.¹ describe the surgical management of complications in eyes containing 2 IOLs. In their report of 8 cases, the authors explain the hazards of placing a

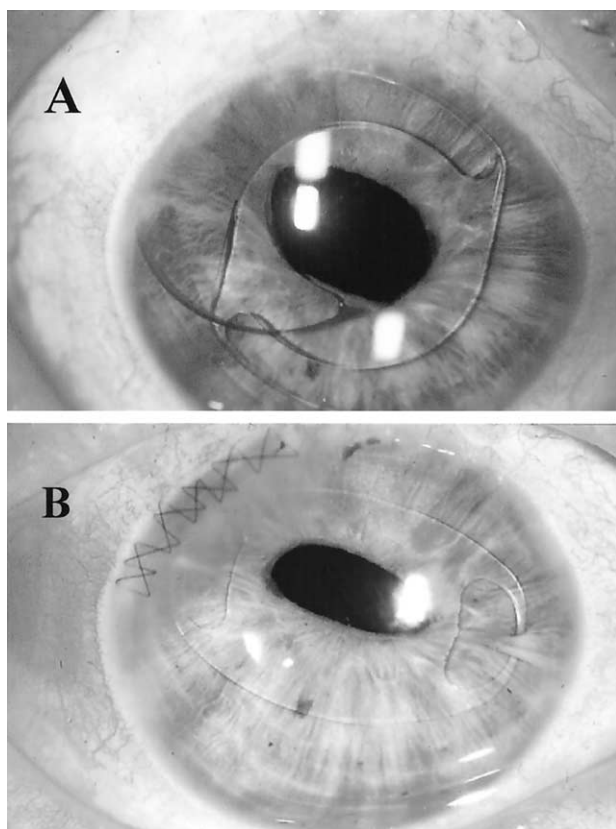


Figure 1. (Izak) *A*: Slitlamp photograph showing partial pupillary capture of the subluxated PC IOL. The AC IOL remained well positioned. *B*: Slitlamp photograph showing the iris claw IOL implanted after PC and AC IOL removal (first postoperative day). The axis of pupil ovalization remained the same as in Figure 1, *A*.

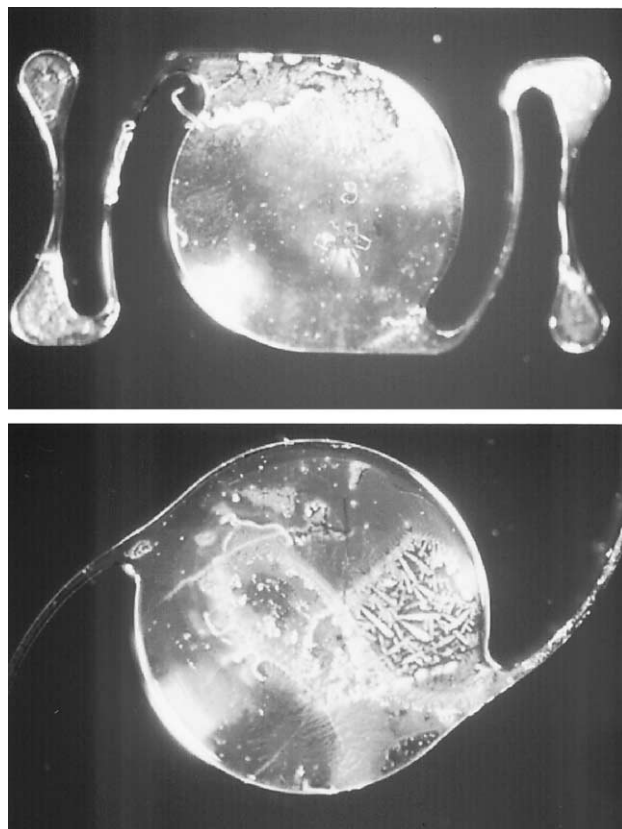


Figure 2. (Izak) Gross photographs of the explanted IOLs showing crystalline deposits on the IOL surfaces probably caused by precipitation of viscoelastic material. *Top*: AC IOL. *Bottom*: PC IOL.

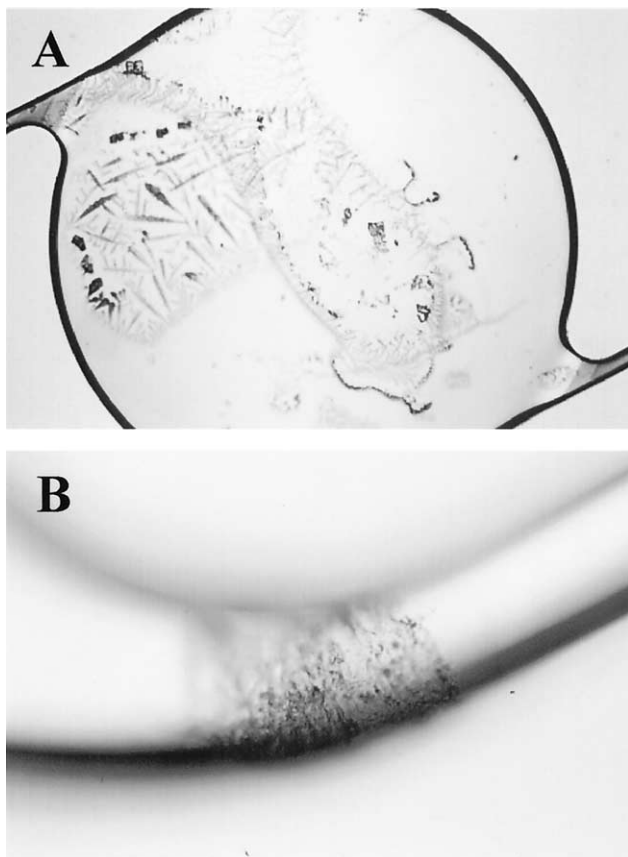


Figure 3. (Izak) A: Photomicrograph of the explanted PC IOL. Crystalline deposits related to viscoelastic crystallization can be observed on the IOL surface. B: Photomicrograph of the AC IOL haptic involved in the anterior synechia. Small fragments of uveal tissue and pigment were found in the middle of the haptic.

secondary AC IOL in an eye containing a dislocated PC IOL. They also state that it is not known how often and for how long eyes containing 2 IOLs will maintain good vision without complications. However, it is clear that the surgical management of posterior segment complications is more complex with bipseudophakia.

In our case, the initial attempt to reposition the decentered PC IOL with an anterior vitrectomy was not successful and the IOL dislocated into the vitreous cavity. Because the PC IOL was neither mobile nor obstructing the visual axis, the surgeon decided to implant an AC IOL, leaving the dislocated PC IOL undisturbed. Three years later, the patient presented with a retinal detachment that did not seem related to the subluxated PC IOL. The surgeon performed a scleral buckling procedure, cryotherapy, and air instillation. Five years after

the initial surgery, the patient returned with partial pupillary capture of the PC IOL. We could find only 1 report of partial pupillary capture of a luxated PC IOL occurring 6 months after AC IOL implantation in a case of bipseudophakia.⁵ Our case shows that a dislocated PC IOL may become unstable long after the original surgery.

After successful PC IOL explantation, the surgeon decided to explant the AC IOL because of anatomic changes in the anterior chamber angle and possible complications such as ovalization of the pupil due to chronic peripheral ischemia of the iris, corneal decompensation, and secondary glaucoma. The disinsertion of the zonules in the upper nasal quadrant excluded the option of PC IOL reimplantation in the sulcus. Exchange implantation of the iris claw IOL was performed to avoid direct interaction with the structures in the anterior chamber angle. It has been alleged that the iris claw IOL may be more appropriate for eyes with a compromised cornea and peripheral anterior synechias,⁷ although this remains a controversial issue.

Regardless of the surgical alternative the surgeon selects, this case emphasizes the potential for complications and the available options to manage a challenging patient with bipseudophakia.

References

1. Williams DF, Del Piero EJ, Ferrone PJ, et al. Management of complications in eyes containing two intraocular lenses. *Ophthalmology* 1998; 105:2017–2022
2. Brockman EB, Franklin RM, Kaufman HE. Visual disability resulting from a dislocated intraocular lens. *J Cataract Refract Surg* 1993; 19:312–313
3. Izak AM, Apple DJ, Werner L, et al. Bipseudophakia: clinicopathological correlation of a dropped lens. *J Cataract Refract Surg* 2002; 28:874–882
4. Connolly BP, McNamara JA, Shah GK, Bauman CR. Retinal detachment with a dislocated posterior chamber intraocular lens. *Arch Ophthalmol* 2001; 119:909–911
5. Taguri AH, Singh J, Khan MA. Delayed reappearance of a dislocated lens [letter]. *J Cataract Refract Surg* 2001; 27: 804
6. Aggarwal JL, Ahluwalia HS. An alternative approach to a posteriorly dislocated intraocular lens. *Indian J Ophthalmol* 1999; 47:36–37
7. Lois N, Kowal VO, Cohen EJ, et al. Indications for penetrating keratoplasty and associated procedures, 1989–1995. *Cornea* 1997; 16:623–629