

# Penetrating keratoplasty combined with posterior Artisan<sup>®</sup> iris-fixated intraocular lens implantation

Paul Dighiero,<sup>1</sup> Sébastien Guigou,<sup>1</sup> Martial Mercie,<sup>1</sup> Benoit Briat,<sup>1,2</sup> Pierre Ellies<sup>3,4</sup> and Jean-Jacques Gicquel<sup>1</sup>

<sup>1</sup>Department of Ophthalmology, Jean Bernard University Hospital, Poitiers, France

<sup>2</sup>Department of Ophthalmology, The Atlantic Private Hospital, La Rochelle, France

<sup>3</sup>Department of Ophthalmology, The Cave Private Hospital, Montauban, France

<sup>4</sup>Department of Ophthalmology, Pasteur Private Hospital, Toulouse, France

## ABSTRACT.

**Purpose:** To present a new surgical technique combining penetrating keratoplasty and open-sky posterior iris fixation of the Artisan<sup>®</sup> iris-claw intraocular lens (IOL) for treatment of pseudophakic bullous keratopathy in a case series of five patients.

**Methods:** A graft diameter of 8.25 mm was chosen. The formerly implanted angle-supported IOL was removed. The IOL was enclosed, entrapping a fraction of the mid-peripheral iris within the haptics whilst being held firmly with the implantation forceps. The corneal button was sutured to the recipient bed with 10-0 nylon sutures. A specular microscope was used for making an endothelial cell count. Patients underwent an ultrasound biomicroscope (UBM) scan before and 6 months after surgery and postoperative macular oedema was assessed by optical coherence tomography (OCT). The minimum follow-up was 12 months.

**Results:** Visual acuity (VA) improved in all five cases (mean best corrected VA was 0.4 postoperatively versus 1.28 preoperatively). No complications were noted. The mean endothelial cell density obtained after 1 year was 1508 cells/mm<sup>2</sup>. The UBM study showed a deep anterior chamber and an open iridocorneal angle of 360 degrees in all cases.

**Conclusion:** The implantation of the Artisan device behind the iris better preserves the anatomy of the anterior segment with respect to the iridocorneal angle.

**Key words:** Artisan – bullous keratopathy – penetrating keratoplasty – ultrasound biomicroscope (UBM) – surgical technique

Acta Ophthalmol. Scand. 2006; 84: 197–200

Copyright © Acta Ophthalmol Scand 2006.

doi: 10.1111/j.1600-0420.2005.00573.x

## Introduction

We present a new surgical technique combining penetrating keratoplasty and open-sky posterior iris fixation of

the Artisan<sup>®</sup> (Verisyse<sup>™</sup>, AMO, Mougins, France) iris-claw intraocular lens (IOL) for the treatment of pseudophakic bullous keratopathy in five

patients. This surgical technique was designed to respect anterior segment anatomy as closely possible; the ideal position for the IOL after extracapsular cataract extraction is behind the iris plane. We confirmed that the anterior segment anatomy was preserved with our technique (normal anterior chamber depth and wide iridocorneal angle) by systematically examining patients postoperatively with the ultrasound biomicroscope (UBM) (Zeiss-Humphrey, Le Pecq, France) developed by Pavlin et al. (1991).

This technique was effective in our series of five patients, who presented with major bullous keratopathy induced by cataract surgery associated with anterior chamber angle-supported IOL implantation, but with no history of macular cystoid oedema.

## Materials and Methods

Each patient underwent a UBM scan and systematic ophthalmological examination the day before surgery. Best corrected visual acuity (BCVA) and intraocular pressure (IOP) (measured with a contact Goldman applanation tonometer) were noted. The surgical procedure was performed under sub-Tenon's anaesthesia in two cases and under general anaesthesia in three cases. All operations were performed by the same surgeon (PD). All patients

underwent corneal trephination with the Hanna trephine. The recipient's corneal button was then cut out with scissors. A graft diameter of 8.25 mm was chosen (8 mm for the recipient bed). In all patients, removal of the angle-supported IOL implanted previously was followed by complementary anterior vitrectomy. In two cases, this was associated with synechiolysis of the angle. Iridoplasty was performed in one case to centre the pupil. After the intracameral injection of acetylcholine (to constrict the pupil to facilitate centering), an Artisan IOL was implanted as described in Figs 1 and 2. The lens was rotated into the desired position (haptics at 3 o'clock and

9 o'clock). The IOL was enclosed, entrapping a fraction of the mid-peripheral iris within the haptics whilst being firmly held with the Artisan implantation forceps. The donor's corneal button was then sutured to the recipient bed with 10-0 nylon sutures. All patients received topical dexamethasone and neomycin four times per day for 1 month after the operation. This treatment was tapered over the following 4-6 months. It is to be noted that neomycin is only necessary for a short time after surgery, and may induce bacterial resistance. However, dexamethasone alone is not widely available in France, so we had to use the combination of dexamethasone + neomycin in our protocol. After 6 months, each patient was re-examined. Best corrected VA and IOP were noted and compared to preoperative data. The graft clarity was assessed by slit-lamp examination. Endothelial cells were counted with a contact specular microscope (EM-1000; Tomey, Erlangen, Germany). All patients underwent a UBM scan 6 months after surgery and postoperative macular oedema was assessed by optical coherence tomography (OCT) (OCT 3; Zeiss-Humphrey).

### Results

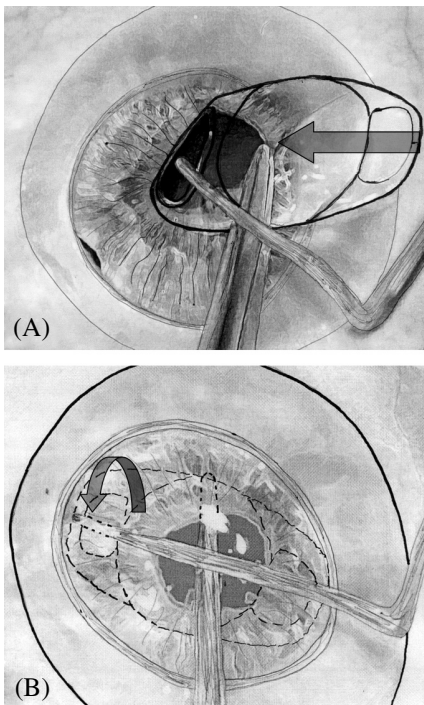
All five patients were followed at least for 12 months. The pre- and postoperative (6 months after surgery) data are summarized in Table 1. The mean age of our patients at the time of surgery was 79.6 years. Visual acuity improved noticeably in all cases (mean BCVA was 0.4 6 months postoperatively versus 1.28 preoperatively). In all cases, VA remained stable for the entire follow-up period. No complications were noted in this preliminary series; in particular, we observed no cases of IOL dislocation. No patient presented postoperative cystoid macular oedema on OCT scans. Slit-lamp examination showed that all grafts were clear after 6 months and that the anterior chamber was quiet in all patients. The mean endothelial cell density obtained after 6 months was 1487 cells/mm<sup>2</sup>. The UBM study showed a deep 'neo' anterior chamber (depth measured between the upper face of the IOL and the endothelium) and an open iridocorneal angle of

360 degrees in all cases. The clipping zone of the haptics was clearly visible along the 3 o'clock to 9 o'clock axis, provoking a depression in the iris plane. There was no contact between the IOL and the endothelium, or between the haptics and the ciliary body. Pigmentary dispersion that might have been anticipated, due to possible rubbing between the iris and the anterior face of the IOL, was not observed postoperatively.

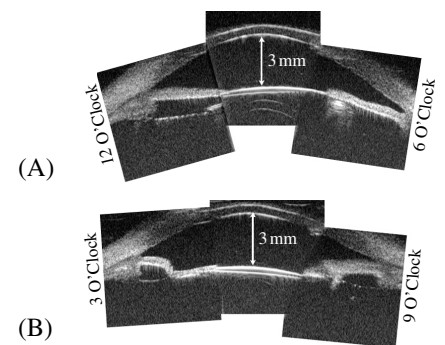
The mean IOP was lower after surgery (15.6 mmHg versus 19.2 mmHg the day before surgery). Longterm follow-up showed that these data tended to remain stable over time.

### Discussion

Patients who develop bullous keratopathy following cataract surgery with anterior chamber angle-supported IOL implantation typically require penetrating keratoplasty, due to the lack of a better technique. The first steps of this procedure give the surgeon access to the anterior segment via the open-sky approach. This facilitates IOL explantation, anterior vitrectomy, synechiolysis, pupilloplasty and IOL implantation. Once the former IOL has been removed, the surgeon may leave the patient aphakic. Aphakia may be corrected postoperatively by a gas-permeable contact lens that will help correct keratoplasty-induced astigmatism. In our experience, older patients have



**Fig. 1.** Schematic representation of the open-sky posterior Artisan IOL enclavation procedure. (A) The Artisan IOL (polymethylmethacrylate with a convex concave profile) is inserted with the implantation forceps and slid through the pupil area; a Sinskey-type manipulating instrument is used to recline the iris sphincter gently. (B) The IOL is now behind the iris plane. While the IOL is maintained horizontally with the forceps, centred over the pupil, with the haptics positioned at 3 o'clock and 9 o'clock, the iris is entrapped using the Sinskey-type manipulating instrument (arrow), by applying gentle pressure over it through the slotted centre of the lens haptic. A sufficient amount of iris tissue must be delivered through the haptic slot to create a fold to ensure lasting lens stability and to prevent it from moving into the vitreous. The Sinskey-type manipulator is then retracted, taking care not to damage the iris surface.



**Fig. 2.** Postoperative composite picture of three longitudinal axial UBM echograms of the Artisan IOL implanted under the iris in patient no. 2. (A) The IOL appears hyperechoic with marked backscatter effect. The anterior chamber is deep (3 mm). (B) On the 3 o'clock/9 o'clock plane, the clipping zone of the haptics is clearly visible, provoking a depression of the iris plane. (A) and (B) demonstrate that the iridocorneal angle is wide (360 degrees).

**Table 1.** Demographic, preoperative and postoperative data for patients 1–5.

Patient	Sex	Age (years)	Eye	Preop VA IM	Preop VA Snellen	Postop VS IM	Postop VA Snellen	Preop IOP	Postop IOP	OCT ME	Clarity	Endothelial cell count per mm <sup>2</sup> at 6 months	Endothelial cell count per mm <sup>2</sup> at 1 year
1	F	88	OD	1.5	20/630	0.5	20/63	18	15	–	4	1535	1600
2	F	87	OD	1.5	20/630	0.4	20/50	22	17	–	4	1655	1645
3	M	82	OS	1.3	20/400	0.5	20/63	19	12	–	4	1380	1435
4	M	76	OD	0.8	20/125	0.1	20/25	20	19	–	4	1320	1300
5	M	65	OS	1.3	20/400	0.5	20/63	17	15	–	4	1545	1560
Mean		79.6		1.28		0.4		19.2	15.6		4	1487	1508

Preop VA IM = preoperative visual acuity measured in logMAR (log of the minimum angle of resolution). It states the visual acuity in absolute terms and makes the calculation of a mean visual acuity possible.

Postop VA IM = postoperative visual acuity measured in logMAR.

Data also appear in Snellen acuity (Preop VA Snellen)/(Postop VA Snellen).

Preop IOP = preoperative intraocular pressure.

Postop IOP = postoperative intraocular pressure.

OCT ME = detection of macular oedema with ocular coherence tomography.

difficulty in dealing with contact lens care, and permanent lens wear is not advisable on a corneal graft. Although recently developed angle-supported IOLs seem to be less harmful to the corneal endothelium than their predecessors, they are still not ideal (Hara 2004). Their iridocorneal angle fixation inevitably leads to endothelial cell loss and bullous keratopathy. The learning curve for implanting transcleral sulcus sutured IOLs, especially during open-sky surgery, is long and steep. Their complications include chronic inflammation, IOL–iris contact, pigment dispersion, high aqueous flare, vitreous incarceration and BCVA loss due to cystoid macular oedema (Dadeya et al. 2003). Current-generation refractive, iris-fixated, anterior chamber IOLs, such as the Artisan, leave enough space between themselves and the endothelium to avoid harming the endothelium in phakic and aphakic eyes with genuine uncut corneas (Budo et al. 2000). Artisan IOLs are placed inside the anterior chamber and clawed onto the mid-peripheral iris. They have previously been used in combination with keratoplasty for the surgical management of aphakic bullous keratopathy (Kanellopoulos 2004) and for the correction of high myopia after penetrating keratoplasty (Moshirfar et al. 2004). Although penetrating keratoplasty usually creates irregular astigmatic patterns (Karabatsas et al. 1999), we found that when the Artisan IOL is clipped to the iris the iridocorneal angle is closed significantly and the anterior chamber becomes shallow. These

findings are consistent with our UBM findings obtained with a preliminary series of eight patients grafted and implanted according to classic Artisan protocol. The implantation of the Artisan IOL in the anterior chamber modified the parameters defined by Pavlin & Foster (1992) (angle-opening distance, iridocorneal angle, anterior chamber depth). This led us to implant the Artisan device behind the iris. We hoped that this would better preserve the anatomy of the anterior segment. Intraocular pressure values may have decreased postoperatively because the anatomical iridocorneal angle was respected. The absence of contact between the endothelium and the IOL explains the good cellular density noted in all cases after 6 months. The BCVAs obtained with our technique after 6 months are similar to those published in a previous series in which patients were treated with a combination of penetrating keratoplasty and anterior over-the-iris Artisan IOL clipping (Kanellopoulos 2004). The absence of contact between the IOL and the ciliary body, and of postoperative aqueous flare in the anterior chamber, seem to have preserved patients from loss of BCVA by cystoid macular oedema. Our technique also offers the advantage of being compatible with the newly developed posterior lamellar keratoplasty techniques (Melles et al. 2000). Posterior clipping in an aphakic eye is still possible even in the absence of open-sky access.

However, the technique has to be modified in the absence of open-sky access: a non-penetrating pre-incision

measuring 6.2 mm at 12 o'clock is followed by a corneal incision to allow the introduction of the Artisan device in the anterior chamber after injection of a viscoelastic substance. Two paracenteses of 1.2 mm (one beginning at 2 o'clock and one at 10 o'clock) will be needed for enclavation, as is the case for classic Artisan implantation in phakic eyes (Budo et al. 2000). Once inside the anterior chamber, the IOL is rotated to the 3 o'clock/9 o'clock position. Using the enclavation forceps, it must be slid behind the iris as previously described. The iris entrapment technique does not differ from that used in open-sky surgery, but the Sinsky manipulator is introduced through the paracenteses.

## References

- Budo C, Hessloeh JC, Izak M et al. (2000): Multicentre study of the Artisan phakic intraocular lens. *J Cataract Refract Surg* **26**: 1163–1171.
- Dadeya S, Kamlesh, Kumari SP (2003): Secondary intraocular lens (IOL) implantation: anterior chamber versus scleral fixation: longterm comparative evaluation. *Eur J Ophthalmol* **13**: 627–633.
- Hara T (2004): Ten-year results of anterior chamber fixation of the posterior chamber intraocular lens. *Arch Ophthalmol* **122**: 1112–1116.
- Kanellopoulos AJ (2004): Penetrating keratoplasty and Artisan iris-fixated intraocular lens implantation in the management of aphakic bullous keratopathy. *Cornea* **23**: 220–224.
- Karabatsas CH, Cook SD & Sparrow JM (1999): Proposed classification for topographic patterns seen after penetrating keratoplasty. *Br J Ophthalmol* **83**: 403–409.

Melles GR, Lander F, van Dooren BT, Pels E & Beekhuis WH (2000): Preliminary clinical results of posterior lamellar keratoplasty through a sclerocorneal pocket incision. *Ophthalmology* **107**: 1850–1856; Discussion 1857.

Moshirfar M, Barsam CA & Parker JW (2004): Implantation of an Artisan phakic intraocular lens for the correction of high myopia after penetrating keratoplasty. *J Cataract Refract Surg* **30**: 1578–1581.

Pavlin CJ & Foster FS (1992): Ultrasound biomicroscopy in glaucoma. *Acta Ophthalmol* **204** (Suppl): 7–9.

Pavlin CJ, Harasiewicz K, Sherar MD & Foster FS (1991): Clinical use of ultrasound biomicroscopy. *Ophthalmology* **98**: 287–295.

---

Received on March 6th, 2005.

Accepted on August 1st, 2005.

*Correspondence:*

Paul Dighiero  
Department of Ophthalmology  
Jean Bernard University Hospital  
2 rue de la Milétrie  
BP 577  
86021 Poitiers  
France  
Tel: + 33 5 49 44 43 17  
Fax: + 33 5 49 44 46 68  
Email: pauldighiero@aol.com