

# COMBINED PARS PLANA PHACOFRAGMENTATION, VITRECTOMY, AND ARTISAN LENS IMPLANTATION FOR TRAUMATIC SUBLUXATED CATARACTS

LAURENT KODJIKIAN, MD, PhD,\*†‡ FRANCIS BEBY, MD,‡  
MYRIAM SPIRE, MD,\* JOEL GAMBRELLE, MD,\* ISABELLE HUBERT, MD,\*  
CAROLE BURILLON, MD,‡ JEAN-DANIEL GRANGE, MD,\*  
JUSTUS G. GARWEG, MD†

---

**Purpose:** To report on the outcome of combined pars plana phacofragmentation, vitrectomy, and Artisan lens implantation in the management of subluxated cataracts.

**Methods:** This prospective, interventional, nonrandomized case series included nine eyes of seven consecutive adult patients with traumatic lens subluxation. Pre- and postoperative data (complete manifest refraction, best spectacle-corrected visual acuity, slit-lamp examination findings, intraocular pressure, fundus status, numerical density of endothelial cells, corneal thickness, and complications) were collected prospectively for all patients.

**Results:** After a median postoperative follow-up of 12 months (range, 8–18 months), a mean spherical equivalent of  $-0.50 \pm 0.87$  diopter (range, +1 to -1.50 diopter) was achieved. The mean logarithm of the minimum angle of resolution visual acuity improved from 1 (preoperatively) to 0.1 (postoperatively) ( $P = 0.007$ , Wilcoxon test). Median endothelial cell losses of  $15 \pm 8\%$  ( $P = 0.008$ ) and  $14 \pm 16\%$  ( $P = 0.011$ ) were registered at follow-ups of 1 month and 12 months, respectively. Postoperative complications included chronic intraocular inflammation and superior corectopia.

**Conclusions:** Our procedure appears to be a safe, accurate, stable, and efficacious option for the management of traumatic subluxated cataracts in adults. However, longer-term data are needed to evaluate the corneal endothelium.

RETINA 25:1-1, 2005

---

Subluxated cataracts often need to be managed using advanced surgical techniques. Intracapsular lens extraction has been traditionally performed via a

From the \*Department of Ophthalmology, Croix-Rousse Hospital, University of Lyon I Claude Bernard, Lyon, France; the †Department of Ophthalmology, Inselspital, University of Bern, Bern, Switzerland; and the ‡Department of Ophthalmology, Ed. Herriot Hospital, University of Lyon I Claude Bernard, Lyon, France.

This study received no funding, and the authors had no financial or proprietary interest in it. Laurent Kodjikian had full access to all available data and takes full responsibility for their integrity and for the accuracy of the analysis.

Reprint requests: Laurent Kodjikian, MD, PhD, Department of Ophthalmology, Croix-Rousse Hospital, 103, grande rue de la Croix-Rousse, Lyon 69004, France; e-mail: kodjikian.laurent@wanadoo.fr

limbal incision, but this technique is associated with many complications, including loss of vitreous, retinal detachment, and glaucoma.<sup>1</sup> An alternative method of removal involves simultaneous pars plana lensectomy and vitrectomy.<sup>2–10</sup> However, the intraocular lenses (IOLs) inserted after this procedure have been either open-loop anterior chamber implants or sclerally suture-fixed, posterior chamber ones. The former are known to be associated with a continuous endothelial cell loss,<sup>11,12</sup> whereas sulcus suture fixation carries an increased risk of early postoperative problems, namely, bleeding, decentration, and retinal detachment.<sup>13</sup>

Because no data on the use of such lenses in association with pars plana vitrectomy and ultrasonic lens fragmentation for subluxated cataracts have been reported to our knowledge, we present our preliminary experience with, and the outcome of, combined ultrasonic pars plana phacofragmentation, vitrectomy, and iris fixation of Artisan (OPHTEC BV, The Netherlands) IOLs for adult traumatic subluxated cataracts.

## Patients and Methods

### Patients

Nine eyes of seven consecutive patients (one female and six males) with lens subluxation caused by trauma (ocular contusion injuries in most cases) were included in this prospective, interventional, nonrandomized trial. Patients were included only if extensive zonular damage ( $\geq 180^\circ$ ) with phacodonesis and iridodonesis was present. All eyes underwent combined pars plana phacofragmentation in combination with three-port pars plana vitrectomy and Artisan lens implantation between July 2002 and January 2004. All patients had a cataractous lens.

Surgery was performed consecutively on each patient by the same surgeon (L.K.) using the same technique at the Department of Ophthalmology, the Croix-Rousse Hospital, Claude Bernard University, Lyon, France. A consent form describing the risks and benefits of the procedure was signed by each patient before surgery, in accordance with the Helsinki Declaration.

### Surgical Intervention

Preoperative examination included assessment of complete manifest refraction, determination of best spectacle-corrected visual acuity (BSCVA), slit-lamp and dilated-fundus examination, keratometry, applanation tonometry, measurement of endothelial cell numerical density using a noncontact specular microscope attached to a slit lamp (Topcon-SL7F), determination of corneal thickness, and A-scan biometry.

Surgical intervention was always performed under conditions of peribulbar anesthesia.

The surgical procedure followed a standard protocol. Two scleral entry ports were prepared 3.5 mm posterior to the limbus at the 10- and 2-o'clock positions using a 20-gauge blade. The blade was then reinserted into the lens nucleus at the equator. The tips of a handheld infusion cannula and a fragmentome (phacofragmenter) were driven into the lens until each was visible within the lens substance. Irrigation and fragmentation were then initiated endocapsularly. Infusion of the lens itself permits a blowing up of the

capsular bag, thereby creating a stable space between anterior and posterior lens capsules. The lens cortex was maintained in situ until the nucleus had been completely removed, to stabilize the latter and protect the anterior and posterior lens capsules. This gradual emulsification of the nuclear material avoids the problem of removing large fragments from the lens cavity. Although vitreal material was present within the anterior chamber of some patients, this endocapsular technique permitted the safe and complete removal of the lens, without incurring any risk of vitreal traction before vitrectomy. Consequently, complete pars plana vitrectomy was always performed after removing lens material. For this purpose, the posterior infusion cannula was secured at a third port within the inferotemporal quadrant. Preservation of the lens capsule's integrity until all of the lens material had been removed appeared to be important. We never succeeded in effecting complete emulsification before the posterior capsule broke, with the result that small lens fragments entered the vitreal cavity. These fragments were removed ultrasonically after complete posterior vitrectomy. Perfluorocarbon was never used.

The two superior entry sites were then definitively closed with 7-0 polyglactin 910 sutures. The infusion cannula was kept open to maintain normal intraocular pressure and thereby to facilitate iris fixation of the Artisan lens. After lensectomy and vitrectomy, the peripheral fundus was carefully examined upon scleral indentation, using a three-mirror lens and an operation slit lamp. The pupil was then constricted pharmacologically (1% acetylcholine). A beveled corneal incision of 5.5 mm was effected at the 12-o'clock position, and two corneal paracenteses were then effected at the 9- and 3-o'clock positions. The anterior chamber was opened and filled with a viscoelastic fluid (Healon GV) to maintain its depth. After implantation with the aid of forceps, the Artisan lens (model 205, Artisan aphakia 5/8.5, OPHTEC BV, The Netherlands) was affixed to the iris using a Bonn forceps. At the end of surgery, slit iridotomy was performed at the 12-o'clock position, the viscoelastic material was carefully removed, and the corneal wound was sutured with 10.0 Ethilon. The infusion cannula was withdrawn, and the scleral entry site and conjunctiva were closed with 7-0 polyglactin 910 sutures (Fig. 1).

Follow-up examinations were performed (by L.K.) on the day after surgery, at 1 week, at 1 month, every 6 months during the following 2 years, and then annually. For inclusion in this study, a minimum follow-up of 6 months was required. To maximize the inclusion number, patients were given fixed appointment dates in writing. Postoperative examinations included assessment of manifest refraction and BSCVA,

AQ: 1

F1

Table 1. Preoperative Patient Characteristics

Patient Eye	Age (y)	Sex	Previous Trauma-to-Surgery Interval (mo)	Type of Trauma	Nuclear Sclerosis (Grade)	Subluxation Location	Zonular Damage (°)	Phacodonesis and Iridodonesis	Intracameral Vitreous Prolapse	Intraocular Hypertension	Artisan Lens Power (D)
1	68	M	4	Contusion	1	Inferior	#210	Yes	Yes	Yes	15
1	68	M	4	Contusion	1	Inferior	>300	Yes	Yes	Yes	16
2	46	M	1	Contusion	2	Superonasal Posterior	#270	Yes	Yes	Yes	20
3	66	M	180	Contusion	2	superotemporal	#210	Yes	No	No	16
4	80	F	60	Contusion	2	Superotemporal	#210	Yes	No	No	15
4	80	F	60	Contusion	2	Superonasal	#180	Yes	Yes	No	17
5	74	M	168	Contusion	1	Superotemporal	#270	Yes	Yes	No	20
6	66	M	360	Penetrating laceration	2	Inferonasal	>300	Yes	Yes	Yes	17
7	70	M	5	Contusion	3	Inferotemporal	#180	Yes	No	No	21
Median (range)	68 (46-80)	—	60 (1-360)	—	2 (1-3)	—	210 (180 to >300)	Yes, 100%	Yes, 67%	Yes, 44%	17 (15-21)

D, diopter.

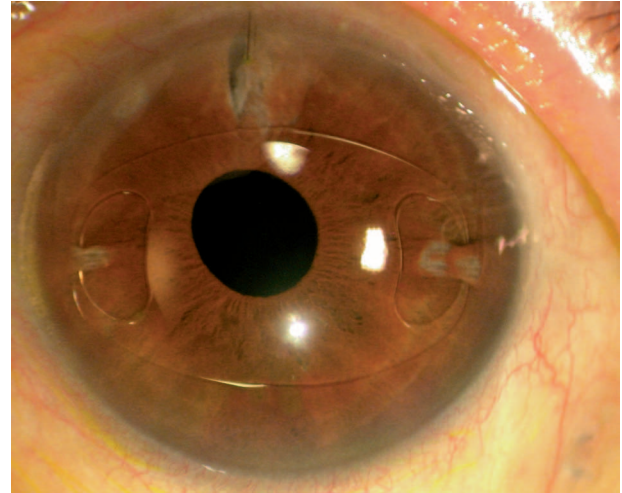


Fig. 1. Photograph of the left eye of Patient 4 6 months after surgery that shows a well-centered Artisan intraocular lens, a superior iridotomy, and the inferotemporal scar of the sclerotomy.

slit-lamp biomicroscopy, applanation tonometry, and inspection of the dilated fundus. Postoperative specular microscopy and pachymetry were regularly performed after the first month. All data were collected prospectively for each patient during the follow-up examinations, as is customary for cataract patients in our department.

Statistical Methods

The statistical analysis was performed using SPSS (SPSS for Windows, version 12.0.1; SPSS, Inc., Chicago, IL). Each of a patient’s eyes was analyzed separately. To evaluate visual acuity results, Snellen fractions were converted into logarithms of the minimum angle of resolution (logMAR). The Wilcoxon signed rank test, which detects differences in the distributions of two related variables, was used to compare visual acuity, endothelial cell counts, and pachymetry results with time. Differences between two corresponding variables were considered to be statistically significant if P was <0.05.

Results

Patient Characteristics

Data relating to patient characteristics are presented in Table 1. Patient age at the time of surgery ranged from 46 years to 80 years (median, 68 years). Nine eyes (six right eyes and three left eyes) of seven consecutive patients (one female and six males) were included in this interventional, prospective case series. Lens opacity was graded as mild in 3 eyes (33%), moderate in 5 (56%), and marked in 1 (11%). No clear

Table 2. Surgical Results: Preoperative and Postoperative VA and Refraction, Duration of Surgery, Postoperative Complications, and Follow-up

Patient	Eye	Preoperative VA (logMAR)	1-y VA (logMAR)	Preoperative SE Refraction (D)	1-y SE Refraction (D)	Duration of Surgery (min)	Postoperative Complication(s)	Postoperative Follow-up (mo)
1	1	20/400 (1.3)	20/25 (0.1)	0	+1	75	—	18
1	2	20/400 (1.3)	20/30 (0.2)	0	0	50	—	17
2	3	CF (1.3)	20/20 (0)	0	-1.25	85	—	14
3	4	20/100 (0.7)	20/25 (0.1)	-4.25	-1.50	105	—	8
4	5	20/100 (0.7)	20/25 (0.1)	-8.50	0	90	Preoperative ERM with CME*	10
4	6	20/100 (0.7)	20/30 (0.2)	-7.50	-1.50	70	Preoperative ERM with CME*	9
5	7	20/125 (0.8)	20/30 (0.2)	0	0	50	Chronic intraocular inflammation	10
6	8	20/400 (1.3)	20/25 (0.1)	-2.0	-0.50	60	—	13
7	9	20/200 (1)	20/25 (0.1)	0	-1.25	60	Mild superior corectopia	12
Mean ± SD (range)	—	20/200 (1; 0.7–1.3)	20/25 (0.1; 0–0.2)	-2.47 ± 3.46 (0 to -8.50)	-0.50 ± 0.87 (+1 to -1.50)	72 (50–105)	—	12 (8–18)

\* Patient 4 (Eyes 5 and 6) was diagnosed preoperatively as having a bilateral epiretinal membrane, which was complicated by mild cystoid macular edema. This condition was therefore not regarded as a complication of the surgical procedure.

VA, visual acuity; logMAR, logarithm of the minimum angle of resolution; SE, spherical equivalent; D, diopter; CF, counting fingers; ERM, epiretinal membrane; CME, cystoid macular edema.

lenses were extracted in this series. All patients had a history of traumatic subluxation of the lens. The traumatic incident had occurred 1 month to 30 years (median, 5 years) before surgery. The types of trauma are described in Table 1. The subluxation was bilateral in 2 (28.6%) of the 7 patients. The location of each subluxated lens and the zonular damage are also indicated in Table 1. These were readily identifiable when the pupil was dilated. In six of nine eyes, vitreous was detected in the anterior chamber, and four of nine eyes were hypertensive preoperatively. This latter condition was always controlled by local treatment with a  $\beta$ -blocker. After surgery, intraocular pressure normalized without medical treatment in two eyes and with the aid of local  $\beta$ -blockers in both eyes of Patient 1. In all eyes, peribulbar anesthesia was administered, because the median axial length in these individuals was 23.4 mm (range, 22.3–24.9 mm). The average duration of surgery was 72 minutes (range, 50–105 minutes). The median length of follow-up was 12 months (range, 8–18 months; mean, 12.4 months) (Table 2). Follow-up data collected at the final examination of each patient (range, 8–18 months) are therefore arbitrarily referred to as the “1-year” results.

#### Refraction and Visual Acuity

Data pertaining to pre- and postoperative refractive errors and to visual acuities are presented in Table 2. The biometry-predicted spherical equivalent ranged from 0 diopter (D) to -0.7 D (mean,  $-0.32 \pm 0.23$  D). Hence, the mean difference between the attempted and the achieved spherical equivalent correction at 1 year was only  $-0.24 \pm 0.88$  D (range, 0–1.4 D). One year after surgery, the refraction lay within  $\pm 0.5$  D of the desired emmetropia in 4 eyes (57%) and within  $\pm 1.5$  D in all cases (100%). The postoperative spherical equivalent refraction was stable between 1 month and 12 months. The mean preoperative cylinder was  $0.17 \pm 0.50$  D (range, 0–1.5 D), whereas the mean postoperative cylinder required for correction was  $0.75 \pm 0.67$  D (range, 0–1.75 D). Consequently, a minor average astigmatism of  $0.58 \pm 0.99$  D (range, 0–1.75 D) was induced.

All patients presented with a preoperative visual acuity equal to or less than 20/100. One year after surgery, a visual improvement of at least 20/30 was observed in all patients ( $P = 0.007$ , Wilcoxon test). On average, BSCVA improved by 9 Snellen lines, with 1 Snellen line corresponding to 0.1 logMAR.

#### Corneal Endothelium

On the basis of preoperative counts, median endothelial cell losses of  $15 \pm 8\%$  ( $P = 0.008$ ) and  $14 \pm 16\%$  ( $P = 0.011$ ) were registered 1 month and 12

Table 3. Changes in Corneal Characteristics With Time

Patient	Eye	Preoperative Endothelial Cell Density (cells/mm <sup>2</sup> )	1-mo Endothelial Cell Density (cells/mm <sup>2</sup> )	1-mo Endothelial Cell Loss (%)	1-y Endothelial Cell Density (cells/mm <sup>2</sup> )	1-y Endothelial Cell Loss (%)	Preoperative Pachymetry (μm)	1-mo Pachymetry (μm)	1-y Pachymetry (μm)
1	1	2,699	2,290	15.15	2,299	14.82	524	523	527
1	2	2,816	2,409	14.45	2,416	14.20	523	525	520
2	3	3,276	2,333	28.79	1,771	45.94	569	620	577
3	4	2,769	2,478	10.51	2,485	10.26	565	576	565
4	5	2,900	2,397	17.34	2,665	8.10	516	551	501
4	6	2,800	2,263	19.18	2,385	14.82	524	535	510
5	7	1,744	1,723	1.20	1,750	0	558	600	573
6	8	1,719	1,374	20.07	960	44.15	575	614	572
7	9	2,219	2,019	9.01	2,000	9.87	484	485	490
Median ± SD (range)	—	2,769 ± 537 (1,719–3,276)	2,290 ± 371 (1,374–2478)	15 ± 8 (1–29)	2,299 ± 527 (960–2,665)	14 ± 16 (0–46)	524 ± 31 (484–575)	551 ± 46 (485–620)	527 ± 35 (490–577)

months, respectively, after surgery (Tables 3 and 4). The loss of endothelial cells from the fellow unoperated eyes (excluding Patients 1 and 4) was 6.0 ± 6.7% (range, 0–16%) after a median follow-up of 12 months. Corneal thickness differed significantly from the preoperative value to that at 1 month (median increase, 3.6%) but not at 1 year (Table 4).

Two patients (Patients 2 and 6) had unexpectedly high endothelial cell loss after 1 year (44% and 46%, respectively; Table 3). Their histories are remarkable in that the underlying ocular trauma was very severe in both. Patient 2 had suffered a severe ocular contusion, with prolapse of the vitreous and ocular hypertension 1 month before surgery. Patient 6 had incurred a severe corneal-perforating injury, with a traumatic iris defect, 30 years before surgery. In this latter individual, vitreous was present within the anterior chamber, and the eye was consequently hypertensive. Hence, this patient underwent iridoplasty. Patients 2 and 6 were the only ones to manifest a continuing decrease in endothelial cell counts between 1 month and 12 months (Table 3). If they were excluded, the median endothelial cell loss 1 year after surgery was of 10 ± 5% (range, 0–15%).

*Complications*

Intra- or postoperative phacofragmentation- or lens fixation-associated complications were not encountered in any of the patients (Table 2)—i.e., there were no occurrences of lens decentration, iridolenticular problems, distortion, ovalization of the pupil, rotation of the lens, retinal detachment, corneoendothelial decompensation, or acute endophthalmitis. However, one eye (Eye 7) presented with intraocular inflammation 15 months after surgery. At this time, the patient had a chronically red eye. A few white deposits were observed on the lens surface, and a moderate flare was present; however, retrocorneal precipitates or hypopyon was absent. Because the patient declined anterior chamber puncture, we were unable to exclude the possibility of chronic endophthalmitis. Drops of dexamethasone administered once a day eradicated all clinical manifestations except the lens precipitates. Patient 7 (Eye 9) presented with postoperative superior corectopia due to trapping of the iris in the corneal wound, but this was not associated with the Artisan lens or with its fixation. Preoperatively, Patient 4

Table 4. Results (P Values) of the Wilcoxon Test for Endothelial Cell Density and Corneal Pachymetry

P (Wilcoxon Test)	Initial Endothelial Cell Density	1-mo Endothelial Cell Density	1-y Endothelial Cell Density	Initial Pachymetry	1-mo Pachymetry	1-y Pachymetry
Initial endothelial cell density	—	0.008	0.011	—	—	—
1-mo endothelial cell density	0.008	—	0.859	—	—	—
1-y endothelial cell density	0.011	0.859	—	—	—	—
Initial pachymetry	—	—	—	—	0.013	0.944
1-mo pachymetry	—	—	—	0.013	—	0.024
1-y pachymetry	—	—	—	0.944	0.024	—

(Eyes 5 and 6) had manifested a bilateral epiretinal membrane, which was complicated by mild cystoid macular edema. Consequently, this condition was not considered as a complication of the procedure. At the time of this writing, this bilateral macular membrane was still present, but it did not affect visual function.

### Discussion

The surgical management of a subluxated lens is always challenging, and some controversies remain unsolved. Removal of a subluxated lens is indicated if the vision is affected—i.e., if the cataract is substantial, if the visual disturbance stems from lens dislocation from the optical axis, or if complications, such as secondary glaucoma or retinal detachment, occur. In our cohort of patients, the median interval between the traumatic event and lens removal was 60 months (range, 1–360 months; Table 1). Most reports have not stated this interval,<sup>2,3</sup> but when given,<sup>4,8</sup> it has been shorter than ours. Variations in this parameter reflect the decision of the managing ophthalmologist, the patient's wishes and expectations, and the severity of the injury. After the lens has been removed, the most critical decision relates to the optical rehabilitation of the aphakic eye. Combined procedures, such as simultaneous cataract extraction, pars plana vitrectomy, and IOL implantation, have become common practice. However, to the best of our knowledge, information on the use of an Artisan IOL in this situation has not been reported hitherto. Literature reports relating to subluxated cataracts are limited.<sup>2–10</sup> Our study has the advantage of being prospective in design and of including an assessment of changes in the numerical density of corneal endothelial cells. However, its obvious limitation is the relatively small size of the patient cohort and the limited follow-up.

Potential disadvantages of combining conventional cataract surgery with pars plana vitrectomy, such as loss of corneal transparency, instability of the cataract wound during globe manipulation, and bleeding from anterior structures,<sup>14</sup> were not encountered in our series. On the contrary, the combined pars plana surgical approach permitted a closed ocular system, a limited reduction in endothelial cell loss,<sup>15</sup> minimal iris trauma, and, above all, a good intraoperative overview of vitreal and retinal structures. Furthermore, this surgical approach affords the possibility of repairing an unstable retina if such is revealed during surgery.

For children with a clear subluxated lens, pars plana lensectomy can be performed using a vitrectomy instrument, but for adults with a cataractous lens, ultrasonic fragmentation is required. The pars plana phacofragmentation technique permits removal of all lens

fragments, irrespective of their location and hardness. In our hands, this undertaking did not complicate the implantation of an Artisan lens in any instance. In contrast to sulcus-sutured IOLs, Artisan lenses are more easily implanted and better tolerated, with low incidences of early postoperative bleeding, retinal detachment, endophthalmitis, decentration, or tilting and no inadvertent endothelial cell loss with time after accurate placement.<sup>2,4,13,16,17</sup> For the latter reason, Artisan lenses are also preferable to open-loop anterior chamber IOLs (i.e., open C-loop Simcoe-style and four-point-fixation Kelman-style IOLs).<sup>11,12,16,17</sup>

A general problem associated with all IOLs is that only a moderately accurate refraction is achieved postoperatively. The Artisan aphakia lenses are manufactured from +2 D to a maximum of +30 D, with half-diopter increments from +14.5 D to +24.5 D. In the present series, all eyes were fitted with lenses that would have ideally corrected their refractive error, given the highly predictable results of positioning IOLs directly on the iris surface, in contrast to fixation via sutures. The mean spherical equivalent remained stable with time—i.e., within 0.5 D during the 12-month follow-up. Although the follow-up was limited in our series, the findings nevertheless confirm the well-known refractive stability of the Artisan lenses with time.<sup>16,18</sup> Furthermore, despite the necessity of producing a 5.5-mm-long corneal incision, a relevant astigmatism was not induced. This circumstance partially explains why we experienced no major difficulties in predicting the refractive outcome, because the mean spherical targeting error (the difference between the spherical equivalent of the postoperative refraction and the biometry-predicted refraction) was only -0.24 D for the entire group. Furthermore, the safety of the corneal endothelium was only minimally endangered during the implantation of the Artisan lenses, which accords with literature findings.<sup>16</sup> The mean postoperative BSCVA at each successive examination was better than the mean preoperative BSCVA, with a mean gain of 9 Snellen lines. As expected, this finding indicates that the Artisan lenses improve the BSCVA of patients with subluxated cataracts. The combined procedure described in the present study is thus deemed to be a safe, stable, efficacious, and predictable method for the treatment of traumatic subluxated cataracts in adults.

Artisan lenses maintain a relatively favorable position in the eye. As long as the anterior chamber is sufficiently deep, which is almost always the case in pseudophakic eyes, the lens is kept at a healthy distance from the corneal endothelium. Two recent prospective, multicenter clinical studies confirmed the safety of this type of implant in phakic eyes.<sup>16,17</sup> The

mean change in endothelial cell numerical density was approximately 2% 1 year after implantation, and this loss was not statistically significant. Nevertheless, 9% of the eyes had a 10% decrease in endothelial cell numerical density after 1 year.<sup>17</sup> Interestingly, greater postoperative endothelial cell losses were correlated with higher preoperative counts.<sup>17</sup> In our series, Patient 2, who incurred the highest cell loss (46% at 1 year), also had the highest preoperative cell count (3,276 cells/mm<sup>2</sup>). The favorable data concerning endothelial safety were recently confirmed in a prospective trial using Artisan lenses to correct hypermetropia in phakic eyes.<sup>18</sup> In principle, endothelial cell loss may be attributable to the surgical process, to the IOL, or to postoperative degeneration. In our study, a median endothelial cell loss of 14% was registered 1 year after surgery, which accords with the results published for phakic eyes and the phacoemulsification procedure. The five unoperated fellow eyes manifested a high natural cell loss (6% at 1 year) compared with the usual literature values ( $0.6 \pm 0.5\%$  after 1 year).<sup>19</sup> However, several studies have reported endothelial cell losses ranging from 4% to 15% after phacoemulsification performed by experienced surgeons.<sup>20–22</sup> In addition, in a recent study, a 1-year endothelial cell loss of 10.5% was reported to occur after phacoemulsification.<sup>23</sup> In this latter study, one preoperative condition that was associated with a particularly high cell loss ( $\geq 15\%$  at 1 year), and which corresponded to that occurring in all of our patients, was an open communication between anterior and posterior segments, which necessitated removal of the vitreous during surgery. After the first postoperative month, the numerical density of endothelial cells stabilized, with only insignificant losses being encountered up to the end of the first year ( $P = 0.859$ ), thereby confirming the high endothelial safety of a well-positioned Artisan lens. As reported in the literature, surgical trauma is the main cause of endothelial cell loss.<sup>15</sup> In contrast to the situation occurring when Artisan lenses are implanted in phakic eyes,<sup>16,17</sup> endothelial cell loss after cataract extraction has been shown to continue for at least 2 years.<sup>24–26</sup>

One could imagine that two surgical interventions, with the IOL being implanted on a second occasion, would be less traumatic for the corneal endothelium, but this is probably not the case. In a recent study, the long-term changes in endothelial cell numerical density were investigated after the primary or secondary implantation of anterior chamber IOLs in association with cataract surgery that was complicated by posterior capsule rupture. After a follow-up of 5.7 years, endothelial cell loss was greater in aphakic patients who had undergone secondary (mean,  $23.7 \pm 8.3\%$ )

rather than primary implantation (mean,  $13.3 \pm 6.7\%$ ;  $P < 0.01$ ).<sup>15</sup> These findings confirm the role played by double surgical trauma in reducing endothelial cell density. Moreover, a single surgical intervention, even if it involves several procedures, is more acceptable to the patient and imposes less of a financial burden on health insurance companies. In our study, corneal thickness, which increased after 1 month, had returned to preoperative values by the first year, which confirms that the endothelium had recovered its functionality.

We have encountered no functionally relevant postoperative complications in association with our technique. The absence of posterior segment complications is indeed hardly surprising. Combined pars plana lensectomy and vitrectomy permits lens removal within a closed ocular system, thereby preventing distortions of the globe and limiting vitreal traction. The technique permits excellent intraoperative visualization of the posterior segment, including the far peripheral retina, as well as easy access to any intraoperatively detected retinal problems. Moreover, Artisan lenses do not restrict pupillary dilatation, which facilitates good postoperative control of the peripheral retina. Although some experience is necessary to accurately center an Artisan lens, suboptimal positioning can always be corrected postoperatively (which was never necessary in our series), because the fixation is reversible. No functionally relevant postoperative complications were encountered. However, as aforementioned, one patient presented with a chronically red eye, which was associated with a few white deposits on the lens surface. It is important to note that the lenticular deposits were not pigmented. Hence, they were not attributable either to surgical trauma (iris contact or pigment liberation during iridotomy) or to postoperative lens–iris contact.<sup>18</sup>

As outlined above, the combined approach is easily and speedily performed in trained hands and appears to be as safe for the corneal endothelium as phacoemulsification. Primary insertion of an Artisan lens is less traumatic for the corneal endothelium than secondary implantation. Moreover, secondary implantation would be more challenging, owing to the lack of vitreous support after vitrectomy and the consequent ocular hypotensive state. The excellent postoperative visual acuity and refraction results achieved in our series demonstrate the efficacy, predictability, and stability of the Artisan lens for the correction of aphakia after subluxated cataract surgery. However, we acknowledge that this study constitutes a preliminary report and that patients must be followed up for longer times to safeguard against the possibility of late-occurring complications.

**Key words:** Artisan lens, phacoemulsification, subluxated cataract, subluxation, trauma, vitrectomy.

### References

- Behki R, Noel L, Clarke W. Limbal lensectomy in the management of ectopia lentis in children. *Arch Ophthalmol* 1990; 108:809–811.
- Kazemi S, Wirostko W, Sinha S, et al. Combined pars plana lensectomy-vitrectomy with open-loop flexible anterior chamber intraocular lens (AC IOL) implantation for subluxated lenses. *Trans Am Ophthalmol Soc* 2000;98:247–251.
- Lai C, Kou H, Lai I, et al. Lens subluxation: 10-years' experience at Chang Gung Memorial Hospital, Kaohsiung. *Chang Gung Med* 2001;24:786–792.
- Chaudhry N, Belfort A, Flynn HJ, et al. Combined lensectomy, vitrectomy and scleral fixation of intraocular lens implant after closed-globe injury. *Ophthalmic Surg Lasers* 1999;30:375–381.
- Malinowski S, Mieler W, Koenig S, et al. Combined pars plana vitrectomy-lensectomy and open-loop anterior chamber lens implantation. *Ophthalmology* 1995;102:211–216.
- Girard L, Canizales R, Esnaola N, Rand W. Subluxated (ectopic) lenses in adults. Long-term results of pars plana lensectomy-vitrectomy by ultrasonic fragmentation with and without a phacoprosthesis. *Ophthalmology* 1990;97:462–465.
- Peyman G, Raichand M, Goldberg M, Ritacca D. Management of subluxated and dislocated lenses with the vitrophage. *Br J Ophthalmol* 1979;63:771–778.
- Greven C, Collins A, Slusher M, Weaver R. Visual results, prognostic indicators, and posterior segment findings following surgery for cataract/lens subluxation-dislocation secondary to ocular contusion injuries. *Retina* 2002;22:575–580.
- Benson W, Blankenship G, Machermer R. Pars plana lens removal with vitrectomy. *Am J Ophthalmol* 1977;84:150–152.
- Loo A, Lai J, Tham C, Lam D. Traumatic subluxation causing variable position of the crystalline lens. *J Cataract Refract Surg* 2002;28:1077–1079.
- Stur M. Long-term changes of the corneal endothelium following intracapsular cataract extraction with implantation of open-loop anterior chamber lenses. *Acta Ophthalmol (Copenh)* 1988;66:678–686.
- Sawada T, Kimura W, Kimura T, et al. Long-term follow-up of primary anterior chamber intraocular lens implantation. *J Cataract Refract Surg* 1998;24:1515–1520.
- Gabor R. Artisan IOL after phacoemulsification in subluxated lenses. *J Cataract Refract Surg* 2002;28:2064.
- Scharwey K, Pavlovic S, Jacobi K. Combined clear corneal phacoemulsification, vitreoretinal surgery, and intraocular lens implantation. *J Cataract Refract Surg* 1999;25:693–698.
- Ravalico G, Botteri E, Baccara F. Long-term endothelial changes after implantation of anterior chamber intraocular lenses in cataract surgery. *J Cataract Refract Surg* 2003;29:1918–1923.
- Budo C, Hessloehl J, Izak M, et al. Multicenter study of the Artisan phakic intraocular lens. *J Cataract Refract Surg* 2000; 26:1163–1171.
- Pop M, Payette Y. Initial results of endothelial cell counts after Artisan lens for phakic eyes: an evaluation of the United States Food and Drug Administration Ophtec Study. *Ophthalmology* 2004;111:309–317.
- Saxena R, Landesz M, Noordzij B, Luyten G. Three-year follow-up of the Artisan phakic intraocular lens for hypermetropia. *Ophthalmology* 2003;110:1391–1395.
- Bourne W, Nelson L, Hodge D. Central corneal endothelial cell changes over a ten-year period. *Invest Ophthalmol Vis Sci* 1997;38:779–782.
- O'Brien P, Fitzpatrick P, Kilmartin D, Beatty S. Risk factors for endothelial cell loss after phacoemulsification surgery by a junior resident. *J Cataract Refract Surg* 2004;30:839–843.
- Morikubo S, Takamura Y, Kubo E, et al. Corneal changes after small-incision cataract surgery in patients with diabetes mellitus. *Arch Ophthalmol* 2004;122:966–969.
- Werblin T. Long-term endothelial cell loss following phacoemulsification: model for evaluating endothelial damage after intraocular surgery. *Refract Corneal Surg* 1993;9:29–35.
- Bourne R, Minassian D, Dart J, et al. Effect of cataract surgery on the corneal endothelium: modern phacoemulsification compared with extracapsular cataract surgery. *Ophthalmology* 2004;111:679–685.
- Liesegang T, Bourne W, Ilstrup D. Short- and long-term endothelial cell loss associated with cataract extraction and intraocular lens implantation. *Am J Ophthalmol* 1984;97:32–39.
- Matsuda M, Suda T, Manabe R. Serial alterations in endothelial cell shape and pattern after intraocular surgery. *Am J Ophthalmol* 1984;98:313–319.
- Cheng H, Jacobs P, McPherson K, Noble M. Precision of cell density estimates and endothelial cell loss with age. *Arch Ophthalmol* 1985;103:1478–1481.



## AUTHOR QUERIES

### AUTHOR PLEASE ANSWER ALL QUERIES

1

AQ1: AUTHOR— Please provide manufacturer (with its location) of Healon GV and make sure that all other manufacturers (with their locations) are provided for all trade names used throughout the article.

AQ2: AUTHOR— In table 1, please confirm use of “intracameral” and clarify use of “#” in Zonular Damage column.

---