

# Scanning Electron Microscopic Characteristics of Phakic Intraocular Lenses

Thomas Kohnen, MD,<sup>1</sup> Martin Baumeister, MD,<sup>1</sup> Gerd Magdowski, BS<sup>2</sup>

**Objective:** To analyze the surface quality of new generation phakic intraocular lenses (IOLs).

**Design:** Experimental materials study.

**Materials:** Three different new generation phakic IOLs: angle-fixated anterior chamber lens Chiron Vision NuVita MA20 (polymethylmethacrylate [PMMA]), iris-fixated anterior chamber lens Ophtec Artisan Iris-Claw (PMMA), posterior chamber lens Staar ICM (polymer from porcine collagen and 2-hydroxyethyl methacrylate [HEMA]).

**Methods:** Representative samples of three different phakic IOLs underwent surface and edge-finish examination with light microscopy (LM). The phakic IOLs were then examined by use of scanning electron microscopy (SEM), and particular attention was given to optic surface quality, edge finish, haptic, and optic/haptic junction.

**Results:** In all IOLs the LM examination showed a smooth and homogeneous surface. No irregularities, particularly at the optic front and back surface, optic edge, haptic, and the optic/haptic junctions, were detected by SEM. One exception was a minor surface roughness at the claws of an Artisan iris-fixated anterior chamber IOL.

**Conclusions:** Phakic IOLs are implanted either in the anterior or posterior chamber of healthy eyes, and high standards for their surface quality are required. The evaluation of surface properties with LM and SEM did not reveal any defects that contraindicate the implantation of phakic IOLs. *Ophthalmology* 2000;107:934–939 © 2000 by the American Academy of Ophthalmology.

Incisional (e.g., radial and astigmatic keratotomy) and laser surgery (e.g., excimer photorefractive keratectomy or laser in situ keratomileusis) of the cornea have become the primary methods to correct refractive errors of the human eye. These procedures are all performed by altering corneal tissues. Recently, the implantation of phakic intraocular lenses (IOLs) has been shown to be an alternative for the correction of refractive errors. Several potential advantages have been ascribed to the use of phakic intraocular lenses for the correction of refractive errors, including excellent refractive accuracy, preservation of accommodation, compatibility with procedures already established in cataract surgery and aphakic IOL implantation, correction of higher levels of myopic and hyperopic refractive errors, and reversibility.<sup>1–3</sup>

Because refractive IOLs are implanted in healthy phakic

eyes—mainly of young patients—the procedure requires not only a skilled and experienced surgeon but also implants that provide long-term acceptance and a minimal risk of intraocular inflammation. Previous reports have shown that the acceptance of intraocular implants is greatly influenced by the regularity of the surface.<sup>4–6</sup> Most IOLs that have been implanted until today are made of polymethylmethacrylate (PMMA), a material that is tolerated by the eye over a long time and has been presumed to be almost biologically inert. However, publications have shown that PMMA can give rise to an inflammatory response.<sup>7–10</sup> Despite the remarkable success rate of cataract and IOL surgery, sight-threatening complications develop in pseudophakic eyes.<sup>11,12</sup> Many of these complications are caused by intraocular inflammation that is precipitated or exacerbated by the presence of the IOL. Partially, this inflammation results from interaction between biomaterials and tissues or foreign body reaction to biomaterials (biocompatibility).<sup>10,13</sup> An IOL is able to stimulate a marked inflammatory response. For example, complement is activated, protein and cells leak from dilated uveal vessels and attach to the IOL surface, and synechiae form.<sup>7,9,14–16</sup>

The purpose of this study was to evaluate the surface quality of three different new-generation phakic IOLs.

## Materials and Methods

Three different types of phakic IOLs (all one-piece models with different haptic design) were examined in this study (Table 1): an angle-fixated anterior chamber lens Chiron Vision NuVita MA20 (PMMA), three samples with a refractive power of –15.0 diopters (D) and an optic diameter of 5.0 mm), an iris-claw lens Ophtec Artisan, Groningen, The Netherlands (PMMA, two samples with a

Originally received April 30, 1999.

Accepted: February 9, 2000.

Manuscript no. 99209.

<sup>1</sup>Department of Ophthalmology, Johann Wolfgang Goethe-University, Frankfurt am Main, Germany.

<sup>2</sup>Institute of Anatomy and Cellular Biology, University of Giessen, Giessen, Germany.

Presented in part at the Symposium of the International Intra-Ocular Implant Club (IIIC), Tenerife, Spain, February 1999, at the Annual Meeting of the German Society of Intraocular Lens Implantation and Refractive Surgery (DGII), Frankfurt, Germany, March 1999, and at the Annual Meeting of the South African Society of Cataract and Refractive Surgery (SASCRS), Durban, South Africa, August 1999.

Dr. Kohnen is a consultant for scientific questions to Bausch & Lomb, Inc. but has no financial or proprietary interest in any of the instrumentation or devices used in this study.

Reprint requests to Thomas Kohnen, MD, Johann Wolfgang Goethe-University, Department of Ophthalmology, Theodor-Stern-Kai 7, 60590 Frankfurt am Main, Germany.

Table 1. Characteristics of Phakic Intraocular Lenses Examined in this Study

Type	Design	Material	Total Diameter (mm)	Optic Diameter (mm)	Power Range (D)	Refractive Index
Chiron Vision NuVita MA 20	One-piece, anterior chamber, angle fixated	PMMA	12.0, 12.5, 13.0, 13.5	5.0	-7.0 to -20.0	1.490
Ophtec Artisan	One-piece, anterior chamber, iris claw	PMMA	8.5	5.0	Dioptic steps: 1.0 -3.0 to -23.5 +1.0 to +12.0	1.490
				6.0	-3.0 to -15.5 +1.0 to +12.0 Dioptic steps: 0.5	
Staar ICL	One-piece, plate haptic, posterior chamber, sulcus fixated	Collagen/HEMA-polymer	11.5, 12.0, 12.5, 13.0	4.5, 5.0, 5.5	-3.0 to -20.0 +3.0 to +17.0  Dioptic steps: 0.5	1.453

Steps = the IOL power increases in 0.5 or 1 diopter steps.  
HEMA = 2-hydroxyethyl methacrylate; PMMA = polymethylmethacrylate

refractive power of -15.0 D and an optic diameter of 5.0 mm and two samples with a refractive power of -14.0 D and an optic diameter of 6.0 mm), and a posterior chamber lens Staar ICL, Staar Surgical, Nidau, Switzerland (Collamer, a copolymer of porcine collagen and 2-hydroxyethyl methacrylate [HEMA], two samples with a refractive power of -21.0 D and one with a power of -19.0 D, all three with an optic diameter of 5.5 mm). The IOLs of each design were received as sterile implantation samples from the manufacturer.

All IOLs were first inspected with a dissecting microscope (Stereolupe Wild, Heerbrugg, Switzerland) and were then processed for scanning electron microscopy (SEM). The IOLs were sputter-coated with gold for 6 minutes at 5 mA in a Balser SCD 040 instrument (Bal-Tec AG, Walluf, Germany). SEM was performed with a Philips PSEM 500 machine at high voltage (>1000 volt) (Philips, Industrial Electronics GmbH, Hamburg, Germany). Photographs were taken with a Steinheil M20 Oscillophot camera (Steinheil Lear Siegler AG, Ismaning-München, Germany) at 5.8 to 175 times magnification. Special attention was given to optic surface quality, edge finish, haptic, and optic/haptic junction.

## Results

Light microscopy did not reveal any surface irregularities on gross examination. The results of the SEM findings are summarized in Table 2. In particular, the Chiron Vision NuVita MA20 angle-fixated anterior chamber phakic IOL demonstrated a smooth and homogenous front and back optic surface in all three samples (Fig 1A). The optic itself showed a meniscus shape and the optic edge

a reduced thickness in higher magnification. At the junction between optic and haptic and at the haptic itself no irregularities could be detected (Fig 1B).

Both front and back examination of the Ophtec Artisan iris-claw phakic IOL with a 5.0-mm optic diameter showed a regular surface and good finish (Fig 2A). The haptics and the optic/haptic junction (Fig 2B) were smooth and regularly shaped. The haptic ends, which are referred to as the "claw" of the IOL, showed sharp edges and tiny cracks in one sample (Fig 2C).

The Ophtec Artisan IOL with a 6.0-mm optic diameter demonstrated excellent optic finish and front and back optic surfaces as well (Fig 3A). In higher magnification, no molding flash or empty spaces at the optic edges were visible (Fig 3B). In this model, there were no irregularities or sharp edges detectable at the optic/haptic junction and the haptic ends (Fig 3C).

The Staar ICL posterior chamber phakic IOL demonstrated a good overall finish in front and back views (Fig 4A). Even high magnification of the front and back optic side of this IOL model did not reveal any irregularities. At the edges of the IOL, no molding flash was detectable (Fig 4B). The positioning holes in the haptic foot plates and near the optic demonstrated a fine, regular finish without any surplus material (Fig 4B, C).

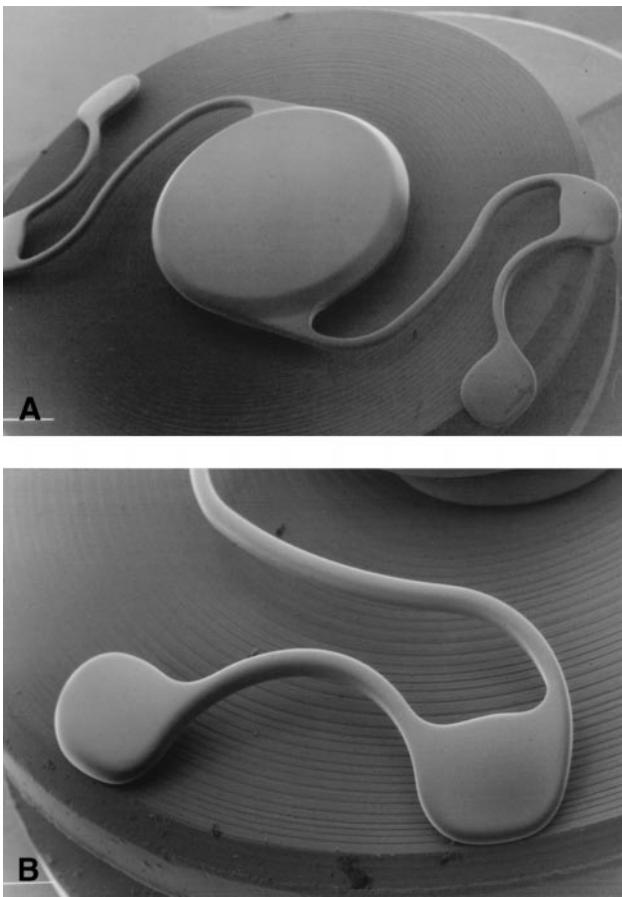
## Discussion

Phakic intraocular lenses have become a possible alternative to corneal surgery for the correction of refractive errors.

Table 2. Surface Quality of the Examined Phakic IOLs

IOL type	Optic Front Surface	Optic Back Surface	Optic Margin	Haptic/Optic Junction	Positioning Holes	Haptic
Chiron Vision NuVita MA 20	✓	✓	✓	✓	-	✓
Ophtec Artisan (5-mm optic diameter)	✓	✓	✓	✓	-	ø, ¥
Ophtec Artisan (6-mm optic diameter)	✓	✓	✓	✓	-	✓
Staar ICL	✓	✓	✓	✓	✓	✓


✓ = smooth surface; ø = irregular surface; ¥ = sharp edge.



**Figure 1.** SEMs of the Chiron NuVita MA20 angle-fixated anterior chamber phakic intraocular lens. **A**, Overview shows a smooth and homogenous surface (original magnification,  $\times 5.8$ ). **B**, Haptic reveals no irregularities and shows an excellent surface finish (original magnification,  $\times 45$ ).

Because several investigators have already demonstrated the importance of surface properties for IOL safety in pseudophakic eyes, particularly for long-term biocompatibility of an implant,<sup>5,6,17</sup> it seems even more important to prove these properties for phakic IOLs because these lenses are implanted into healthy eyes. Rough and irregular surfaces and sharp edges could damage the delicate intraocular tissues<sup>5</sup> and could lead to disastrous consequences. The quality of modern IOLs has been perfected during the last two decades<sup>4,5,8,18-21</sup> and new IOLs, especially IOLs implanted in phakic eyes, should match these standards.



In a previous study we evaluated the surface properties of foldable silicone elastomer IOLs<sup>19</sup> and found generally acceptable surface properties. In another study new foldable acrylate/methacrylate polymer IOLs did show uniformly excellent surface quality with no surplus material or molding flash.<sup>21</sup> Omar et al<sup>20</sup> also demonstrated adequate lens finish in small-incision IOLs made of PMMA, silicone, and acrylic. However, they found small irregularities and molding flash in four of the five foldable IOLs examined. These studies demonstrated the importance of quality control for new IOLs. In this study we evaluated the surface properties of new-generation phakic IOLs made of PMMA and a



**Figure 2.** SEMs of the Ophtec Artisan iris-claw IOL with 5.0-mm optic diameter. **A**, Overview (original magnification,  $\times 5.8$ ). **B**, Haptic/optic junction with good surface finish (original magnification,  $\times 22$ ). **C**, Claw ends with irregularities and sharp edges (original magnification,  $\times 88$ ).

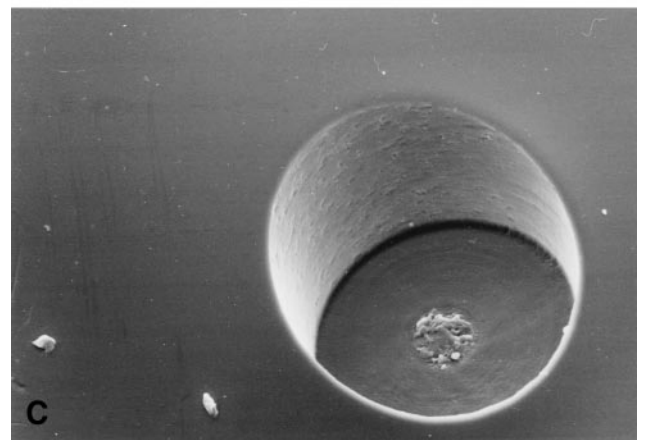


collagen/HEMA-polymer and uniformly found excellent surface quality with no surplus material or molding flash. All but one haptic end (Fig 2C) had a smooth, even surface, and the haptic and optic surfaces of all IOLs were smooth and regular.

The main complications of phakic IOLs include endothelial cell loss, pupil ovalization, glaucoma, and chronic subclinical inflammation for anterior chamber IOLs,<sup>1,22-25</sup> and cataract formation, pupillary block, pigment dispersion,



**Figure 3.** SEMs of the Ophtec Artisan IOL with a 6.0-mm optic. **A**, Overview of the front side shows a smooth and regular surface and good finish (original magnification,  $\times 5.8$ ). **B**, At the optic edge, no molding flash is visible (original magnification,  $\times 45$ ). **C**, Claw ends show no sharp edges (original magnification,  $\times 175$ ).

and glaucoma for posterior chamber IOLs.<sup>2,26–31</sup> The clinical impact of surface irregularities for these complications remains to be established. However, these lenses are placed in direct contact with delicate tissues like the anterior chamber angle (angle-fixated anterior chamber lenses), the iris (iris-fixated anterior chamber lenses), and the ciliary sulcus or crystalline lens (posterior chamber lenses). It is conceiv-



**Figure 4.** SEM images of the Staar ICL posterior chamber one-piece plate-haptic phakic intraocular lens. **A**, Overview of the front surface reveals an excellent finish. The slightly bent haptic edges are an artifact caused by the water extraction for the SEM procedure. The small particles on the IOL are artifacts after the examination procedure (original magnification,  $\times 5.8$ ). **B**, Edge of the foot plate with smooth optic surface and positioning hole (original magnification,  $\times 45$ ). **C**, Holes in the IOL near the optic do not reveal any major irregularities (original magnification,  $\times 88$ ).

able that surplus material or surface defects would result in irritation of these tissues, causing some of the aforementioned complications with phakic IOLs. Surface irregulari-



ties by themselves could be accompanied by deposition of inflammatory cells, protein, or microorganisms and might predispose to synechia formation.<sup>7-9,14-16</sup> Considering the sometimes delayed manifestations of complications with IOLs, irregularities on the IOL surface could provoke them in phakic IOLs. Long-term clinical studies with larger numbers of patients are required to verify the safety of these IOLs.

In this study we have used SEM to analyze the surface quality of phakic IOLs. Recently, a discussion of the "gold standard" of techniques for studying intraocular lens finishing was published.<sup>32</sup> There seem to be even more sophisticated methods than SEM, namely low-voltage SEM (LVSEM) or atomic force microscopy (AFM) to examine surfaces.<sup>32-35</sup> With these new techniques (LVSEM, AFM) an even more accurate assessment of phakic IOLs might be possible. However, the information obtained in our study with SEM allows good comparison with previous surface IOL examinations.<sup>19-21</sup>

In summary, we can state that the surface quality of third-generation phakic IOLs is excellent in this small number of samples. The quality meets the "gold standard" set by other PMMA and foldable IOLs.<sup>19-21,36</sup> We believe that the safest option for phakic IOL implantation is an IOL with perfectly smooth and regular surfaces. The process of developing and refining ophthalmic biomaterials especially seems to be of great importance for phakic IOLs.<sup>37</sup> From this study we can conclude that no contraindication for the implantation of the examined new implants into phakic eyes should exist because of surface quality.

## References

- Baikoff G, Arne JL, Bokobza Y, et al. Angle-fixated anterior chamber phakic intraocular lens for myopia of -7 to -9 diopters [see comments]. *J Refract Surg* 1998;14:282-93. Comment in: *J Refract Surg* 1998;14:272-7.
- Rosen E, Gore C. Staar collamer posterior chamber phakic intraocular lens to correct myopia and hyperopia. *J Cataract Refract Surg* 1998;24:596-606.
- Landesz M, Worst JG, Siertsema JV, van Rij G. Correction of high myopia with the Worst myopia claw intraocular lens. *J Refract Surg* 1995;11:16-25.
- Apple DJ, Mamalis N, Loftfield K, et al. Complications of intraocular lenses. A historical and histopathological review. *Surv Ophthalmol* 1984;29:1-54.
- Apple DJ, Mamalis N, Olson RJ, et al. Intraocular Lenses: Evolution, Designs, Complications and Pathology. Baltimore: Williams & Wilkins, 1989.
- Amon M. Die Relevanz der in-vitro Dokumentation zellulärer Reaktionen auf der Linsenoberfläche für die Beurteilung der Biokompatibilität unterschiedlicher intraokularer Implantate. *Spektrum Augenheilkd* 1992; 6(Suppl 7):1-42.
- Cunanan CM, Tarboux NM, Knight PM. Surface properties of intraocular lens materials and their influence on in vitro cell adhesion. *J Cataract Refract Surg* 1991;17:767-73.
- Ohara K, Okada K, Akahoshi T. Surface quality of intraocular lenses. *J Cataract Refract Surg* 1989;15:105-8.
- Versura P, Caramazza R. Ultrastructure of cells cultured onto various intraocular lens materials. *J Cataract Refract Surg* 1992;18:58-64.
- Wolter JR. Cytopathology of intraocular lens implantation. *Ophthalmology* 1985;92:135-42.
- Mateo NB, Ratner BD. Relating the surface properties of intraocular lens materials to endothelial cell adhesion damage. *Invest Ophthalmol Vis Sci* 1989;30:853-60.
- Nishi O. Fibrinous membrane formation on the posterior chamber lens during the early postoperative period. *J Cataract Refract Surg* 1988;14:73-7.
- Joo CK, Kim JH. Compatibility of intraocular lenses with blood and connective tissue cells measured by cellular deposition and inflammatory response in vitro. *J Cataract Refract Surg* 1992;18:240-6.
- Kochounian HH, Maxwell WA, Gupta A. Complement activation by surface modified poly(methyl methacrylate) intraocular lenses. *J Cataract Refract Surg* 1991;17:139-42.
- Mondino BJ, Rao H. Effect of intraocular lenses on complement levels in human serum. *Acta Ophthalmol (Copenh)* 1983;61:76-84.
- Wolter JR. Pathology and general significance of fibrin deposition on lens implants. *J Cataract Refract Surg* 1989;15:572-6.
- Kohnen T, Dick B, Jacobi KW. Surface alterations on PMMA-intraocular lenses induced by different implantation forceps. *Eur J Implant Refract Surg* 1994;6:138-42.
- Koch DD, Samuelson SW, Dimonie V. Surface analysis of surface-passivated intraocular lens. *J Cataract Refract Surg* 1991;17:131-8.
- Kohnen T, Magdowski G, Koch DD. Oberflächenqualität faltbarer Intraokularlinsen aus Silikon. Eine rasterelektronenmikroskopische Studie. *Klin Monatsbl Augenheilkd* 1995;207:253-63.
- Omar O, Mamalis N, Veiga J, et al. Scanning electron microscopic characteristics of small-incision intraocular lenses [see comments]. *Ophthalmology* 1996;103:1124-9. Comment in: *Ophthalmology* 1997;104:3
- Kohnen T, Magdowski G, Koch DD. Scanning electron microscopic analysis of foldable acrylic and hydrogel intraocular lenses. *J Cataract Refract Surg* 1996;22:1342-50.
- Menezo JL, Cisneros AL, Rodriguez-Salvador V. Endothelial study of iris-claw phakic lens: four year follow-up [see comments]. *J Cataract Refract Surg* 1998;24:1039-49. Comment in: *J Cataract Refract Surg* 1998;24:1013-4.
- Pérez-Santonja JJ, Iradier MT, Benítez del Castillo JM, et al. Chronic subclinical inflammation in phakic eyes with intraocular lenses to correct myopia [see comment]. *J Cataract Refract Surg* 1996;22:183-7. Comment in: *J Cataract Refract Surg* 1997;23:815-7.
- Pérez-Santonja JJ, Iradier MT, Sanz-Iglesias L, et al. Endothelial changes in phakic eyes with anterior chamber intraocular lenses to correct high myopia. *J Cataract Refract Surg* 1996;22:1017-22.
- Alio JL, de la Hoz F, Pérez-Santonja JL, et al. Phakic anterior chamber lenses for the correction of myopia: a 7-year cumulative analysis of complications in 263 cases. *Ophthalmology* 1999;106:458-66.
- Erturk H, Ozcetin H. Phakic posterior chamber intraocular lenses for the correction of high myopia [see comments]. *J Refract Surg* 1995;11:388-91. Comment in: *J Refract Surg* 1996;12:454-6.
- Assetto V, Benedetti S, Pesando P. Collamer intraocular contact lens to correct high myopia. *J Cataract Refract Surg* 1996;22:551-6.
- Fechner PU, Haigis W, Wichmann W. Posterior chamber myopia lenses in phakic eyes [see comments]. *J Cataract Refract Surg* 1996;22:178-82. Comment in: *J Cataract Refract Surg* 1996;22:153-4.

29. Brown DC, Grabow HB, Martin RG, et al. Staar collamer intraocular lens: clinical results from the phase I FDA core study. *J Cataract Refract Surg* 1998;24:1032–8.
30. Trindade F, Pereira F. Cataract formation after posterior chamber phakic intraocular lens implantation [see comments]. *J Cataract Refract Surg* 1998;24:1661–3. Comment in: *J Cataract Refract Surg* 1999;25:461–2.
31. Visessoon N, Peng Q, Apple DJ, et al. Pathological examination of an explanted posterior chamber intraocular lens [see comments]. *J Cataract Refract Surg* 1999;25:216–22. Comment in: *J Cataract Refract Surg* 1999;25:1033–4.
32. Goldberg EP. Surface characterization of intraocular lenses [letter]. *Ophthalmology* 1997;104:3. Comment on: *Ophthalmology* 1996;103:1124–9.
33. Goldberg EP, Yalon M, Longo WE. Low voltage SEM for unique surface analysis of prosthetic devices. In: Hanker JS, Giammara BL, eds. *Proceedings of the Biomedical Materials and Devices Symposium*; 1987 Nov 30-Dec 4; Boston, MA. Pittsburgh: Materials Research Society, 1989; 355–60.
34. Hayashi H, Oshima K. Low-vacuum, low-voltage scanning electron microscopy of poly(methyl methacrylate) intraocular lenses. *J Cataract Refract Surg* 1998;24:385–9.
35. Bhatia S, Goldberg EP, Enns JB. Examination of contact lens surfaces by Atomic Force Microscope (AFM). *CLAO J* 1997; 23:264–9.
36. Apple DJ, Mamalis N, Brady SE, et al. Biocompatibility of implant materials: a review and scanning electron microscopic study [review]. *J Am Intraocul Implant Soc* 1984; 10:53–66.
37. Obstbaum SA. Development of foldable IOL materials [editorial]. *J Cataract Refract Surg* 1995;21:233. Comment on: *J Cataract Refract Surg* 1995;21:331–47.