

# Artisan Toric Phakic Intraocular Lens for the Correction of High Astigmatism

JOSE L. GÜELL, MD, PhD, MERCEDES VÁZQUEZ, MD, FRANCOISE MALECAZE, MD, PhD,  
FELICIDAD MANERO, MD, OSCAR GRIS, MD, FORTINO VELASCO, MD,  
HELENE HULIN, MD, AND JAUNE PUJOL, MD, PhD

- **PURPOSE:** To evaluate efficacy, predictability, and safety of Artisan toric phakic intraocular lens (Ophtec, Groningen, The Netherlands) implantation for the correction of astigmatism higher than 2 diopters.
- **DESIGN:** Interventional case series.
- **METHODS:** This prospective study included 27 eyes of 16 patients with a mean preoperative spherical equivalent of  $-11.78 \pm 6.24$  diopters and a mean preoperative astigmatism of  $-3.43 \pm 0.81$ . The Artisan phakic intraocular lens was inserted in the anterior chamber through a posterior corneal incision; the technique is similar to the implantation of the classical Artisan lens, but in these cases it is particularly important to secure the lens accurately in the correct axis. The main parameters evaluated in this study were uncorrected visual acuity, best-corrected visual acuity, refraction, and endothelial cell count.
- **RESULTS:** Twelve months after the implantation of the Artisan toric phakic intraocular lens, 62.90% of the eyes were within  $\pm 0.50$  diopters. of emmetropia and 96.20% within  $\pm 1.0$  diopters. Seventy percent of the eyes gained 1 or more Snellen lines from their preoperative best-corrected visual acuity, and 11.11% lost 1 Snellen line. Mean endothelial cell count increased 2.9%. Mean of the parallel and orthogonal components of cylinder correction were 1.97 diopters and 0.10 diopters, respectively, of the intended cylinder change. The mean of axis alignment error was 10.53 degrees. No serious complications were observed.
- **CONCLUSION:** Artisan toric phakic intraocular lens implantation appears to be a safe and predictable method for the correction of high levels of astigmatism. (Am J

Ophthalmol 2003;136:442-447. © 2003 by Elsevier Inc. All rights reserved.)

**T**HE SURGICAL CORRECTION OF NATURAL AND INDUCED astigmatism has advanced rapidly in the last decade. Astigmatic keratotomy, photorefractive astigmatic keratectomy, laser-assisted in situ keratomileusis (LASIK), photothermal keratoplasty techniques, cataract or clear lens extraction surgery with toric intraocular lens (IOL) implantation, phakic toric intraocular lenses, or a combination of these procedures are the main techniques employed.

The various procedures for the surgical management of high levels of astigmatism have had their limitations. Combined procedures, such as astigmatic keratotomy plus photorefractive astigmatic keratectomy,<sup>1</sup> astigmatic keratotomy plus myopic in situ keratomileusis,<sup>2</sup> astigmatic keratotomy plus laser-assisted in situ keratomileusis,<sup>3</sup> and astigmatic keratotomy with cataract surgery,<sup>4</sup> and a procedure termed keratolenticuloplasty have been tried in these cases to improve efficacy and predictability.

In young patients with high ametropia and high astigmatism, toric phakic intraocular lenses may be an alternative to be taken into account before other corneal refractive approaches because of its theoretical advantages of reversibility and the preservation of the corneal contour.

We have been working with the Artisan lens (Ophtec, Groningen, The Netherlands), an iris-claw fixated intraocular lens that is the phakic lens of our preference.<sup>5,6</sup> Currently we are using this type of lens to make toric corrections. Our inclusion and exclusion criteria are the same than for the standard Artisan lens.

Originally, the reasons to work with this intraocular lens (IOL) were its location of placement in the eye, far from the corneal endothelium and avoiding the posterior chamber, and its larger optical zone compared with other anterior chamber phakic IOLs used for the same range of corrections. An important optical advantage is that, because of its fixation characteristics, centering the lens over the pupil is dependent on surgeon ability rather than angle situation (as with angle-supported IOLs) or difficult "white

Accepted for publication March 4, 2003.

From the IMO Instituto de Microcirugía Ocular, Barcelona, Spain (J.L.G., M.V., O.G., F.V.); Service Ophtalmologie, CHU Toulouse, Toulouse, France (F.M., H.H.); Centre de Desenvolupament de Sensors, Instrumentació i Sistemes (CD6), Universitat Politècnica de Catalunya, Terrassa, Spain (J.P.).

Inquires to José L. Güell, MD, PhD, Instituto de Microcirugía Ocular (IMO), 08022, Barcelona, Spain; fax: (+34) 93-4171301; e-mail: guell@imo.es

to white" measurements (as with posterior chamber IOLs). We report the results of 27 eyes implanted with the Artisan toric phakic IOLs designed to correct both spherical and astigmatic components of ametropia.

## METHODS

THE STUDY DESIGN IS AN INTERVENTIONAL CASE SERIES. Two surgeons, José L. Güell at Instituto de Microcirugía Ocular de Barcelona, Spain, and F. Malecaze at Service Ophthalmologie, CHU Toulouse, France, performed the procedures. We enrolled 27 eyes of 16 patients in this prospective study (6 men, 10 women), aged from 28 to 50 years ( $37.8 \pm 7.18$  years).

The preoperative spherical equivalent ranged from +6.00 diopters (D) to -19.50 diopters (D) (mean,  $-11.78 \pm 6.24$ ) and preoperative astigmatism ranged from -2.25 to -4.75 (mean,  $-3.43 \pm 0.90$ ). Preoperative uncorrected visual acuity was lower than 20/400 in all of the eyes, and preoperative best-corrected visual acuity was  $\geq 20/40$  in 78% of the eyes.

The study included a consecutive series of patients who, for medical, professional, or personal requirements, attained unsatisfactory correction with spectacles or contact lenses; had a stable refraction for at least 1 year; had astigmatism  $> -2.00$ ; and either did not want refractive surgery or it was contraindicated for them. The study was approved by the ethical committees of Barcelona (Autonoma University) and Toulouse. All patients were fully informed of the details and possible risks of the procedure in accordance with the Helsinki Declaration, and written informed consent was obtained for each patient.

Exclusion criteria were as follows: anterior segment pathology, inadequate eyelid closure, uveitis, previous corneal or intraocular surgery, monocular status, systemic diseases (such as autoimmune, connective tissue disease, atopia, or diabetes), chronic treatment with corticosteroids or any immunosuppressive treatment or state, pregnancy, endothelial cell counts of less than  $2,200 \text{ cell/mm}^2$ , and an anterior chamber central depth less than 3.2 mm.

Examinations were performed by M. Vazquez and H. Hulin. The preoperative evaluation included uncorrected visual acuity and best-corrected visual acuity, manifest and cycloplegic refraction, slit-lamp microscope examination, applanation tonometry, keratometry, and indirect ophthalmoscopy. The subjective response for satisfaction was rated on a scale from 1 to 5 (1 = *very poor*, 2 = *poor*, 3 = *moderate*, 4 = *good*, and 5 = *excellent*). The symptoms such as glare and halos were rated as 1 = *very intense*, 2 = *intense*, 3 = *moderate*, 4 = *few*, and 5 = *none*. Complementary examinations were also required, including axial length and anterior chamber depth, videokeratography, and endothelial cell count.

Postoperative evaluations were programmed at 24 hours, 1 week, and 1, 3, 6, and 12 months after surgery. A

complete ophthalmologic examination was performed at each visit, as previously described, with the exception of the first and seventh day postoperatively, on which endothelial cell count was not measured.

The Artisan IOL is a one-piece polymethylmetacrylate (PMMA) lens. Its overall diameter is 8.5 mm, maximum height is 1.04 mm, and optical zone diameter is 5.0 mm. The available powers for myopia vary from -3.00 to -20.00 D, with cylindrical correction from 1 to 7 D and, for hyperopia, from + 2.00 to + 12.00 D with the same cylindrical correction as for myopia.

The dioptric power of the lens was calculated with the patient's refractive error, the anterior chamber depth, and keratometric values (Van der Heijde formula).<sup>7</sup>

There are two available models for correcting, with a similar surgical technique, any astigmatic axis: a toric Artisan phakic IOL with a cylinder axis at 0 degrees (model A) and a toric Artisan phakic IOL with a cylinder axis at 90 degrees (model B) with respect to the position of the haptics. When the axis of the cylinder is between 0 and 45 degrees or 135 and 180 degrees, model A is recommended; when the axis of the cylinder is between 45 and 135 degrees, model B is recommended.

The procedure was similar to standard Artisan IOL implantation, but in these cases it was important to secure the lens accurately in the correct axis to avoid induced astigmatism. The enclavation sites were preoperatively marked on the iris using argon laser. The limbus was also marked, immediately before the surgery, while the patient was sitting upright at the ophthalmometer.

We generally used a superior approach and retrobulbar anesthesia (4 cc of a proportional combination of mepivacaine 2% and bupivacaine 0.75%). The first plane of a 5.2-mm-long posterior vascular corneal incision and two vertical paracentesis were performed. These last two were located for an easy iris enclavation, accordingly, to the cylinder axis where the IOL had to be placed. After the intracameral injection of acetylcholine and viscoelastic material through the paracentesis, the second plane of the incision was performed, opening the anterior chamber. The lens was then completely introduced in one step to avoid any contact of the front part of the IOL with the crystalline lens. Under viscoelastic protection, the IOL was then rotated until the appropriate axis was reached. The IOL was fixated with a blunt 30-G blended needle, grasping, through both paracentesis, the iris into both "claws." Once the proper axis alignment and centering over the pupil was confirmed, a peripheral slit iridotomy at 12 o'clock was performed. Viscoelastic material was exchanged with balanced salt solution through our irrigation-aspiration automatic system, and the incision was closed with five interrupted 10-0 nylon sutures. The correct tension and distribution of the sutures were confirmed with a Maloney qualitative keratometer. Postoperative treatment included tobramycin and dexamethasone four times

per day and timolol 0.5% twice a day for 3 weeks. Suture removal was started at the first postoperative month, taking into account postoperative refractive and topographic astigmatism.

Change in spherical equivalent manifest refraction was calculated by subtraction.

$$DSE = SE_2 - SE_1$$

where  $DSE$  is change in spherical equivalent,  $SE_1$  and  $SE_2$  are spherical equivalent at preoperative and postoperative examination, respectively.

Cylindrical refractions were represented as double-angle vectors, which can be decomposed into two perpendicular components in rectangular coordinates as follows:

$$X = A \cos(2a)$$

$$Y = A \sin(2a)$$

Where  $X$  is the cardinal component,  $Y$  is the oblique component,  $A$  is the cylinder magnitude in diopters,  $a$  = Cylinder axis in degree.  $X$  is positive for against-the-rule astigmatism and negative for with-the-rule astigmatism.  $Y$  is positive for a positive cylinder at 45 and negative for a positive cylinder at 135. The positive cylinder convention is used for these calculations.

Changes in cylindrical refractions are computed in rectangular coordinates as follows:

$$DX = X_2 - X_1$$

$$DY = Y_2 - Y_1$$

where  $DX$  is the change in cardinal component of astigmatism,  $X_2$  is the postoperative cardinal components,  $X_1$  the preoperative cardinal components,  $DY$  the change in oblique component of astigmatism,  $Y_2$  the postoperative oblique components, and  $Y_1$  the preoperative oblique components.

Conversion from rectangular to polar coordinates is performed as follows:

$$DA = (DX^2 + DY^2)^{1/2}$$

If  $DX = 0$ , then if  $DY > 0$ ,  $b = 45$ , otherwise  $b = 135$ .

If  $DX > 0$  and  $DY > 0$ ,  $b = 0.5 \arctan(DY/DX)$ ;

if  $DX > 0$  and  $DY < 0$ ,  $b = 0.5 \{\arctan(DY/DX) + 360\}$ ;

if  $DX < 0$ ,  $b = 0.5 \{\arctan(DY/DX) + 180\}$ ,

where  $DA$  is the magnitude of cylinder change, and  $b$  is the axis of cylinder change.

Deviation  $g$  of the axis of the actual cylinder change from the axis of intended change is computed as follows:

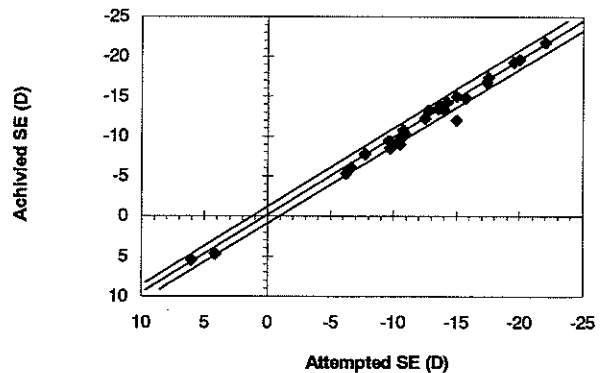


FIGURE 1. Scattergram shows the preoperative manifest spherical equivalent refraction vs the induced change 1 year after Artisan toric phakic intraocular lens implantation.

If  $b - b_{intended} > 90$ , then  $g = b - b_{intended} - 180$ ;  
if  $b - b_{intended} < -90$ , then  $g = b - b_{intended} + 180$ ;  
otherwise,  $g = b - b_{intended}$ ;

where  $b_{intended}$  = axis of intended cylinder change.

A positive  $g$  indicates a counterclockwise (CCW) axis deviation and a negative  $g$  indicates a clockwise (CW) axis deviation. By our convention, the axis of intended cylinder correction was always the same, from the consensus preoperative refractive cylinder axis.

The cylinder changes can be decomposed into two rectangular components referenced to the axis of intended correction.

$$DP = DA \cos(2g)$$

$$DO = DA \sin(2g)$$

where  $DP$  is the component of cylinder change parallel to the axis of intended correction and  $DO$  is the component of cylinder change orthogonal to the axis of intended correction. The terms *parallel* and *orthogonal* refer to orientations in the double-angle vector plot.

The formulae for the decomposition of astigmatism vectors into cardinal and oblique components are adapted from Holladay and associates,<sup>8,9</sup> Naeser,<sup>10</sup> Alpins,<sup>11</sup> and Huang and associates.<sup>12</sup>

Concerning quantitative data, the comparisons between pre- and postoperative periods were performed using the Student  $t$  test for paired data. Comparisons for percentages were performed using the  $\chi^2$  and McNemar tests.

## RESULTS

MEAN PREOPERATIVE SPHERICAL EQUIVALENT REFRACTION and astigmatism were  $-11.78 \pm 6.24$  (+ 6.00 to -19.50) and  $-3.48 \pm 0.81$  (-2.25 to -4.50), respectively. Mean postoperative spherical equivalent refraction and astigmatism were  $-0.58 \pm 0.64$  (-1.25 to 0) and  $-0.66 \pm$

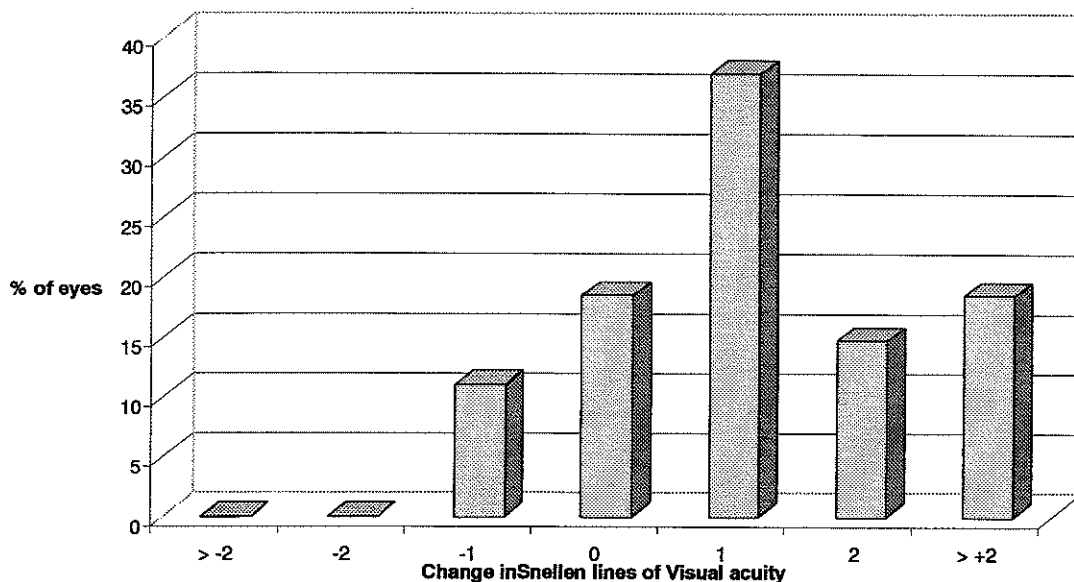


FIGURE 2. The bar graph depicts the change in best-corrected visual acuity from preoperative to the 1-year postoperative examinations in terms of change in the number of Snellen lines.

0.57 (−1.00 to 0), respectively, at 12 months (Figure 1) after the surgery. A satisfactory residual refraction appeared early, at the first month, and an optimal residual refraction had already been obtained as early as the third month (Table 1).

One year after the surgery, 96.20% of the eyes were within  $\pm 1.00$  D of emmetropia, and 17 eyes (63%) were within  $\pm 0.50$  D after Artisan toric implantation. Regarding the astigmatism, 85.50% of the eyes were within  $\pm 1.00$  D after IOL implantation and 8 eyes (30%) were within  $\pm 0.50$  D (Table 1). To analyze the change in astigmatism caused by the surgery, the astigmatic component of the power vector was represented by decomposition of the cylinder change vector. The mean of the parallel components was  $-0.97$  D and the mean of the orthogonal components was  $0.10$  D of cylinder correction of the intended cylinder change (Table 2). Mean of the magnitude of cylindrical power error was  $0.74$  D, with respect to the cylindrical power intended (Table 3). The mean of axis alignment error was  $10.53$  degrees (Table 4). We also constructed a formal statistical analysis of the null hypothesis in which postsurgical power vectors were equal to zero. The results of these tests, conducted at the 0.01 level, indicated that neither astigmatism components are significantly different from zero.

Preoperative uncorrected visual acuity was less than 20/400 in all cases; its evolution during the first postoperative year is shown in Table 1. At 1 year, about two thirds (63%) of the eyes had an uncorrected visual acuity of 20/40 or better. The maximal efficacy was observed as soon as the third month (Table 1), once the sutures had been removed.

With regard to best-corrected visual acuity, as shown in Table 1, the safety index (ratio of mean postoperative

BSCVA over mean preoperative BSCVA) was high at all periods. The evaluation of visual acuity in terms of gain or loss of 1 or more Snellen lines confirms this result: Three eyes (11.11%) lost a single Snellen line of visual acuity, but 37.03% of the eyes gained 1 line, 14.80% gained 2 lines, and 18.50% gained 3 or more lines after the procedure, compared with preoperative values (Figure 2).

Mean preoperative endothelial cell density was  $2,649 \pm 311$  cells/mm<sup>2</sup> (2,231–3,355). Twelve months after IOL implantation, mean endothelial density was  $2,726 \pm 271$  cells/mm<sup>2</sup> (2,241–3,355). These differences between preoperative and postoperative endothelial cell counts were not statistically significant ( $P = .21$ ). There were no significant intraoperative or postoperative complications during the follow-up period in this group of eyes. During the first week after IOL implantation, 10% of the eyes were found to have mild elevation of intraocular pressure. From the first month through the 1-year follow-ups, no statistically significant difference was observed when comparing the pre- and postoperative intraocular pressure values. No lens opacification, pigmentary dispersion, pupillary block, or retinal complications occurred during the follow-up period.

All the patients were highly satisfied with the procedure. Mean subjective response for satisfaction and symptoms such as glare and halos was 4.0 at 12 months after the surgery, using the scale described previously.

## DISCUSSION

THE CORRECTION OF HIGH ASTIGMATISM IS STILL A CONTROVERSIAL issue. Corneal refractive (nonreversible) surgery cannot adequately correct high myopia and astigmatism

**TABLE 1.** Comparison of the Visual Acuity and Refractive Outcomes at Various Intervals After Artisan Toric Phakic Intraocular Lens Implantation

	1 Month	3 Months	6 Months	1 Year
UCVA $\geq$ 20/40	11/27 (41%)	20/27 (74%)	21/27 (78%)	21/27 (78%)
Safety index*	1.16	1.25	1.34	1.40
Spherical equivalent (D)	-0.70 $\pm$ 1.04	-0.37 $\pm$ 0.66	-0.32 $\pm$ 0.75	-0.58 $\pm$ 0.64

UCVA = Uncorrected visual acuity; BCVA = best-corrected visual acuity; D = diopters.  
\*Safety index = ratio of mean postoperative BCVA over mean preoperative BCVA.

**TABLE 2.** Statistical Summary of the Decomposition of Astigmatism Vectors Into Parallel and Orthogonal Components

	DP	DO
Mean	-0.9713	0.1043
SEM	0.3536	0.0635
SD	0.3240	0.2202

DP = component of cylinder change parallel to the axis of intended correction; DO = component of cylinder change orthogonal to the axis of intended correction.

**TABLE 3.** Statistical Summary of the Magnitude of Cylinder Change

	Intended	Achieved
Mean	-4.41	-3.67
SEM	0.2543	0.3492
SD	0.8812	1.2098

SD = standard deviation; SEM = standard error of the mean.

levels without decreasing the central optical zone and thus limiting the quality of vision.<sup>13,14</sup> Combined procedures such as astigmatic keratotomy plus LASIK<sup>3</sup> and better and improved ablational profiles and techniques (positive cylinder, cross cylinder) have emerged to achieve the latter. With the implantation of the Artisan toric phakic IOL, however, it is theoretically possible to obtain good results with a single reversible procedure.

Artisan toric phakic IOL implantation allows correction of myopia up to -20.00 and of astigmatism up to 7.00 D, with an optical zone of 5 mm. Conversely, it is a reversible and adjustable procedure, hence the lens may be explanted, exchanged, or adjusted with corneal refractive surgery, primarily LASIK. Another advantage of this technique is the possibility of attaining better vision because the original corneal contour is preserved. Performing a 6-mm optical zone arcuate keratotomy or 5-mm optical zone LASIK is different from a 5-mm optical zone

**TABLE 4.** Postsurgical Axis Error

	Axis Error
Mean (degrees)	10.53
Mean absolute (degrees)	18.68
SD (degrees)	21.64

SD = standard deviation.

Artisan implantation. The central effective optical zone will always be smaller in the first two procedures, and thus patients may suffer more frequently from complaints such as glare and halos, especially in dim lighting conditions.<sup>15</sup> Therefore, correction with a toric lens may be an interesting alternative, even though this means correcting a corneal astigmatism that theoretically could be treated by a corneal procedure.

The refractive results of this study were excellent. At 1 year, 96% (25 eyes) of the eyes were within  $\pm$ 1.00 D of emmetropia and 63% (17 eyes) were within  $\pm$ 0.50 D. These refractive results appeared early in the postoperative period; similar values had already been attained as early as the third month. With corneal refractive surgery it has not always been possible to attain such results and combined procedures or upgraded profiles or techniques had to be employed to improve efficacy.<sup>3</sup> In contrast, all patients in our study noted that they were highly satisfied with the procedure.

Seventy percent of the eyes in this study gained one or more lines of their preoperative best-corrected visual acuity. Other authors<sup>16,17</sup> have reported this gain in visual acuity after phakic IOL implantation because of the increase in the size of the retinal image.

Damage to the endothelium is one of the main concerns with anterior chamber phakic IOL implantation. This could be the result of the surgery itself or of the presence of a foreign body in the anterior chamber (chronic inflammatory or mechanical hypothesis). Nevertheless, we observed a paradoxical increase (+2.90%) in the mean endothelial cell count. This may be due to the reproducibility of the technique, despite the fact that we took extreme care to eliminate bias (eight measures at each

exploration time per patient). It may also be explained by the long-term daily use by most of our patients of toric soft contact lenses or rigid gas permeable contact lenses until the surgery was performed (13 of 16 patients). Despite this, a long-term follow-up is essential with any type of anterior chamber lenses to assess the stability of endothelial cell count and morphology. Budo and associates<sup>18</sup> reported an endothelial cell loss of 0.7% per year between 2 and 3 years following a mean loss of 7.1% during the first year, possibly associated with the initial surgical trauma. Similar results have been described by other authors, including us.<sup>5,19</sup> A more complete follow-up of these patients (5 to 10 years) compared with an age-matched control group would be important in assessing the safety of these lenses and considering their use as an standard either in myopia alone or combined with astigmatism.

We had no intraoperative or postoperative complications. This is probably related to our experience with this type of implant. We must point out that, from our point of view, a proper surgical training is especially important with this type of IOL implantation and especially with the toric model. In our study group, best-corrected visual acuity was equal or better compared with the preoperative values, which favors the procedure; only three cases lost 1 Snellen line with respect to their best-corrected visual acuity. As with other series,<sup>16,20</sup> no postoperative glaucoma has been observed, with the exception of a mild, transient early episode of elevated intraocular pressure. The problem resolved with discontinuation of topical corticosteroids. Other complications reported in the literature, such as decentration,<sup>16</sup> retinal complications,<sup>17</sup> cystic wounds,<sup>21</sup> Urrets/Zavalía syndrome,<sup>21</sup> lens opacity,<sup>16</sup> and ischemic optic neuropathy,<sup>22</sup> were not found in our series.

Artisan toric phakic IOL implantation appears to be a suitable option for patients with high levels of myopia or hyperopia and astigmatism and who otherwise have normal ophthalmologic examinations. Nevertheless a long-term follow-up of these patients will provide the last word. This technique has been helpful to us in the correction of postpenetrating keratoplasty ametropia. In any case, we favor this approach over aggressive irreversible corneal surgery, combined or alone, in correcting this high ametropic group. From our point of view, corneal refractive surgery, customized or not, should be reserved for postoperative refinements until the IOL itself can be modified in situ (Light Adjustable IOL project).

## REFERENCES

- Ganem S, Sidhoum B. Surgery in myopic astigmatism: arciform keratotomy and PRK versus PARK. *Bull Soc Belge Ophthalmol* 1997;266:87-90.
- Manche EE, Maloney RK. Astigmatism keratotomy combined with myopic keratomileusis in situ for compound myopic astigmatism. *Am J Ophthalmol* 1996;122:18-28.
- Guell JL, Vazquez M. Correction of high astigmatism with astigmatic keratotomy combined with laser in situ keratomileusis. *J Cataract Refract Surg* 2000;26:960-966.
- Kershner RM. Keratolenticuloplasty: arcuate keratotomy for cataract surgery and astigmatism. *J Cataract Refract Surg* 1995;21:274-277.
- Güell JL, Vazquez M, Gris O, De Muller A, Manero F. Combined surgery to correct high myopia: iris claw phakic intraocular lens and laser in situ keratomileusis. *J Refract Surg* 1999;15:529-537.
- Güell JL, Vazquez M. Adjustable refractive surgery: 6-mm Artisan lens plus laser in situ keratomileusis for the correction of high myopia. *Ophthalmology* 2001;108:945-952.
- Van der Heijde GL, Fechner PU, Worst JGF. Optische Konsequenzen der Implantation einer negativen Intraokularlinse bei myopen Patienten. *Klin Monatsbl Augenheilkd* 1988;193:99-102.
- Holladay JT, Dudeja DR, Koch DD. Evaluating and reporting astigmatism for individual and aggregate data. *J Cataract Refract Surg* 1998;24:57-65.
- Thibos LN, Wheeler W, Horner D. Power vectors: an application of Fourier analysis to the description and statistical analysis of refractive error. *Optom Vis Sci* 1997;74:367-375.
- Naeser K, Beherens JK, Naeser EV. Quantitative assessment of corneal astigmatic surgery: Expanding the polar values concept. *J Cataract Refract Surg* 1994;20:162-168.
- Alpins NA. Vector analysis of astigmatism changes by flattening, steepening and torque. *J Cataract Refract Surg* 1997;23:1503-1514.
- Huang D, Stulting D, Carr J, et al. Multiple regression and vector analyses of laser in situ keratomileusis for myopia and astigmatism. *J Refract Surg* 1999;15:538-550.
- Chávez S, Chayet A, Celikkol L, Parker J, Celikkol G, Feldman ST. Analysis of astigmatism keratotomy with a 5.0 mm optical clear zone. *Am J Ophthalmol* 1996;121:65-76.
- Danjoux JP, Fraenkel G, Lawless MA, Rogers C. Treatment of myopic astigmatism with the Summit Apex Plus excimer laser. *J Cataract Surg* 1997;23:1472-1479.
- Uozato H, Guyton DL. Centering corneal surgical procedures. *Am J Ophthalmol* 1987;103:264-275.
- Pérez-Santonja JJ, Bueno J, Zato MA. Surgical correction of high myopia in phakic eyes with Worst-Fechner myopia intraocular lenses. *J Refract Surg* 1997;13:268-284.
- Fechner PU, Wichmann W. Correction of myopia by implantation of minus optic (Worst iris claw) lenses into the anterior chamber of phakic eyes. *Eur J Implant Surg* 1993;5:55-59.
- Budo C, Hessloehl JC, Izak M, et al. Multicenter study of the Artisan phakic intraocular lens. *J Cataract Refract Surg* 2000;26:1163-1171.
- Menezo JL, Cisneros AL, Rodriguez-Salvador V. Endothelial study of iris-claw phakic lens: four year follow-up. *J Cataract Refract Surg* 1998;8:1039-1049.
- Krumeich JH, Daniel J, Gas R. Closed-system technique for implantation of iris-supported negative-power intraocular lens. *J Refract Surg* 1996;12:334-340.
- Fechner PU, Strobel J, Wichmann W. Correction of myopia by implantation of a concave Worst-iris claw lens into phakic eyes. *Refract Corneal Surg* 1991;7:286-298.
- Pérez-Santonja JJ, Bueno JL, Meza J, et al. Ischemic optic neuropathy after intraocular lens implantation to correct high myopia in a phakic patient. *J Cataract Refract Surg* 1993;19:651-654.