

Rate of Cataract Formation in 343 Highly Myopic Eyes After Implantation of Three Types of Phakic Intraocular Lenses

José L. Menezo, MD, PhD; Cristina Peris-Martínez, MD, PhD;
Angel L. Cisneros-Lanuza, MD, PhD; Rafael Martínez-Costa, MD, PhD

ABSTRACT

PURPOSE: To assess the feasibility of using phakic intraocular lenses (PIOL) to treat high myopia, and evaluate the incidence of cataract, comparing three different lens types.

METHODS: From 1989 to 2002, we implanted three different phakic intraocular lenses (PIOL) in 343 eyes of 232 patients; 231 eyes received an Ophtec (Worst-Fechner model, iris-claw), 89 an Adatomed (silicone posterior chamber), and 23 a Staar (posterior chamber, models V2, V3, V4). Average follow-up was 96.2 months for the Ophtec group, 31.5 months for the Adatomed group, and 19.3 months for Staar group. Eyes that subsequently developed cataract were studied for clinical evolution and had PIOL explantation and cataract extraction.

RESULTS: Nuclear cataract developed in 7 of 231 eyes (3.04 %) with an Ophtec lens. Anterior subcapsular cataract developed with the two types of posterior PIOLs (Adatomed group: 38/89 eyes, 42.69%; Staar group: 3/23 eyes, 13.04%). Anterior subcapsular cataract in the Adatomed group developed more rapidly compared to the Staar group. We explanted 7 lenses in the Ophtec group, 16 lenses in the Adatomed group, and 2 lenses in the Staar group (models V2 and V3 only). Patient age older than 40 years at implantation of PIOLs and axial length greater than 30 mm were factors significantly related to nuclear cataract formation and the Ophtec lens. However, these two factors had a weaker correlation with the posterior phakic lenses

(Adatomed, Staar) for high myopia than with the Ophtec lens. Postoperative best spectacle-corrected visual acuity remained stable after explantation, phacoemulsification, and posterior chamber lens implantation.

CONCLUSIONS: Delayed cataract development and cataract type (nuclear) in patients with an Ophtec lens and the variables of patient age (>40 yr) and axial length (>30 mm) may be considered prognostic factors. Other factors such as lens design, material, and placement probably influenced cataract formation in patients with the Adatomed and Staar PIOLs. The lens styles used in this study are no longer manufactured. [*J Refract Surg* 2004;20:317-324]

Surgical correction of higher amounts of myopia has improved over the past few years.¹ Various techniques, some complementary and some overlapping, have been introduced with acceptable predictability, safety, and stability. Corneal surgery shows the greatest promise, but is controversial for higher corrections. Clear lens extraction exposes the patient to the risk of retinal detachment and cystoid macular edema.²

Phakic intraocular lens (PIOL) surgery has developed significantly since Fechner's modification of the Worst iris-claw lens and Baikoff's modification of the Kelman multiflex anterior chamber IOL in the middle 1980s.^{3,4} Both these anterior chamber PIOLs have had design improvements and are generally used to treat high myopia. Posterior chamber lenses have also been developed for high myopia.^{5,6}

Although reports mention the potential of cataract development with PIOLs, specific factors in cataract development are unknown.⁷⁻⁹ High myopia alone can predispose to cataract formation, unrelated to PIOL implantation.¹⁰⁻¹² Our study, with more than 12 years of follow-up, includes some models of Ophtec, Adatomed, and Staar PIOLs for high myopia; some treated eyes developed cataract.¹³⁻¹⁵

From the Department of Surgery, University of Valencia, School of Medicine, Valencia, Spain (Menezo), Department of Ophthalmology, La Fe University Hospital, Valencia, Spain (all authors), and Fundación Oftalmológica del Mediterráneo, Valencia, Spain (Menezo).

The authors have no proprietary interest in the development or marketing of this or a competing instrument, drug, or piece of equipment.

Correspondence: Cristina Peris-Martínez MD, PhD, La Fe University Hospital, Department of Ophthalmology, Avda. Campanar 21, 46013 Valencia, Spain. Tel: 34.96.3868767; Fax: 34.6.1973117; E-mail: cperis@ctv.es or javino@ono.com

Received: October 28, 2003

Accepted: May 20, 2004

PATIENTS AND METHODS

From October 1989 to December 2002 we implanted three different PIOLs to correct high myopia in 343 eyes of 232 patients at the Ophthalmology Department of the University Hospital La Fe. All eyes were operated by the same surgeon (JLM) and followed from the time of implantation by the same physician.

Indications for PIOL implantation were stable axial myopia not treatable by another refractive surgical technique, age younger than 50 and older than 20 years, and a best spectacle-corrected visual acuity (BSCVA) of at least 20/200. Before surgery, patients were told in detail about complications and were fully informed of the risks. All patients signed a written consent form in accordance with the Helsinki Declaration.

All patients had clear crystalline lenses, with no evidence of cataract previous to surgery. Patients with uveitis, ocular trauma, prior ocular surgery, diabetic retinopathy, or capsular pseudoexfoliation were excluded from this study.

One hundred eleven patients received bilateral implantation and 121 had a PIOL in one eye. Of 231 eyes, the first 48 received a biconcave optic model (Ophtec, Groningen, The Netherlands, Artisan brand, Worst-Fechner [iris-claw] style; no longer available); the remaining eyes had a concave-convex implant (Ophtec, Artisan). Eighty-nine eyes had an episcapsular silicone PIOL (Chiron-Bausch and Lomb, Munich, Germany, Adatomed, silicone; no longer available) and 23 eyes received an episcapsular hydrogel lens (Staar Surgical AG, Nidau, Switzerland, collamer). The Staar models used in this study were the ICM series (8 eyes with the V2 model, 7 eyes with the V3 model, and 8 eyes with the V4 model; models V2 and V3 no longer available). No particular criteria were followed in determining which PIOL the patient received. Patient data from 1989 to 2002 are summarized in Table 1; groups were comparable in spherical equivalent refraction, age, and gender.

A complete preoperative ocular examination was performed in all eyes, including anterior segment and retina examinations and measurement of intraocular pressure (IOP). In eyes with high risk peripheral retinal degenerations, argon laser prophylactic photocoagulation was performed. Anterior chamber depth was determined with an Echograph A-Ultrasound pachymeter (Nidek Echo-Scan U8-1000; Nidek Inc., Fremont, CA, and DGH ultrasonic; DGH Technology Inc., St. Louis, MO). Central keratometry was measured over two principal

Table 1
Patient Demographics for Eyes Implanted With Phakic Intraocular Lens

	Ophtec	Adatomed	Staar
Number of eyes	231	89	23
Gender			
Male	99	42	11
Female	132	47	12
Age (yr) at PIOL implantation			
Mean ± SD	35.3 ± 3.5	36.78 ± 6.7	33.79 ± 3.2
Range	24 to 67	31 to 59	29 to 47
Follow up (mo)			
Mean ± SD	96.2	31.5	19.32
Range	37 to 158	17 to 49	12 to 22
Mean preoperative myopia (D)			
Mean ± SD	-16.56 ± 3.02	-14.89 ± 2.56	-16.79 ± 4.59
Range	-7.00 to -21.50	-9.00 to -19.50	-11.50 to -19.50
Mean axial length (mm)	29.81	30.41	29.57
Mean anterior chamber depth (mm)	3.25	3.17	3.22
Number (%) of cataracts	7 (3)	38 (42.7)	3 (13)

meridians, employing a calibrated Haag-Streit keratometer (Haag-Streit, Bern, Switzerland). Central corneal endothelial cell count and morphometry was done using a non-contact specular microscope with a conventional slit lamp (Topcon SL7F, Topcon Corp, Tokyo, Japan). Visual acuity was evaluated by Snellen characters projected at a distance of 5 meters.

Eyes that subsequently developed cataract were studied for clinical evolution. A single observer identified cataract formation by ophthalmologic evidence of natural lens opacification with a slit-lamp biomicroscope (Zeiss SLO-10) after adequate pupil dilation. Cataract surgery was indicated when a reduction in BSCVA of 4 or more lines compared to BSCVA achieved after PIOL implantation was associated with progressive myopia and absence of obvious macular disease or other sight-threatening conditions. Following these criteria, we explanted and performed phacoemulsification with low power lens implantation in the capsular bag in 7 eyes with Ophtec lenses (5 eyes with biconcave lenses—Worst-Fechner polymethylmethacrylate; and 2 with convex-concave lenses—Artisan Model 206 Myopia 5/8.5), 16 eyes with Adatomed lenses, and 2 eyes with a Staar lens (Table 2).

Table 2
Patient Demographics in Eyes With PIOL Implantation That Developed Cataracts

	Ophtec	Adatomed	Staar
Number of eyes with cataracts	7	38	3
Number of cataract extractions	7	16	2
Cataract type	nuclear	anterior subcapsular	anterior subcapsular
Implanted lens model	biconcave—5 convex-concave—2	silicone biconcave	Version 3—2 Version 2—1
Gender			
Male	5	16	1
Female	2	22	2
Mean myopia (D)	-16.19 ± 2.50	-15.79 ± 3.10	-16.05 ± 2.75
Myopia range (D)	-8.00 to -21.00	-10.00 to -19.00	-13.50 to -19.50
Mean axial length (mm)	32.31	30.02	29.67
Mean anterior chamber depth (mm)	3.38	3.01	3.23
Age at cataract surgery (yr)			
Mean	53.85	34	33.5
Range	52 to 62	31 to 43	32 to 35
Mean time from implantation to appearance of cataract (mo)			
Mean	56.92 ± 2.25	13.05 ± 4.96	20 ± 1.0
Range	38 to 121	10 to 20	12 to 27
Mean time from implantation to cataract extraction (mo)	136.2	18.28	22.2

Ophtec PIOL Explantation and Cataract Surgery

All cataract extractions were made with local peribulbar anesthesia of 8 ml bupivacaine 0.75% and lidocaine 2%, administered and followed by pressure with the Honan balloon (30 mmHg) for at least 10 minutes before surgery. Under pharmacologic mydriasis, a 6-mm-long tunneled scleral incision was made at the 12 o'clock meridian. The length of the scleral arc incision was measured with a caliper. The scleral dissection was performed with a crescent knife (806-5990002, Alcon, Inc) up to approximately 2.0 mm. For additional intraocular manipulation, two puncture incisions were placed at the 3 and 9 o'clock meridians. After deepening the anterior chamber with a high viscosity viscoelastic agent (1% sodium hyaluronate), a forceps was inserted through the scleral incision, and one of the haptics was disengaged using a lens fixation forceps designed by one of the authors, JLM.² A Rycroft 30-gauge cannula was inserted through the corresponding horizontal paracentesis to free the iris fold from the slit in the haptic. This was repeated for the other haptic. The lens was oriented in the 6 and 12 o'clock direction and was explanted without complication.

After PIOL explantation, the anterior chamber was refilled with the same viscoelastic material. Two lateral X sutures were then placed in the scleral incision with partial closure of the latter to secure a 3.2-mm-long wound. Through this incision,

continuous curvilinear capsulorhexis and then phaco-fragmentation were performed. After cutting the previous sutures, a 6-mm-diameter capsular bag IOL (Corneal ACR6D, foldable style, Corneal France or Storz Hydroview) was implanted in the posterior chamber in the capsular bag. The scleral incision was then closed with X sutures (Ethicon, 10-0 nylon). The viscoelastic substance was then removed from the two puncture incisions. Finally, the corneal side-port incisions were hydrated to prevent postoperative leaking.

Adatomed and Staar Lens Extraction and Surgery

The procedure was similar to that with the Ophtec PIOL—phacoemulsification with scleral incision. These lenses, especially the Adatomed, were not as easily explanted as the Ophtec and Staar lenses.

Patients with the Adatomed silicone PIOL who developed subsequent anterior subcapsular cataracts presented a more difficult surgical problem. The PIOL was firmly approximated to the anterior capsule, presumably both from the adhesive nature of the silicone and possibly to a cupping effect from the concave surface of the lens. Therefore, during explantation, it was difficult to break this adhesion, but once it was broken, a continuous circular capsulorhexis could be accomplished.

Calculation of IOL Power for Capsular Bag Placement

In all eyes that had cataract surgery, we used the Corneal ACR6D style lens A119 (Corneal S.L., Paris, France) or the Storz Hydroview Model H55S, (Bausch and Lomb Surgical, Inc. Clearwater, FL). Biometry and preoperative IOL calculations were not affected by PIOL implantation, based on initial biometric data and current corneal keratometry using the SRK-T formula. The refractive goal in all eyes was approximately -1.00 diopter (D). All calculations were done using the same biometry software (Ocuscan contact biometer, S/N 9901053301X, Alcon Surgical, Ft. Worth, TX).

Statistical Analysis

Quantitative variables are expressed as the mean and corresponding standard deviation (SD) and qualitative variables as relative percentages with respect to the total number of eyes. For statistical analysis of results we used a paired Student *t*-test for comparison of means between groups. Statistical significance was at the level of $P \leq .05$.

RESULTS

Mean age of patients who developed cataract and subsequently had PIOL explantation and cataract surgery (7 Ophtec, 16 Adatomed, 2 Staar) was 54 years in the Ophtec group, 34 years in the Adatomed group, and 34 years in the Staar group.

Mean preoperative myopia in the Ophtec group was -16.56 ± 3.02 D (range -7.00 to -21.50 D), in the Adatomed group, -14.89 ± 2.56 D (range -9.00 to -19.50 D), and in the Staar group, -16.79 ± 4.59 D (range -11.50 to -19.50 D).

Clinical data for anterior chamber amplitude and axial length are shown in Tables 1 and 2. We did not have bilateral PIOL explantation and cataract surgery with any eye.

We found nuclear cataract and anterior subcapsular opacification in our study: 7 of 231 eyes (3.04%) in 7 patients (5 men and 2 women) developed nuclear cataract (Fig 1) after Ophtec PIOL implantation (5 cataracts with the biconcave optic iris-claw model and 2 cataracts with the concave-convex model). The average time after Ophtec PIOL implantation until nuclear cataract appearance was 56.92 ± 2.25 months (range 38 to 121 mo), and cataract surgery occurred an average 136.2 months after PIOL implantation.

Anterior subcapsular cataract developed with the Adatomed and Staar PIOLs: 38/89 eyes (42.69%) in the Adatomed group and 3/23 eyes (13.04%) in the Staar group. Two cases of anterior subcapsular

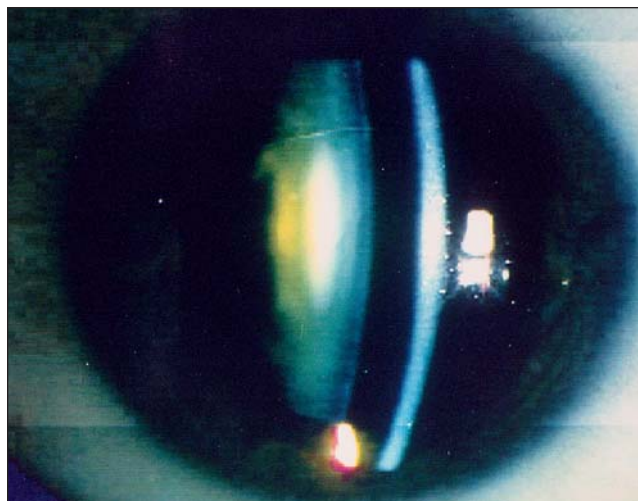


Figure 1. Nuclear cataract, 4 years after implantation of an Ophtec lens.

cataract with the Staar lens were with the V3 model and the other one was with the V2 model. However, anterior subcapsular opacification in the Adatomed group developed more rapidly compared to the Staar group. The average time to cataract appearance in the Adatomed group was 13.05 ± 4.96 months; in the Staar group it was 20.0 ± 1.00 months. No eye that developed cataract after PIOL implantation had significant intraoperative or postoperative complications. We did not find differences between the two groups (Adatomed and Staar) in relation to clinical appearance of the anterior subcapsular cataract. In general, cataracts associated with Adatomed PIOLs were denser, with more clinical significance than cataracts with Staar PIOLs. Anterior subcapsular cataract types were classified as peripheral concentric to the optical zone (Figs 2A, B), central gray-white opacities in the pupillary zone (Figs 3A, B), and diffuse-dense (Fig 4). The histopathological study of one specimen of anterior capsule obtained during cataract surgery showed a hyalinized laminate structure covered by a flat and smooth epithelium with thickened hyaline areas (Fig 5). All cataracts diminished visual acuity, depending on proximity to the optical axis.

Eyes that subsequently developed cataract were studied. Cataract surgery was indicated only when a reduction occurred in BSCVA of 4 or more lines compared with BSCVA achieved after PIOL implantation. According to this criteria, cataract extraction was performed in 7 eyes with Ophtec PIOLs, 16 with Adatomed PIOLs, and 2 with Staar PIOLs. Cataract surgery was successful in all eyes, and posterior chamber low power IOLs were implanted in

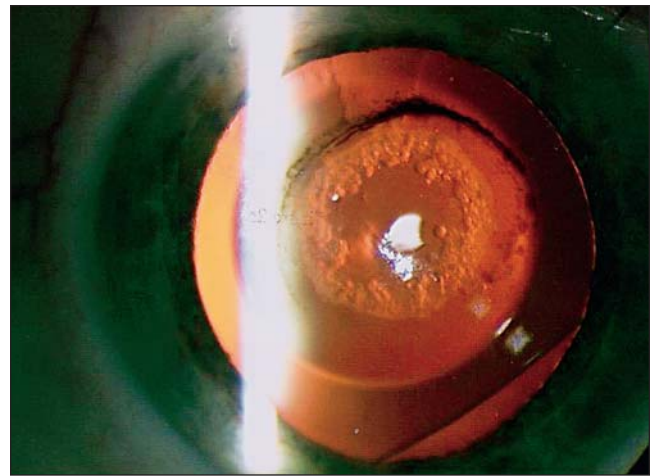
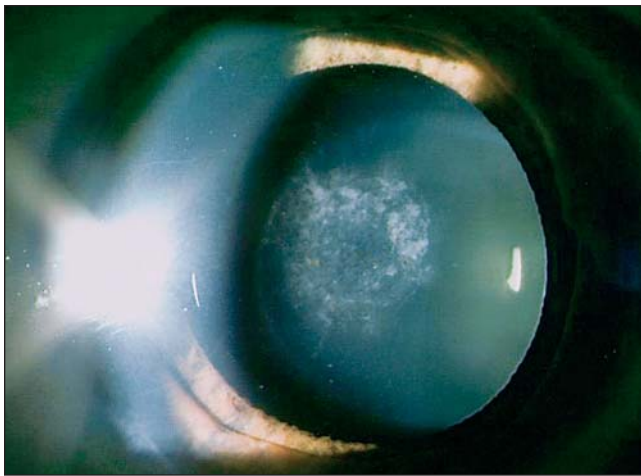


Figure 2. A) Anterior subcapsular cataract: peripheral and concentric to the optical zone of the Adatomed silicone lens 15 months after implantation. B) The same eye in retroillumination.


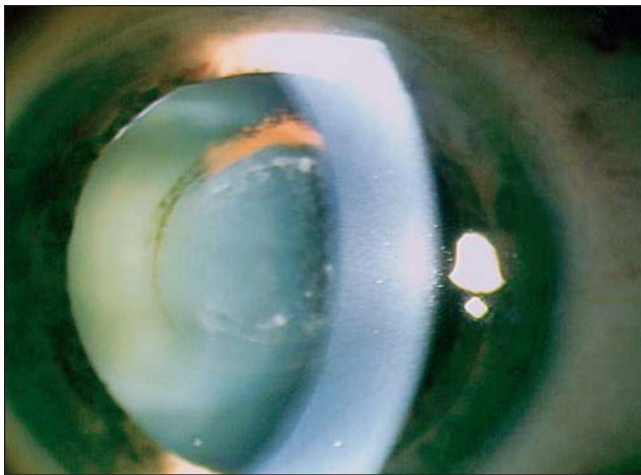


Figure 3. Anterior subcapsular cataract in a Staar lens (model V3). A) Central gray-white opacities in the pupillary zone in retroillumination. B) The same eye without retroillumination.

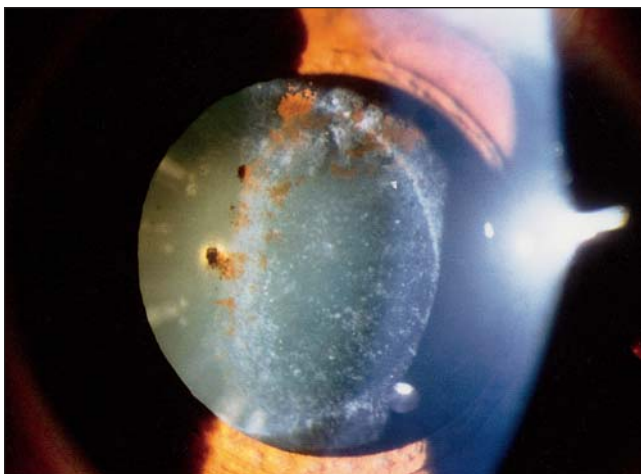


Figure 4. Adatomed lens: diffuse-dense cataract, 2 years after first diagnosis.

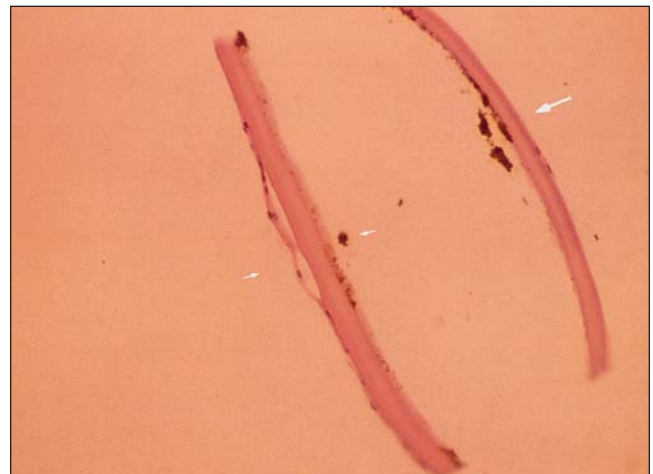


Figure 5. Histologic section of the anterior capsular zone of the cataractous crystalline lens shows a hyalinized laminate structure covered by a smooth epithelium with thickened hyaline areas. Note pigment deposits (arrows). Adatomed silicone PIOL; hematoxylin and eosin stain (magnification 50X).

the capsular bag in all eyes.

Mean time between PIOL implantation and cataract surgery was 136.2 months in the Ophtec group, 18.28 months in the Adatomed group, and 22.2 months in the Staar group (Table 2).

After cataract surgery, mean BSCVA was 0.60 (0.22 logMAR \pm 0.24) in the Ophtec group, 0.64 (0.18 logMAR \pm 0.14) in the Adatomed group, and 0.8 in the two eyes with the Staar PIOL. The difference between BSCVA after cataract surgery with low power posterior chamber IOL implantation compared with that after posterior chamber PIOL implantation was not statistically significant ($P=.45$ and $P=.56$, paired Student *t*-test for Ophtec and Adatomed groups, respectively). Only two eyes with a Staar lens PIOL had cataract with explantation; BSCVA of 0.8 was the same after phacoemulsification with posterior chamber IOL compared with that initially after Staar lens PIOL implantation.

DISCUSSION

The relationship between PIOL implantation and cataract development has not been clearly shown. Cataract formation is a potential complication in any intraocular procedure. However, with a PIOL for high myopia, it is unknown whether cataract formation is related to the PIOL itself, to the intraocular procedure, or to high myopia. Cataract development is four times more frequent in those with high myopia than in the general population.¹² Hoffer¹⁶ in 1980 and more recently Colin¹⁷ contended that eyes with high myopia develop cataracts earlier than normal eyes. One of the possible complications posed by the implantation of a PIOL is the possibility of inducing a cataract—especially with posterior chamber PIOLs—as a result of either direct trauma or a later metabolic effect.¹⁸

Early cataracts are not only related to high myopia; other risk factors are a family history of early cataracts, ocular trauma, medications, or other diseases—all of which were negative in our series.

We found two kinds of cataracts in our series, anterior subcapsular opacification and nuclear cataract. Our study suggests a relationship between cataract type and PIOL placement (anterior chamber versus posterior chamber). All eyes with Ophtec PIOLs that developed cataract were a nuclear type, and all eyes with Adatomed and Staar PIOLs developed an anterior subcapsular cataract. We have reported the development of lens opacification in the anterior subcapsular area caused by a posterior capsule refractive IOL.¹⁸ Other studies report cataract

development and cataract extraction during follow-up in one eye that had an Ophtec PIOL.^{7,19}

In our large series, anterior subcapsular opacification appears to have been associated with posterior chamber PIOLs (Adatomed and Staar). The association between posterior chamber PIOLs and anterior subcapsular opacification and pigment deposits in most cases of observed cataracts leads us to believe that a metabolic alteration may be released by the following mechanisms: 1) Repeated micro-trauma to the iris-lens-anterior capsule complex during the accommodation process²⁰; 2) Cupping effect—when the space between the posterior face of the PIOL and the anterior capsule of the natural lens is minimal or nonexistent.²⁰ In this situation, the posterior face of the PIOL (concave vaulting) against the anterior capsule of the natural lens obstructs aqueous humor circulation²¹; 3) Surgical trauma, even with experienced surgeons²² with an associated inflammatory process; and 4) Higher level of pigmentary dispersion in young myopic patients²³ associated with possible dispersion due to contact between the PIOL and iris posterior face.

This cataract type was less frequent with the Staar lenses (3/23 eyes, 13.04%) than with the Adatomed lenses (38/89 eyes, 46%). Cataract development occurred with the Staar lens model V3 in two eyes and with model V2 one eye. Model V3 was a non-vaulted flat design and was associated with a higher cataract incidence by other authors: Sanders (12.6% versus 2.9% with Staar V3/V4 designs)²⁴, Uusitalo (2.6% of eyes with the Staar lenses)²⁵, Gonvers (27% had ICL-induced anterior subcapsular cataracts)²⁶, Menezo and colleagues (16.6% versus 8.33% with V3/V2 designs)¹⁸, and Fink (two cases of lens opacities in four eyes).²⁷ The V3 model is no longer in use, but more vaulted models are currently being implanted, such as the V4.²⁸ The older models of Staar lenses have substantial differences in design compared with newer ones, particularly with vault. The new models vault the lens, with no contact with the posterior iris face PIOL and natural lens, which avoids the possibility of late complications such as complicated cataracts. Gonvers^{26,28} realized that the number of cataracts increased with the duration of the follow-up and cataracts developed more commonly in older patients than in younger patients.

Adatomed lenses have not been used clinically since 1998 because of high cataract incidence. Brauweiler²⁹ and Menezo¹⁸ reported a high incidence of cataract with this lens type.

Regarding patients with Ophtec lenses, mean age

of the seven patients with nuclear cataract was 42.5 years at the time of PIOL implantation and 53.85 years (range 52 to 62 yr) at the time of cataract surgery. Average axial length was 32.31 mm in these seven patients. These two parameters (age and axial length) were statistically significant ($P \leq .01$). Our results—delayed cataract formation (56.92 ± 2.5 months after PIOL implantation) and delayed cataract extraction (136.2 months) with nuclear cataract in all eyes—support the conclusion that age (older than 40 years) and high axial length (>30 to 31 mm) may be considered prognostic factors.⁷ From our experience, we cannot establish an association between cataract formation and iris-claw PIOL implantation, because of the delayed time of appearance and time to cataract surgery.

Cataract surgery may be difficult in the presence of a PIOL. In all eyes in this study and with the three PIOL types, phacoemulsification after PIOL explantation was uneventful. However, posterior chamber PIOLs, especially the Adatomed type (no longer available) could not be explanted as easily as the Ophtec and Staar PIOLs. Eyes with the Adatomed PIOL demonstrated adhesion between the PIOL and the anterior capsule, which made separation of the adhesion and removal of the PIOL difficult, sometimes requiring a 360° excision of the anterior capsule with adherence to the PIOL.

Postoperative BSCVA achieved after cataract removal and posterior chamber lens implantation was similar to that obtained with PIOL lenses for high myopia.⁷ Best spectacle-corrected visual acuity was not significantly different from that before cataract development. However, one eye showed visual deterioration after Ophtec PIOL explantation and posterior cataract removal. This patient was 57 years old, and preoperative BSCVA in this eye was 20/40 with a refraction of -19.50 D. The Ophtec PIOL implantation and postoperative follow-up were uneventful. After phacoemulsification and low power lens implantation in the capsular bag, BSCVA was 20/40, but 5 months later it decreased to count fingers. Fluorescein angiographic examinations revealed dry macular degeneration. Visual deterioration was explained by progression of the macular degeneration, probably unrelated to the Ophtec PIOL or surgical procedure.

Cataracts occurred with undesirable frequency during the development of different styles of PIOLs, with different levels of surgical experience. The PIOL styles reported in this paper are no longer available. Current data suggest that using contemporary styles, along with surgical experience, has

decreased the rate cataract formation. In our experienced hands, this has been true with the Ophtec PIOL. More than 12 years of experience with this PIOL have yielded outcomes that are safe and stable. Long-term follow-up is required to assess whether Staar lenses, especially the new vaulted models, are safe (in terms of cataract formation) for correcting high myopia.

REFERENCES

1. Marinho A, Pinto MC, Vaz F. Phakic intraocular lenses: which to choose. *Curr Opin Ophthalmol* 2000;11:280-288.
2. Menezo JL, Aviñó JA, Cisneros A, Rodriguez-Salvador V, Martínez-Costa R. Iris-claw phakic intraocular lens for high myopia. *J Refract Surg* 1997;13:545-555.
3. Fechner PU, Strobel J, Wichmann W. Correction of myopia by implantation of a concave Worst iris claw lens into phakic eyes. *Refract Corneal Surg* 1991;7:286-298.
4. Fechner PU, Wichmann W. Correction of myopia by implantation of minus optic (Worst iris claw) lenses into the anterior chamber of phakic eyes. *Eur J Implant Refract Surg* 1993;5:55-59.
5. Pearce JL. Sixteen months' experience with 140 posterior chamber intraocular lens implants. *Br J Ophthalmol* 1997;61:310-315.
6. Fechner PU, Haigis W, Wichman W. Posterior chamber myopia lenses in phakic eyes. *J Cataract Refract Surg* 1996;22:178-182.
7. Menezo JL, Cisneros A, Rodriguez-Salvador V. Removal of age-related cataract and iris-claw phakic intraocular lens. *J Refract Surg* 1997;13:589-590.
8. Wiechens B, Winter M, Haigis W, Happe W, Behrendt S, Rochels R. Bilateral cataract after phakic posterior chamber top hat-style silicone intraocular lens. *J Refract Surg* 1997;13:392-397.
9. Trindade F, Pereira F. Cataract formation after posterior chamber phakic intraocular lens implantation. *J Cataract Refract Surg* 1998;24:1661-1663.
10. Brauweiler PH. High incidence of cataract formation after implantation of a silicone posterior chamber lens in phakic highly myopic eyes. *Ophthalmology* 1999;106:1651-1655.
11. Apollonio A, Weigelin E. Complicazioni della miopia elevata. *Boll Oculist* 1964;43:25.
12. Metge P, Pichot de Champfleury A. La cataracte du myope fort. In Mondon H, Metge P, eds. *La Myopie Forte*. Paris, France: Masson; 1994;447-465.
13. Menezo JL, Cisneros A, Cervera M, Harto M. Iris claw phakic lens: intermediate and long term corneal endothelial changes. *Eur J Implant Refr Surg* 1994;6:195-199.
14. Menezo JL, Cisneros A, Hueso JR, Harto MA. Long-term results of surgical treatment of high myopia with Worst-Fechner intraocular lens. *J Cataract Refract Surg* 1995;21:93-98.
15. Pérez-Torregrosa VT, Menezo JL, Harto MA, Maldonado MA, Cisneros A. Digital system measurement of decentration of Worst-Fechner iris-claw myopia intraocular lens. *J Refract Surg* 1995;11:26-30.
16. Hoffer KJ. Biometry of 7500 cataractous eyes. *Am J Ophthalmol* 1980;90:360-368.
17. Colin J. Bilensectomy: the implications of removing phakic intraocular lenses at the time of cataract extraction (guest editorial). *J Cataract Refract Surg* 2000;26:2-3.
18. Menezo JL, Peris-Martínez C, Cisneros A, Martínez-Costa R. Posterior chamber phakic intraocular lenses to correct high myopia: A comparative study between Staar and Adatomed models. *J Refract Surg* 2001;17:32-41.
19. Menezo JL, Cisneros A, Harto MA. Extracapsular cataract

- extraction and implantation of a low power lens for high myopia. *J Cataract Refract Surg* 1988;14:409-412.
20. Cisneros AL. Estudio prospectivo de lentes fáquicas epicapulares para la corrección de la alta miopía (thesis doctoral). Valencia, Spain: Universidad de Valencia; 1997.
 21. Zaldivar R, Davidorf JM, Oscherow S, Ricur G, Piezzi V. Combined posterior chamber phakic intraocular lens and laser in situ keratomileusis: bioptics for extreme myopia. *J Refract Surg* 1999;15:299-308.
 22. Apple DJ, Brems RN, Park RB, Norman DK, Hansen SO, Tetz MR, Richards SC, Letchinger SD. Anterior chamber lenses. Part I: complications and pathology and a review of designs. *J Cataract Refract Surg* 1987; 13:157-174.
 23. Sugar HS, Barbour FA. Pigmentary dispersion and glaucoma: a rare clinical entity. *Am J Ophthalmol* 1949;32:90-92.
 24. Sanders DR, Vukich JA, ICL in Treatment of Myopia (ITM) Study Group. Incidence of lens opacities and clinically significant cataracts with the implantable contact lens: comparison of two lens designs. *J Refract Surg* 2002;18:673-682.
 25. Uusitalo RJ, Aine E, Sen NH, Laatikainen L. Implantable contact lens for high myopia. *J Cataract Refract Surg* 2002; 28:29-36.
 26. Gonvers M, Bornet C, Othenin-Girard P. Implantable contact lens for moderate to high myopia: relationship of vaulting to cataract formation. *J Cataract Refract Surg* 2003; 29:918-924.
 27. Fink AM, Gore C, Rosen E. Cataract development after implantation of the Staar Collamer posterior chamber phakic lens. *J Cataract Refract Surg* 1999;25:278-282.
 28. Gonvers M, Othenin-Girard P, Bornet C, Sickenberg M. Implantable contact lens for moderate to high myopia: short term follow-up of two models. *J Cataract Refract Surg* 2001; 27:380-388.
 29. Brauweiler PH, Wehler T, Busin M. High incidence of cataract formation after implantation of a silicone posterior chamber lens in phakic, highly myopic eyes. *Ophthalmology* 1999;106:1651-1655.